

Letter to the Editor

Cytogenetic studies for cMYC, BCL2 and BCL6 genes in neoplasm: comparison of karyotype, FISH in paraffin-embedded tissue and FISH in methanol-acetic acid-fixed cells suspensions



Dear Editor,

Diffuse large B-cell lymphomas (DLBCL) comprise a group of heterogeneous neoplasms being the most frequent subtype of non-Hodgkin Lymphoma (NHL). Seven to 10% of DLBCL, most of them derived from germinal center cells, harbored cMYC, BCL2 and/or BCL6 translocations, known as “Double-hit” lymphoma (DHL) and/or “Triple-hit” lymphoma (THL). They are

categorized as a high-grade B-cell lymphoma (HGBL) according to World Health Organization (WHO) classification, have an inferior prognosis and a special therapeutic approach.^{1,2,3} The standard technique for diagnosis of double or triple hit NHL is the fluorescence *in situ* hybridization (FISH) performed in paraffin-embedded tissue, using probes to detect cMYC (located in chromosome 8q), BCL2 (located in chromosome 18q) and BCL6 (located in chromosome 3q) rearrangements.

Table 1 – Results of interphasic FISH for cMYC, BCL2 and BCL6 in paraffin-embedded tissue and in suspension cells and the karyotype in 4 lymph nodes samples. The numbers in parentheses represent the percentage of interphases with the cytogenetic abnormality.

	FISHparaffin	FISH suspension	Karyotype	
Case 01 Diffuse large B-cell lymphoma	cMYC	Negative	Negative	49,X,add(X)(q24),der(1)dup(1)(q21q4)
	BCL2	Negative	Negative	del(1)(q42),+4,+5,del(9)(p13),
	BCL6	Negative	Negative	add(14)(q32),+21,add(21)(p11.2)x2[3]/46,XX[4]
	IGH	Rearrangement (54%)	Rearrangement (56%)	
Case 02 Diffuse large B-cell lymphoma	cMYC	Negative	Negative	45,XX,-7,-8,-12,add(12)(q24.1),
	BCL2	Negative	Negative	+del(13)(q12q22),add(13)(q34),
	BCL6	Negative, 3 signals (46%)	Negative, 3 signals (93%)	-14,t(14;?)(q32;?),add(15)(p11.1),
	IGH/CCND1	Negative	Negative ^a	add(16)(p13.3)+2mar[21] /46,XX[3]
Case 03 Mantle cell lymphoma	cMYC	Negative	Negative	47,XX,add(1)(q21),+3,der(8)t(8;11;?)
	BCL2	Negative	Negative	(p21;q13;?)-9,-11,t(11;14)(q13;q32),
	BCL6	Negative, 3 signals (19%)	Negative, 3 signals (46%)	+12,del(13)(q12q21),+mar[8]/
	IGH/CCND1	Present (15%)	Present (89%)	46,XX[12]
Case 04 Metastatic carcinoma	cMYC	–	–	76~85,XXYY,-1,inv(2)(q12q24)x2,
	BCL2	–	–	del(3)(p24)x2,-4,-4,-9,-9,del(11)
	BCL6	Negative, 4 signals (10%)	Negative, 4 signals (78%)	(q22q25)x2,del(13)(q12q32)x2,-14, -14,-16,-20,-20,+22,+add(22)(p11.2) x2[12]/46,XY[8]

^a Suggestive IGH rearrangement.

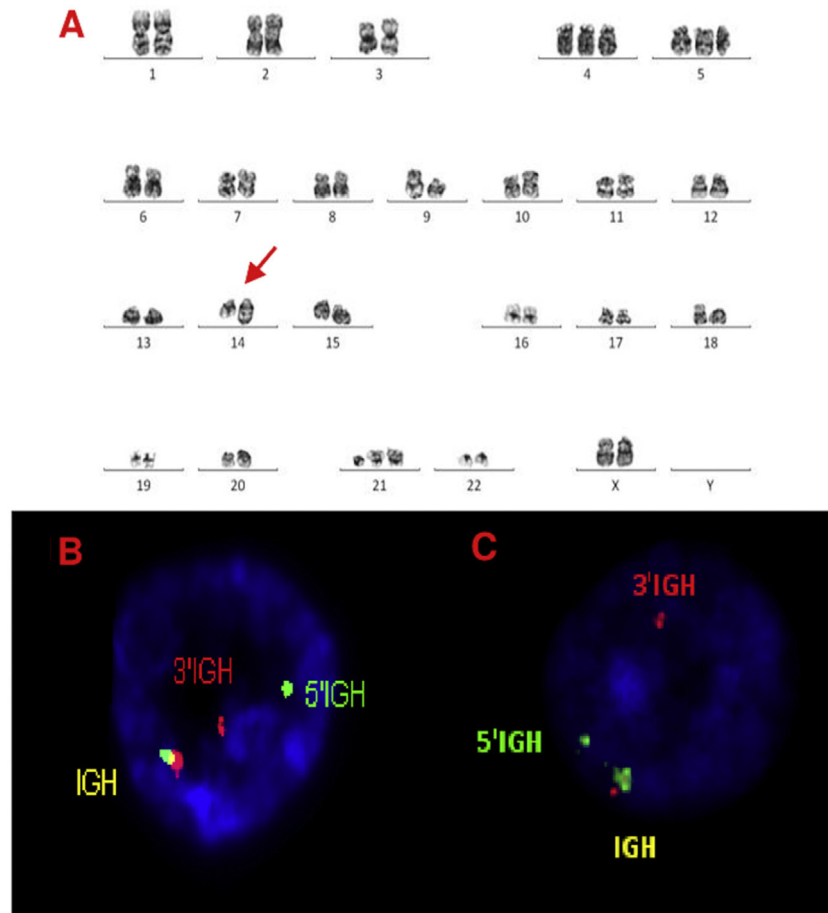


Figure 1 – A, B and C–Cytogenetic studies from case 1: (1A) Lymph node karyotype analysis with G-banding demonstrating complex karyotype, the arrow shows additional material in 14q, (1B) interphase break-apart FISH showing IGH rearrangement, with separation of the 5'-probe (green) from the 3'-probe (red) in paraffin-embedded tissue and (1C) in suspension cells.

Although karyotype is important to determine significant abnormalities for characterization of NHL genetic subtypes, it is not used in clinical routine, because of the difficulty to send fresh material to the laboratory. This fresh material and methanol-acetic acid-fixed cell suspensions (arising from the karyotype preparation) could also be used for performing FISH.

This study aimed to compare the results of karyotype and the *cMYC*, *BCL2* and *BCL6* rearrangements detected by FISH performed in paraffin-embedded tissues and methanol-acetic acid fixed cells suspensions in lymph nodes samples with suspicious of NHL diagnosis.

For karyotyping, cells from lymph nodes samples were obtained after mechanical disaggregation, cultured for 24-hrs without mitogen and 72-hrs cultures with phorbol-12-myristate 13-acetate (TPA), harvested and submitted to G-banding according to standard protocols.⁴ We use the same probes *cMYC*, *BCL2*, *BCL6* (*Break-apart*, DC, Cytocell®, Cambridge, UK) for FISH studies on paraffin-embedded tissues fixed in 10% buffered formalin and on methanol-acetic acid (3:1) fixed cells. In some cases, other probes were used to confirm the karyotype findings, for example, FISH for detection the t(11;14) *CCND1-IGH* rearrangement.

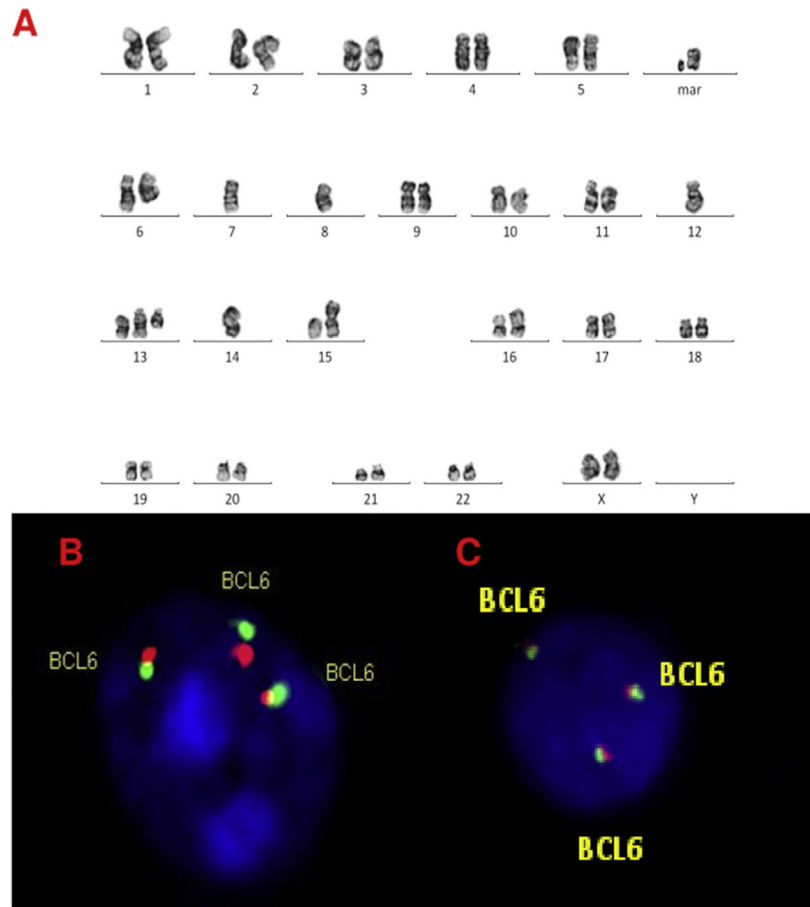


Figure 2 – A, B and C–Cytogenetic studies from case 2: (2A) Lymph node karyotype analysis with G-banding demonstrating complex karyotype, (2B) interphase break-apart FISH showing extra copy of BCL6 (3 fusion signals) detected in paraffin-embedded tissue and (2C) in suspension cells.

Images were captured with a Zeiss Axio Scope.A1 microscope and were evaluated with IKAROS and ISIS imaging system (MetaSystems, Altlußheim, Germany). FISH studies were performed according to the manufacturer's recommendations, in 2 µm thick section paraffin block or suspension cells. A hundred cells were manually scored in each case by two biologists and reviewed by expert hematopathologists. Cut-off values were established in our laboratory following international guidelines.⁵ cMYC, BCL2, BCL6 rearrangements cut-offs in paraffin-embedded tissue were 3.8%, 2.3% and 3.8% respectively, and in suspension cells were 11.9%, 4.6% and 6.0%. The cytogenetic results agreed with the International System for Human Cytogenetic Nomenclature 2016.⁶

Fresh and paraffin-embedded tissues from 4 lymph nodes were used in this study (2 diffuse large B-cell lymphomas, 1 mantle cell lymphoma, and 1 metastatic carcinoma).

Karyotype and FISH results are shown in Table 1 and Figure 1. All karyotypes were complex, showing IGH rearrangement in 2 cases (cases 1 and 2), one of them with t(11;14) CCND1/IGH. FISH for detection of t(11;14) (CCND1/IGH DC, DF, Cytocell[®], Cambridge, UK) or IGH rearrangement (IGH, Breakapart, DC, Cytocell[®], Cambridge, UK) was studied in paraffin and fixed material and confirmed the results. cMYC, BCL2 and BCL6 rearrangements were not detected in paraffin-embedded tissue nor suspension cells. Extra copies of BCL6 were detected in fixed and paraffin samples in 3 cases (cases 2, 3 and 4) (Figures. 2–4).

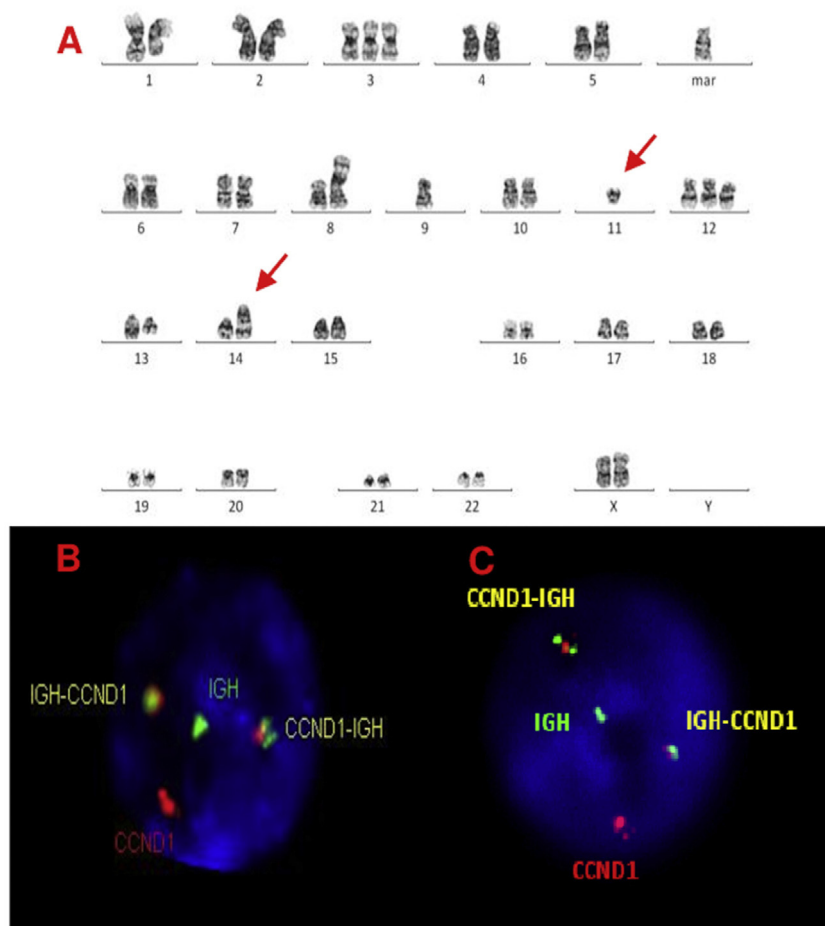


Figure 3 – A, B and C–Cytogenetic studies from case 3: (3A) Lymph node karyotype analysis with G-banding demonstrating complex karyotype, the arrows shows $t(11;14)$, (3B) interphase dual color, dual fusion FISH showing $CCND1-IGH$ rearrangement, with 2 fusion signals detected in paraffin-embedded tissue and (3C) in suspension cells.

Although we were unable to obtain double and/or triple-hit NHL in these small number of samples to compare these rearrangements in suspension cells and paraffin-embedded tissue we observed agreement for *IGH* rearrangement and extra *BCL6* copies. We still observed a higher percentage of cells with gene rearrangements in three out of four cases in methanol-acetic acid-fixed material when compared to paraffin blocks. We had difficulty in obtaining fresh samples from

biopsies in the medical routine, but we know the importance of making this material available for immunophenotypic and genetic studies, which can generate important data in a short turnaround time. We reinforce the importance of collecting fresh material during biopsies procedures in patients with NHL suspicions and challenge to perform a greater number of karyotyping and FISH studies in cell suspensions, to confirm our findings.

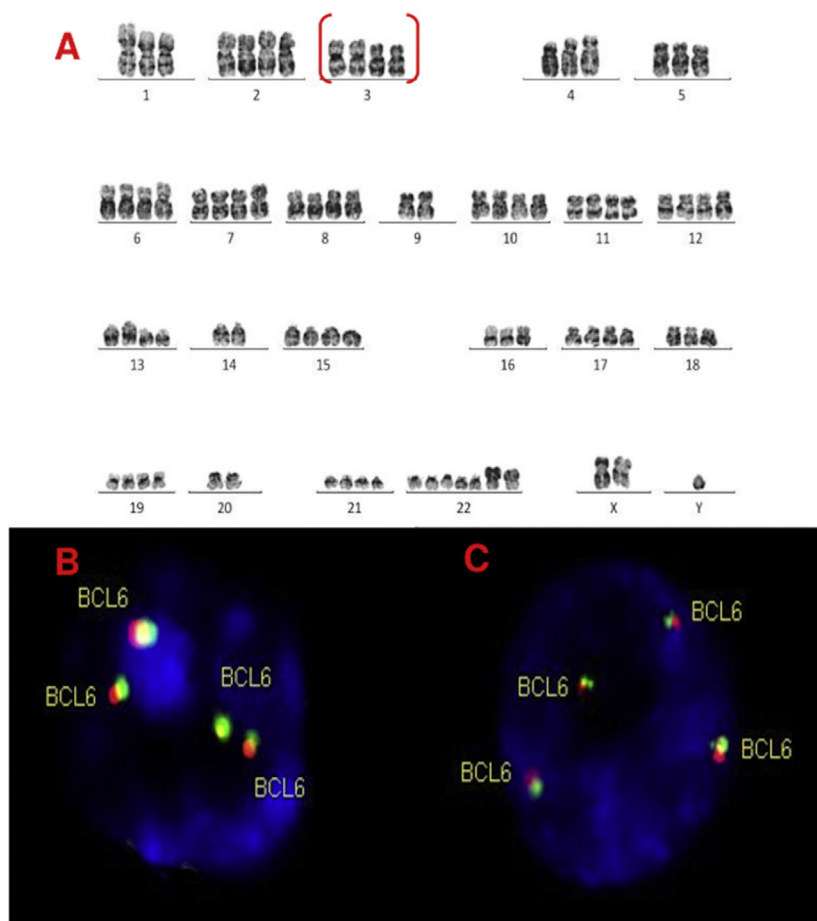


Figure 4 – A, B and C–Cytogenetic studies from case 4: (4A) Lymph node karyotype analysis with G-banding demonstrating complex and hypotetraploidy karyotype, (4B) interphase break-apart FISH showing two extra copies of *BCL6* (4 fusion signals) detected in paraffin-embedded tissue and (4C) in suspension cells.

Conflict of interest

The authors declare no conflicts of interest.

Acknowledgments

The authors acknowledge the technical staff of the cytogenetic and the pathology laboratories for their assistance, in special to Cristine Dobo and Daniela Borri.

REFERENCES

1. Swerdlow SH, Campo E, Pileri SA, Harris NL, Stein H, Siebert R, et al. The 2016 revision of the World Health Organization classification of lymphoid neoplasms. *Blood*. 2016;127:2375–90.
2. Savage KJ, Johnson NA, Ben-Neriah S, Connors JM, Sehn LH, Farinha P, et al. *MYC* gene rearrangements are associated with a poor prognosis in diffuse large B-cell lymphoma patients treated with RCHOP chemotherapy. *Blood*. 2009;114:3533–7.
3. Dunleavy K, Fanale MA, Abramson JS, Noy A, Caimi PF, Pittaluga S, et al. Dose-adjusted EPOCH-R (etoposide, prednisone, vincristine, cyclophosphamide, doxorubicin, and rituximab) in untreated aggressive diffuse large B-cell lymphoma with *MYC* rearrangement: a prospective, multicentre, single-arm phase 2 study. *Lancet Haematol*. 2018;5:e609–17.
4. Katzenberger T, Kalla J, Leich E, Stöcklein H, Hartmann E, Barnickel S, et al. A distinctive subtype of t(14;18)-negative nodal follicular non-Hodgkin lymphoma characterized by a predominantly diffuse growth pattern and deletions in the chromosomal region 1p36. *Blood*. 2009;113(2009):1053–61.
5. Wolff DJ, Bagg A, Cooley LD, Dewald GW, Hirsch BA, Jacky PB, et al. Association for Molecular Pathology Clinical Practice Committee. American College of Medical Genetics Laboratory Quality Assurance Committee Guidance for fluorescence in situ hybridization testing in hematologic disorders. *J Mol Diagn*. 2007;9:134–43.
6. McGowan-Jordan J, Simons A, Schmid M, editors. *ISCN 2016: An International System for Human Cytogenomic Nomenclature*. Basel, Basel: S. Karger; 2016.

Caroline Henriques Garcia *, Roberta Maria da Silva Oliveira Safranauskas , Alanna Mara P.S. Bezerra 

Hospital Israelita Albert Einstein, São Paulo, SP, Brazil

Elvira D.R.P. Velloso  a,b

^a Hospital Israelita Albert Einstein, São Paulo, SP, Brazil

^b Hospital das Clínicas, Faculdade de Medicina, Universidade de São Paulo, São Paulo, SP, Brazil

* Corresponding author at: Hospital Israelita Albert Einstein, Av. Albert Einstein 627/701, Morumbi, CEP:05652-900, São Paulo, SP, Brazil.

E-mails: carolhenriques13@hotmail.com,
roberta.safranauskas@einstein.br (C.H. Garcia).

Accepted 24 June 2020

Received 3 March 2020

Available online 7 August 2020

2531-1379/

© 2020 Associação Brasileira de Hematologia, Hemoterapia e Terapia Celular. Published by Elsevier Editora Ltda. This is an open access article under the CC BY-NC-ND license (<http://creativecommons.org/licenses/by-nc-nd/4.0/>).

<https://doi.org/10.1016/j.htct.2020.06.012>