



Testicular involvement in pediatric acute lymphocytic leukemia: what to do about it?

Lisieux Eyer de Jesus^{1,2}, Samuel Dekermacher², Glaucia Campos Resende², Renata Rangel Justiniano²

¹ Serviço de Cirurgia pediátrica, Hospital Universitário Antônio Pedro - Niterói, RJ, Niterói, Brasil; ² Serviço de Cirurgia pediátrica, Hospital federal dos Servidores do Estado - Rio de Janeiro, RJ, Brasil

INTRODUCTION

Acute lymphocytic leukemia (ALL) represents 30% of childhood cancers (1) and relapsed ALL is the leading cause of death caused by cancer in childhood (2).

Relapse of ALL typically arises from the bone marrow. Extramedullary relapse most commonly involves the central nervous system but may also present as a testicular isolated or concomitant relapse in males (3).

Information about testicular leukemia is difficult to analyze, considering difficulties to compare patients treated with protocols that are not in use contemporaneously to children treated nowadays, the different results of leukemia treatment in developed and low/medium income countries (LMIC) results referring to multiple age groups, the relative rarity of the disease and the limited quality of the literature.

MATERIALS AND METHODS

We made an analytic descriptive non-systematic literature review about testicular recurrence after ALL in childhood. The key words "leukemia AND (testis OR testicle)" were used to find papers through PUBMED, limited to children (0-18 years old), in Portuguese, Spanish, English, or French. The abstracts were then reviewed. Pa-

pers dealing primarily with TR after ALL were reviewed. The selected papers were then read in toto. Any other papers of interest retrievable from the references were also reviewed. Gray literature was not included.

RESULTS

Testicular involvement in pediatric ALL is rare in patients from developed countries being treated with modern protocols, where more than 90% survive (4), with a proportion of 15-20% relapses after first remission, mostly bone marrow disease (5-6). Lower prevalence of testicular ALL is strongly dependent on modern chemotherapy protocols: testicular recurrences (TR) affected 5.8 to 16.2% of the patients in the '70s, versus 0-2% in contemporaneous cohorts from developed countries (0-2%), equally divided between early, intermediate and late occurrences (2, 3, 6, 7). Data from 308 ALL autopsies on leukemia patients from 1958-1982 (88 children) showed involvement of the testes in 15% of the most recent cases (1977-1982) versus 49% of those treated between 1958-1964 (8). Later and intermediate TR usually occurs 2-3 years after remission but has been reported up to 10 years after treatment of myeloid leukemias (9).

TR incidence in LMIC persists similar to that described in the '70s, mainly due to late diagnosis and irregular or inadequate chemotherapy,

despite the adoption of intermediate/high-dose methotrexate (MTX) protocols. In India, almost a quarter of ALL children recur (half of those early), and a quarter of the relapses present TR (equally divided between isolated and concurrent) (10).

Timing of TR (early/ < 18 months, intermediary/ $18-35$ months or late/ ≥ 36 months after remission), kind of relapse (isolated versus concurrent TR), and the number of relapses presented by the patient are directly related to the prognosis. Early, concurrent, and successive relapses are related to a worse prognosis. TR is partially responsible for the worse prognosis of ALL in males as compared to females (11).

Studies from autopsies of ALL patients, obviously biased towards severe and/or irresponsive cases, report frequent testicular involvement (25-48.5% of the patients) associated with other disease foci (12, 13), suggesting that the testis may be frequently involved in disseminated uncontrolled disease and that testicular leukemia that is associated to severe disseminated early or recurrent leukemia may be different from TR, especially if isolated.

Three different clinical patterns of TR may be seen:

1. Isolated TR;
2. Concurrent relapse associating TR to disease attaining other loci;
3. Advanced/out of control severe leukemia.

The efficacy of chemotherapy on the testicles is limited due to insufficient penetration of some drugs in the blood-testicular barrier ("pharmacological sanctuary"). Although the physiological basis for a blood-testis barrier is unclear, it has been demonstrated that some systemic medications do not distribute equally to the testes. The concentrations of methotrexate (MTX) are 2-4 times lower in the testicular interstitial space (the typical site of tumoral invasion) and 18-50 times lower in the tubules (typically associated with late tumoral invasion) than in the patient's blood MTX (6, 14). This can be resolved with higher doses of MTX (14), prolonged chemotherapy, and usage of vincristine and/or cyclophosphamide (drugs that surpass the blood-testicular barrier) associated with steroids. Departing from this information, the

usage of intermediate/high intravenous doses of MTX from the 1980s significantly lowered the incidence of TR. Some authors also suggest that the lower temperatures typical for normally located testis may also be related to the lower pharmacological activity of some drugs (15).

Prepubertal and peripubertal testicles may respond differently to neoplastic invasion, as compared to mature gonads (16). Cases presenting next to puberty may be more prone to TR than pre- or post-pubertal patients (6, 11). Immunological tolerance to neoplastic cells may also differ in the testicles as compared to other organs, locally "protecting" and "harboring" leukemia cells (4, 11). Two possibilities involving relapses have been suggested: (1) development from original clones that survived chemotherapy and are probably chemoresistant; (2) isolated or non-isolated TR developing from cells from a common ancestral clone previously protected from chemotherapy as a testicular nidus (2). This has obvious implications for treatment, with potentially worse results with rescue chemotherapy for chemotherapy-resistant disease, and calls for more studies (4, 16).

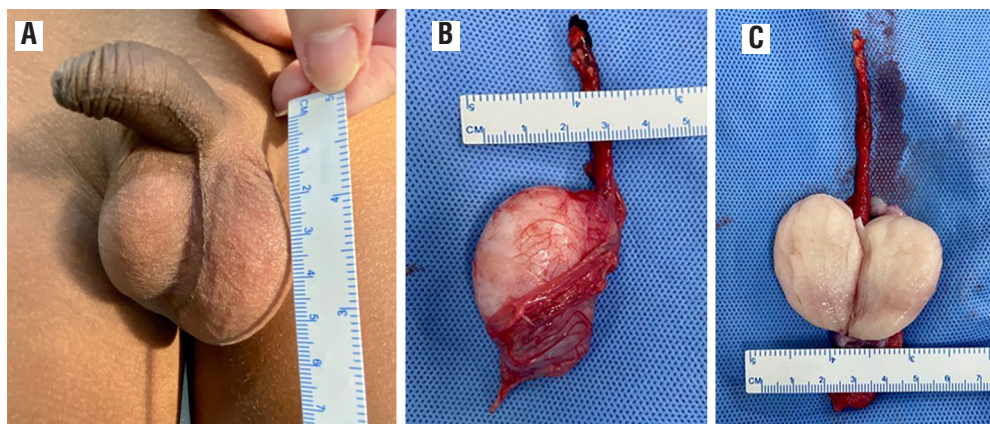
The involvement of the testicle in ALL cases is more frequent in high-risk patients (< 1 -year-old, ≥ 10 years old, patients presenting higher peripheral blasts counts at the moment of the diagnosis, T-cell leukemia cases showing significant hepatomegaly/splenomegaly or > 2 cm lymph nodes, unfavorable genetic patterns (BCR-ABL1 and KMT2A), and multiple recurrences) (1, 4, 10). Those need aggressive treatment, frequently including bone marrow transplantation (4).

Testicular ALL may (1) be simultaneous to the diagnosis of the primary disease (1.1 to 2.4% of the patients), and (2) present after treatment and remission of the primary disease (TR).

Clinically, the involved testis is usually augmented (Figure-1), irregular, firmer than a normal testicle, and usually painless. Bilateral enlargement is typically asymmetric. Discoloration may be rarely seen. The growth rate is quite rapid: some authors report that many of the involved testicles doubled in volume in 15 days (3).

In ultrasound, the testis is diffusely hypoechogenic or presents hypoechogenic nodules that are hypervascular on Doppler (17). The role of 18F

Figure 1 - Early left testicular recurrence in a 4-year-old boy.



A) testicular enlargement at physical examination; B) surgical specimen; C) surgical specimen, longitudinal section showing almost complete substitution of testis parenchyma for tumor cells.

FDG PET/CT to detect extramedullary leukemia is still being studied. Most data are available from relapsed patients, with sensitivity, specificity, and accuracy of, respectively, 93.3%, 71.4%, and 79.7%. The exam was able to detect all 4 cases of TR in Zhou's paper, 3/4 as diffuse uptaking/involvement. No false positives (usually related to inflammatory or infectious complications) were reported (9).

Fine needle and core needle biopsies are both accurate for diagnosis. Needle biopsy specimens provide results that are similar to open wedge biopsies (18-21). Microscopically the involved testicle shows focal or diffuse infiltration of leukemic blasts with effacement of the normal architecture (22), frequently arranged in a concentric fashion around tubules or vessels in the interstitial tissue (7). Tubular involvement is a late event (4). The specimen should be handled with care to avoid crushing artifacts and should be promptly fixed. There is some controversy about what concerns the fixative (formaldehyde, Bouin's, or Zenker's) (23).

"Isolated" TR should be considered a systemic disease: exclusive local treatment is associated with early systemic recurrence, including 10-20% with central nervous system invasion. Concerning treatment:

1. Clinically apparent testicular involvement simultaneous to primary diagnosis/treatment is rare (less than 2% of the patients) and is treated

as "common" cases. This clinical presentation is related to severe disease at presentation (hepatosplenomegaly, lymphonodomegaly, high number of peripheral blasts), but the results of treatment are similar to those in other cases in modern cohorts: testicular involvement in the initial clinical presentation is not an individual predictive factor (24, 25). Testicular irradiation is used only if the testicular abnormalities persist after chemotherapy. This is controversial and some authors advocate for local radiotherapy depending on the moment of the diagnosis, the bulk of testicular disease, and initial response to chemotherapy or for post-chemotherapy "control" biopsies by protocol (1). Subclinical testicular involvement normally responds to routine modern chemotherapy protocols. So, there is no need to actively search for testicular foci in ALL patients presenting clinically normal testicles and a normal ultrasound examination (4, 26).

- a. Systematic testicular biopsy just before discontinuing maintenance therapy in patients in remission was routine till the 1980s. Positive biopsies led to bilateral testicular irradiation and extension of chemotherapy in positive cases) (23). This was abandoned, considering the better results

of modern chemotherapy protocols, the relative rarity of TR, the possibility of false negatives, late diagnoses of TR despite negative biopsies, and results similar to those found in patients diagnosed departing from clinical symptoms/signs of TR (4, 27-30).

- b. Prophylactic testicular irradiation has been abandoned, in order to minimize gonadal dysfunction and infertility (14, 31), as no improvement in survival has been demonstrated in patients that received adequate systemic chemotherapy (32).

2. Post-remission TR:

- a. Local treatment: bilateral gonadal irradiation (24 Gy/2500 rads distributed in 2 weeks, 12 sessions, applied to the testis and spermatic cords (31, 33) or orchiectomy (generally reserved for unilateral cases and patients who refuse radiotherapy) + contralateral prophylactic irradiation (15 Gy), trying to preserve Leydig function and the potential for spontaneous puberty. However, lower testosterone levels in response to HCG stimulation, as compared to normal children/adolescents, have been proved after testicular irradiation (34), as well as delayed or arrested spontaneous puberty, and high serum FSH (31). Contralateral irradiation is needed even if the contralateral testicle seems normal clinically, as microscopic involvement is common: unilateral orchiectomy is not sufficient, but may be done with lower doses (15 Gy) (3). The penis is taped away from the irradiation field in order to protect the urethra. The responsive testes reduce to the normal size during the first month after treatment (3). Associated intensive re-induction chemotherapy with high doses of MTX is mandatory.
- b. Late TR after bone marrow transplantation: orchiectomy is mandatory (4, 35), but other treatments are controversial, considering previous exposures to chemotherapy and bad prognosis (36).
- c. There is no published protocol specifically considering the technique for orchiectomy

in ALL TR. The concept of avoiding lymphatic spreading of the tumor via scrotal incisions seems to apply, and trans-inguinal radical orchiectomy seems appropriate, as done in primary testicular tumors.

Immunotherapy using CD19-specific chimeric antigen receptor T (CAR-T) cells has shown good results and complete remission in 6/7 patients with isolated TR (5-23 months follow-up), without radiotherapy or orchiectomy. One patient re-recurred (bone marrow), but all showed a complete testicular response (37).

The prognosis varies with the timing of TR: 5 years of survival varies from 13.6% in early recurrences (< 18 months) to 52.2% (18-36 months) and 60% (late recurrences, \geq 36m after treatment), with modern treatment protocols (4).

DISCUSSION

The quality of the information about TR after ALL is a serious problem. Most papers about the TR are from the '80s and the '90s and report on retrospective descriptive cohorts. Many mix children and adults, leukemias and lymphomas, and different types of leukemia together. Also, papers from LMIC are scarce. Most information available comes from developed countries, which usually present more favorable results, and provide easy access to state-of-the-art treatments. This is directly related to the high indexes of TR in LMICs when compared to developed countries, but the effect of worse treatments is difficult to separate from the effect of late diagnoses and the predominance of more advanced cases in LMICs. Also, the protocols may have to be adjusted to the circumstances. Considering the relatively high incidences of TR, would it be useful to adopt post-remission testicular biopsies in LMICs, despite this having been eliminated from developed countries' protocols?

Would it be useful to frequently follow up the testis with imaging after remission? As some suggest, testicular "harbored" blasts may be the origin of systemic leukemia relapse. Would early detection of subclinical testicular nodules facilitate treatment?

Some clinical situations are exceedingly rare (e.g. TR after bone marrow transplantation), making it difficult to evaluate and compare the

treatment strategies and establish reasonable treatment protocols.

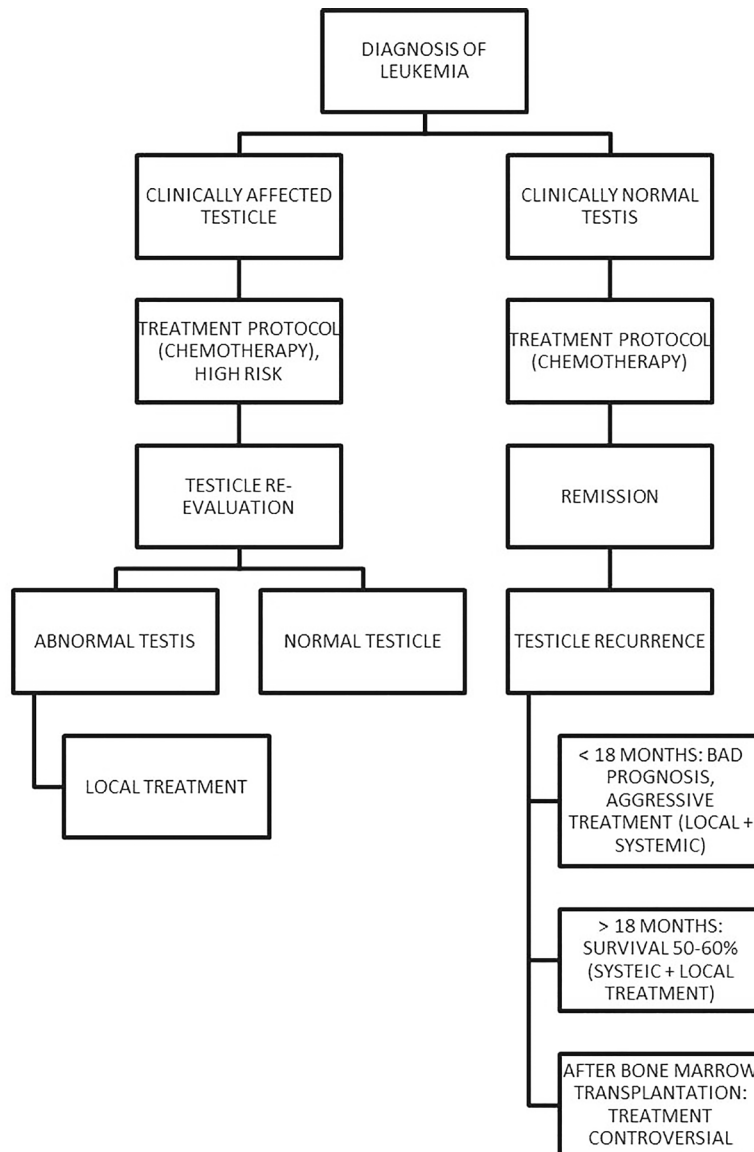
Basic research is needed to understand the testicular-blood barrier in detail. This may deepen our understanding of the immunological response of the testis to leukemic cells and, potentially, suggest new methods of treatment and avoidance of future TR.

A recent paper describing excellent results of immunotherapy may be a first suggestion that

this may also be used to avoid future TR in the future (37). TR, despite being treatable, leads to prolonged chemotherapy, high risks of infertility, and frequent need for external androgens in young adults. Survival after early TR remains dire. New protocols to avoid and treat TR are needed. We suggest herein a treatment algorithm, based on the current state of the art (Figure-2).

In conclusion, testicular affection by ALL is not rare in LMICs, despite being very uncommon

Figure 2 - Treatment algorithm suggested by the authors to treat ALL cases, according to the clinical situation and response to treatments, considering primary testicular affection and testicular recurrence. Local treatment in this context means either ipsilateral orchiectomy or radiotherapy with contralateral biopsy.



in developed nations. Data about this condition are mainly based on results from developed countries in the 20th century, which may not apply to the contemporaneous circumstances found in LMIC. TR worsens prognosis, and is related to late diagnosis of ALL, suggesting that better pediatric health care may help to get earlier diagnoses and to diminish the incidence of testicular ALL. Also, more research is needed on this subject, especially concerning physiopathology and the role of the testes as “leukemia sanctuaries” and about the promising new proposals for the immunological treatment of ALL testicular relapses.

ABBREVIATIONS

ALL = acute lymphocytic leukemia
LMIC = low and middle-income country
TR = testicular recurrence

CONFLICT OF INTEREST

None declared.

REFERENCES

- Gutjahr P, Humpl T. Testicular lymphoblastic leukemia/lymphoma. *World J Urol.* 1995; 13:230-2.
- Ding LW, Sun QY, Mayakonda A, Tan KT, Chien W, Lin DC, et al. Mutational profiling of acute lymphoblastic leukemia with testicular relapse. *J Hematol Oncol.* 2017; 10:65.
- Stoffel TJ, Nesbit ME, Levitt SH. Extramedullary involvement of the testes in childhood leukemia. *Cancer.* 1975; 35:1203-11.
- Nguyen HTK, Terao MA, Green DM, Pui CH, Inaba H. Testicular involvement of acute lymphoblastic leukemia in children and adolescents: Diagnosis, biology, and management. *Cancer.* 2021; 127:3067-81.
- Gaudichon J, Jakobczyk H, Debaize L, Cousin E, Galibert MD, Troadec MB, et al. Mechanisms of extramedullary relapse in acute lymphoblastic leukemia: Reconciling biological concepts and clinical issues. *Blood Rev.* 2019; 36:40-56.
- Jacobs JE, Hastings C. Isolated extramedullary relapse in childhood acute lymphocytic leukemia. *Curr Hematol Malig Rep.* 2010; 5:185-91.
- Kuo TT, Tschang TP, Chu JY. Testicular relapse in childhood acute lymphocytic leukemia during bone marrow remission. *Cancer.* 1976; 38:2604-12.
- Barcos M, Lane W, Gomez GA, Han T, Freeman A, Preisler H, et al. An autopsy study of 1206 acute and chronic leukemias (1958 to 1982). *Cancer.* 1987; 60:827-37.
- Zhou WL, Wu HB, Wang LJ, Tian Y, Dong Y, Wang QS. Usefulness and pitfalls of F-18-FDG PET/CT for diagnosing extramedullary acute leukemia. *Eur J Radiol.* 2016; 85:205-10.
- Kulkarni KP, Marwaha RK, Trehan A, Bansal D. Testicular relapse in childhood acute lymphoblastic leukemia: the challenges and lessons. *Indian J Cancer.* 2010; 47:134-8.
- Ritzén EM. Testicular relapse of acute lymphoblastic leukemia (ALL). *J Reprod Immunol.* 1990; 18:117-21.
- Kamiyama R, Funata N. A study of leukemic cell infiltration in the testis and ovary. *Bull Tokyo Med Dent Univ.* 1976; 23:203-10.
- Kuhajda FP, Haupt HM, Moore GW, Hutchins GM. Gonadal morphology in patients receiving chemotherapy for leukemia. Evidence for reproductive potential and against a testicular tumor sanctuary. *Am J Med.* 1982; 72:759-67.
- Brecher ML, Weinberg V, Boyett JM, Sinks LF, Jones B, Glicksman A, et al. Intermediate dose methotrexate in childhood acute lymphoblastic leukemia resulting in decreased incidence of testicular relapse. *Cancer.* 1986; 58:1024-8.
- Kay HE. Testicular infiltration in acute lymphoblastic leukaemia. *Br J Haematol.* 1983; 53:537-42.
- Jahnukainen K, Salmi TT, Kristinsson J, Müller J, Madsen B, Gustafsson G. The clinical indications for identical pathogenesis of isolated and non-isolated testicular relapses in acute lymphoblastic leukaemia. *Acta Paediatr.* 1998; 87:638-43.
- Mazzu D, Jeffrey RB Jr, Ralls PW. Lymphoma and leukemia involving the testicles: findings on gray-scale and color Doppler sonography. *AJR Am J Roentgenol.* 1995; 164:645-7.
- Kumar PV. Testicular leukemia relapse. Fine needle aspiration findings. *Acta Cytol.* 1998; 42:312-6.
- Gill B, Kogan S, Rossman B, Santorineou M, Radel E, Reda E, et al. Needle biopsy in the diagnosis of testicular leukemia in children. *J Urol.* 1989; 141:1169-71.
- Layfield LJ, Hilborne LH, Ljung BM, Feig S, Ehrlich RM. Use of fine needle aspiration cytology for the diagnosis of testicular relapse in patients with acute lymphoblastic leukemia. *J Urol.* 1988; 139:1020-2.
- de Almeida MM, Chagas M, de Sousa JV, Mendonça ME. Fine-needle aspiration cytology as a tool for the early detection of testicular relapse of acute lymphoblastic leukemia in children. *Diagn Cytopathol.* 1994; 10:44-6.
- Wong KY, Ballard ET, Strayer FH, Kisker CT, Lampkin BC. Clinical and occult testicular leukemia in long-term survivors of acute lymphoblastic leukemia. *J Pediatr.* 1980; 96 (3 Pt 2): 569-74.
- Askin FB, Land VJ, Sullivan MP, Ragab AH, Steuber CP, Dymont PG, et al. Occult testicular leukemia: testicular biopsy at three years continuous complete remission of childhood leukemia: a Southwest Oncology Group Study. *Cancer.* 1981; 47:470-5.

24. Hijjiya N, Liu W, Sandlund JT, Jeha S, Razzouk BI, Ribeiro RC, et al. Overt testicular disease at diagnosis of childhood acute lymphoblastic leukemia: lack of therapeutic role of local irradiation. *Leukemia*. 2005; 19:1399-403.
25. Sirvent N, Suciú S, Bertrand Y, Uyttebroeck A, Lescoeur B, Otten J. Overt testicular disease (OTD) at diagnosis is not associated with a poor prognosis in childhood acute lymphoblastic leukemia: results of the EORTC CLG Study 58881. *Pediatr Blood Cancer*. 2007; 49:344-8.
26. Kim TH, Hargreaves HK, Chan WC, Brynes RK, Alvarado C, Woodard J, et al. Sequential testicular biopsies in childhood acute lymphocytic leukemia. *Cancer*. 1986; 57:1038-41.
27. Hudson MM, Frankel LS, Mullins J, Swanson DA. Diagnostic value of surgical testicular biopsy after therapy for acute lymphocytic leukemia. *J Pediatr*. 1985; 107:50-3.
28. Pui CH, Dahl GV, Bowman WP, Rao BN, Abromowitch M, Ochs J, et al. Elective testicular biopsy during chemotherapy for childhood leukaemia is of no clinical value. *Lancet*. 1985; 2:410-2.
29. Nachman J, Palmer NF, Sather HN, Bleyer WA, Coccia PF, Lukens JN, et al. Open-wedge testicular biopsy in childhood acute lymphoblastic leukemia after two years of maintenance therapy: diagnostic accuracy and influence on outcome--a report from Children's Cancer Study Group. *Blood*. 1990; 75:1051-5.
30. Miller DR, Leikin SL, Albo VC, Palmer NF, Sather HN, Hammond GD. The prognostic value of testicular biopsy in childhood acute lymphoblastic leukemia: a report from the Children's Cancer Study Group. *J Clin Oncol*. 1990; 8:57-66.
31. Grundy RG, Leiper AD, Stanhope R, Chessells JM. Survival and endocrine outcome after testicular relapse in acute lymphoblastic leukaemia. *Arch Dis Child*. 1997; 76:190-6.
32. Eden OB, Lilleyman JS, Richards S. Testicular irradiation in childhood lymphoblastic leukaemia. Medical Research Council Working Party on Leukemia in Childhoods. *Br J Haematol*. 1990; 75:496-8.
33. Amendola BE, Hutchinson R, Grossman HB, Amendola MA. Isolated testicular leukemic relapse. Response to radiation therapy. *Urology*. 1987; 30:240-3.
34. Blatt J, Sherins RJ, Niebrugge D, Bleyer WA, Poplack DG. Leydig cell function in boys following treatment for testicular relapse of acute lymphoblastic leukemia. *J Clin Oncol*. 1985; 3:1227-31.
35. Kodama Y, Okamoto Y, Ijichi O, Shinkoda Y, Nishikawa T, Tanabe T, et al. Continued complete remission without systemic therapy for isolated testicular relapse after bone marrow transplantation in a boy with acute lymphoblastic leukemia. *Pediatr Transplant*. 2009; 13:769-72.
36. Quaranta BP, Halperin EC, Kurtzberg J, Clough R, Martin PL. The incidence of testicular recurrence in boys with acute leukemia treated with total body and testicular irradiation and stem cell transplantation. *Cancer*. 2004; 101:845-50.
37. Chen X, Wang Y, Ruan M, Li J, Zhong M, Li Z, et al. Treatment of Testicular Relapse of B-cell Acute Lymphoblastic Leukemia With CD19-specific Chimeric Antigen Receptor T Cells. *Clin Lymphoma Myeloma Leuk*. 2020; 20:366-370.

Lisieux Eyer de Jesus, MD

Serviço de Cirurgia pediátrica, Hosp. Universitário Antônio Av. Marquês de Paraná, 303, Centro Niterói, RJ, 24033-900, Brasil
E-mail: lisieuxeyerdejesus@gmail.com

ARTICLE INFO

 **Lisieux de Jesus**

<https://orcid.org/0000-0003-0308-1152>

Int Braz J Urol. 2022; 48: 981-7

Submitted for publication:
June 16, 2022

Accepted:
June 24, 2022

Published as Ahead of Print:
August 31, 2022