





# Effect of Photobiomodulation on Pain Following Single Visit Non-surgical Root Canal Treatment of Molar Teeth with Symptomatic Irreversible Pulpitis

Narges Farhad-Mollashahi<sup>1</sup>, Eshagh Ali Saberi<sup>1</sup>, Bitá Aramesh<sup>2</sup>, Farnaz Faramarzian<sup>3</sup>

<sup>1</sup>Oral and Dental Disease Research Center, Department of Endodontics, Faculty of Dentistry, Zahedan University of Medical Sciences, Zahedan, Iran.

<sup>2</sup>Private Practice, Zahedan, Iran.

<sup>3</sup>Department of Endodontics, Faculty of Dentistry, Zahedan University of Medical Sciences, Zahedan, Iran.

**Correspondence:** Farnaz Faramarzian, Department of Endodontics, Faculty of Dentistry, Zahedan University of Medical Sciences, Zahedan, Azadeganst, Khorramshahr Ave, Iran. **E-mail:** [dr.faramarzianfarnaz@gmail.com](mailto:dr.faramarzianfarnaz@gmail.com)

**Academic Editor:** Wilton Wilney Nascimento Padilha

**Received:** 06 December 2022 / **Review:** 04 April 2023 / **Accepted:** 27 April 2023

**How to cite:** Farhad-Mollashahi N, Saberi EA, Aramesh B, Faramarzian F. Effect of photobiomodulation on pain following single visit non-surgical root canal treatment of molar teeth with symptomatic irreversible pulpitis. *Pesqui Bras Odontopediatria Clín Integr.* 2023; 23:e220180. <https://doi.org/10.1590/pboci.2023.087>

## ABSTRACT

**Objective:** To assess the effect of Photobiomodulation (PBM) on post-endodontic pain of mandibular molar teeth with symptomatic irreversible pulpitis. **Material and Methods:** In this clinical trial, mandibular molars with symptomatic irreversible pulpitis underwent primary endodontic treatment in 90 systemically healthy patients. After root canal treatment, the patients were randomly divided into two groups of PBM with diode laser at 940 nm wavelength and 200 mW output power and placebo (mock PBM therapy). Level of pain was recorded at 6, 12, 24, 48, and 72 hours postoperatively using a visual analog scale (VAS). The data were analyzed using the Mann-Whitney test and the Kruskal-Wallis test. **Results:** The results showed that post-endodontic pain at all time points was significantly lower in the PBM group compared with the placebo group. The pain score in the PBM group was significantly lower than the placebo group ( $p < 0.05$ ). However, this difference was not significant at 48 h ( $p = 0.18$ ) and 72 h ( $p = 0.12$ ) postoperatively. Also, the results showed that the mean pain score in males and females in the PBM group was significantly lower than in males and females in the placebo group. **Conclusion:** Photobiomodulation can effectively decrease post-endodontic pain in mandibular molar teeth with symptomatic irreversible pulpitis.

**Keywords:** Root Canal Therapy; Pain; Low-Level Light Therapy.

## Introduction

Post-endodontic pain is the most common complication of endodontic treatment. A systematic review reported that the frequency of post-endodontic pain ranges from 3% to 58% [1]. This pain can be due to an inflammatory process triggered by the extrusion of bacteria, debris and pulpal residues from the root canal system into the periapical tissue and subsequent chemical and/or mechanical injury [2,3]. Such injuries and stimulations would increase the expression and release of neuropeptides from the C nerve fibers present in the periodontal ligament, which would result in postoperative pain and discomfort and prolong the course of recovery [2,3]. Recent studies on post-endodontic pain control have offered several strategies that include pharmacological and non-pharmacological interventions [4]. The pharmacological interventions include the administration of non-steroidal anti-inflammatory drugs (NSAIDs), acetaminophens, antihistamines, opioids, long-acting analgesics and intracanal medicaments [5-7]. Non-pharmacological strategies include anxiety reduction protocols, laser therapy [2,8] and cryotherapy [9].

At present, with an enhanced understanding of the applications of different laser types and their interactions with biological tissues, they are increasingly used for medical and dental purposes. By development of new laser systems that include fine flexible fibers, they can be used for different purposes in endodontic treatment, such as diagnosis of pulp status, pulp capping, pulpotomy, cleaning and disinfection of the root canal system, and control of postoperative pain and inflammation [10].

Photobiomodulation therapy (PBM) uses a low-level laser (LLL) in the visible infrared or near-infrared spectrum with 600 to 1000 nm wavelength and 1 to 20 J/cm<sup>2</sup> energy density. Although the energy density of laser widely varies depending on the actual light source and spot size, values between 5 and 50 mW/cm<sup>2</sup> are commonly used for tissue stimulation and healing, and higher values are used to inhibit the action of nerves and for pain control. PBM is commonly performed to induce tissue regeneration, decrease swelling and inflammation and alleviate pain with its photochemical effect and different irradiation times [11].

A previous study showed that PBM significantly decreased the level of pain in the first four days following non-surgical endodontic retreatment of mandibular molar teeth compared with the placebo, and the amount of analgesics taken was significantly lower in the PBM group [4]. However, Asnaashari et al. [12] found no significant difference in the level of post-endodontic pain at different time intervals between the PBM and placebo groups. Studies on the effects of PBM on endodontic pain after primary endodontic treatment are limited and there seem to be disagreements on the role of phototherapy for post-endodontic pain control. Thus, this study sought to assess the effect of PBM on post-endodontic pain in mandibular molars with symptomatic irreversible pulpitis.

## Material and Methods

### Study Design and Ethical Clearance

This clinical trial was approved by the ethics committee of Zahedan University of Medical Sciences (IR.ZAUMS.REC.1395.24) and registered in the Iranian Registry of Clinical Trials (IRCT2017052834193N1).

### Participants and Procedures

Ninety patients (45 females and 45 males between 20 to 50 years) were selected among those presenting to the Endodontics Department of Zahedan University, School of Dentistry, complaining of moderate to severe pain in their mandibular molar teeth. The pulp vitality status was determined by an electric pulp test (Parkell, Farmingdale, NY, USA), cold test (Hygiene Endo Ice F, Coltene/Whaledent, Germany) and evaluation of the

presence of spontaneous pain or referred pain. Teeth with symptomatic irreversible pulpitis were included in the study (the definite pulp status was determined by the presence/absence of bleeding during access cavity preparation). The patients were informed about the study objectives and willingly signed informed consent forms. A datasheet asking for the age and sex of patients, type of tooth, medical history of patient, pulp status, periapical status, presence of periapical lesions on radiographs, history of previous dental treatments, and history of analgesic intake was filled out for each patient.

The exclusion criteria were previous endodontic treatment of the respective tooth, history of analgesic and medication intake (antibiotics, NSAIDs, opioids or corticosteroids) during 12 hours prior to treatment, pregnancy, malignancy, diabetes mellitus, presence of complex anatomy of the root (severe curvature  $>25^\circ$ ), calcified/obstructed canals on radiographs, very long or very short roots, internal/external root resorption, open-apex teeth, procedural errors, severe periodontal disease, presence of periodontal pockets  $>3$  mm, swelling, sinus tract, presence of a radiographic lesion, tooth hypersensitivity to percussion and absence of occlusal contact. The patients were randomly divided into two groups (the two groups were standardized in terms of age, gender, type of tooth, root curvature and severity of pain before treatment). Patients who were excluded were replaced with new patients. Endodontic treatments were performed by the same operator, who was a post-graduate student of endodontics.

For administration of inferior alveolar nerve block anesthesia in mandibular molar teeth, one cartridge of 2% lidocaine plus 1:80,000 epinephrine (Persocaine; Darupakhsh, Tehran, Iran) was used. If the adequate depth of anesthesia was not achieved, another anesthetic injection was performed. The procedure was started after achieving adequate lip anesthesia. Rubber dam isolation was performed and an access cavity was prepared using a round bur and high-speed hand-piece under water and air spray. The working length of the canals was determined -1mm to the apical foramen by introducing a #15 K-file (Mani, Tochigi, Japan) into the canals using Root ZX apex finder (J Morita Corp., Tokyo, Japan) and was confirmed by digital radiography. The root canals were prepared using Reciprosystem (VDW, Munich, Germany) according to the manufacturer's instructions. A new Reciproc file was used for each patient.

During root canal preparation, 2.5% sodium hypochlorite was used for root canal irrigation and 5 mL of 1% sodium hypochlorite, followed by 5 mL of 17% EDTA, each for 1 minute, were used for smear layer removal. A final rinse with saline was also performed.

The root canals were dried with sterile paper points and filled with gutta-percha and AH Plus sealer (Dentsply DeTrey, Konstanz, Germany) with lateral compaction technique in the same session. The optimal quality of obturation was ensured by taking a final radiograph.

Occlusal contacts with the opposing teeth were eliminated in endodontically-treated teeth. Teeth with technical problems and procedural errors such as perforation, canal transportation, missed canals and poor quality of obturation were excluded. The access cavity was temporarily sealed with a temporary restorative material. After completion of endodontic treatment, the patients were randomly divided into two groups of Photobiomodulation therapy and placebo (mock Photobiomodulation therapy). Endodontic treatment in all patients was performed by the same operator, while Photobiomodulation was performed by another operator.

In the PBM group, a low-level diode laser (Epic™10 Diode laser; Biolase Technology, Irvine, CA, USA) with 940 nm wavelength, 200 mW output power and a glass fiber tip with 400  $\mu$ m diameter in continuous-wave mode was used. The laser was irradiated to the buccal and lingual surfaces of the root of the mandibular molar at the level of the apex for 30 seconds. The fiber tip of the laser was positioned perpendicular to the surface and close to the soft tissue.

In the placebo group, the fiber tip of laser was positioned over the buccal and lingual surface of the tooth at the level of the apex, but no irradiation was performed.

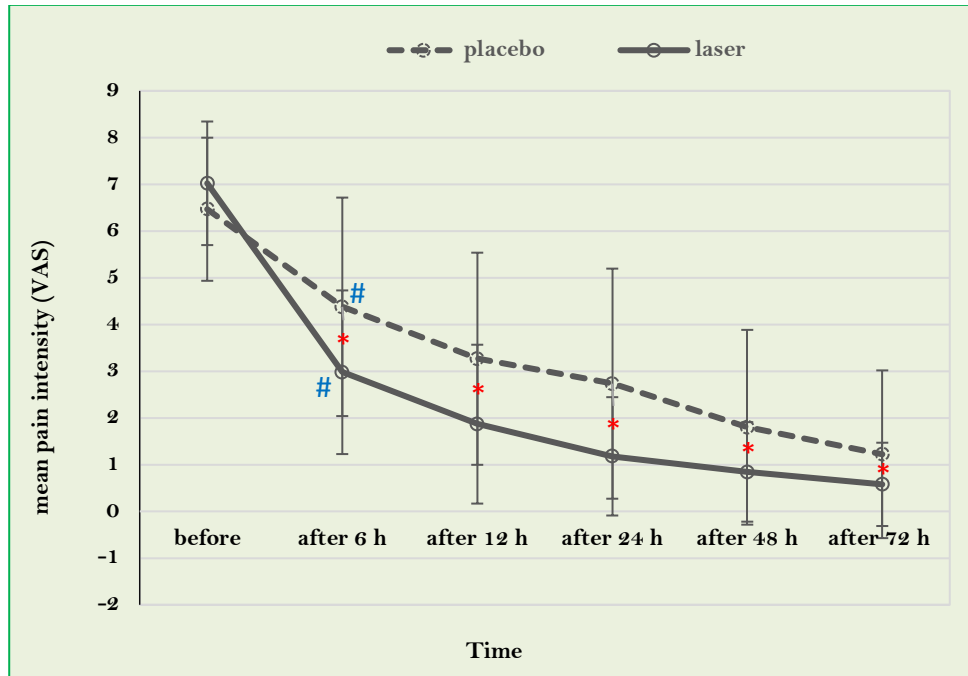
The patients reported the level of pain experienced at 6, 12, 24, 48, and 72 hours postoperatively using a visual analog scale (VAS). Moreover, they received an envelope containing 6 ibuprofen tablets (400 mg each) along with the instructions for use and they were requested to take tablets in case of experiencing severe pain. They were also asked to record the number of analgesics taken in a form. Independent observers blinded to the group allocation of patients evaluated the VAS forms of patients.

### Data Analysis

The data were analyzed using the IBM SPSS (IBM Corp., Armonk, NY, USA). The Chi-square, Mann Whitney and the Kruskal-Wallis tests were used. The significance level adopted was 5%.

### Results

Of all, 44 patients (48.9%) were females and 46 patients (51.1%) were males. The difference in gender distribution was not significant between the two groups ( $p > 0.05$ ). The patients' ages ranged from 20 to 50 years and the mean age was 39 years in the PBM group and 34 years in the placebo group. No significant difference was noted between the two groups in terms of age or preoperative pain ( $p > 0.05$ ). Both groups reported significantly lower level of pain after treatment compared with their preoperative pain score. According to the Mann-Whitney and Kruskal-Wallis tests, post-endodontic pain at all time points was significantly lower in the PBM group compared with the placebo group (Figure 1).



\*Kruskal-Wallis test for within-group comparison at different time points; #Mann Whitney test for the comparison of the two groups at a certain time point.

**Figure 1. Comparison of the mean pain score in laser and placebo groups at various intervals.**

The Chi-square test was used to compare the frequency of pain scores in the PBM and placebo groups. The results showed significant differences in pain scores between the two groups at 6, 12, and 24 hours,

postoperatively, and the pain score in PBM group was significantly lower than that in the placebo group ( $p < 0.05$ ). However, this difference was not significant at 48 h ( $p = 0.18$ ) and 72 h ( $p = 0.12$ ) postoperatively (Figure 2).

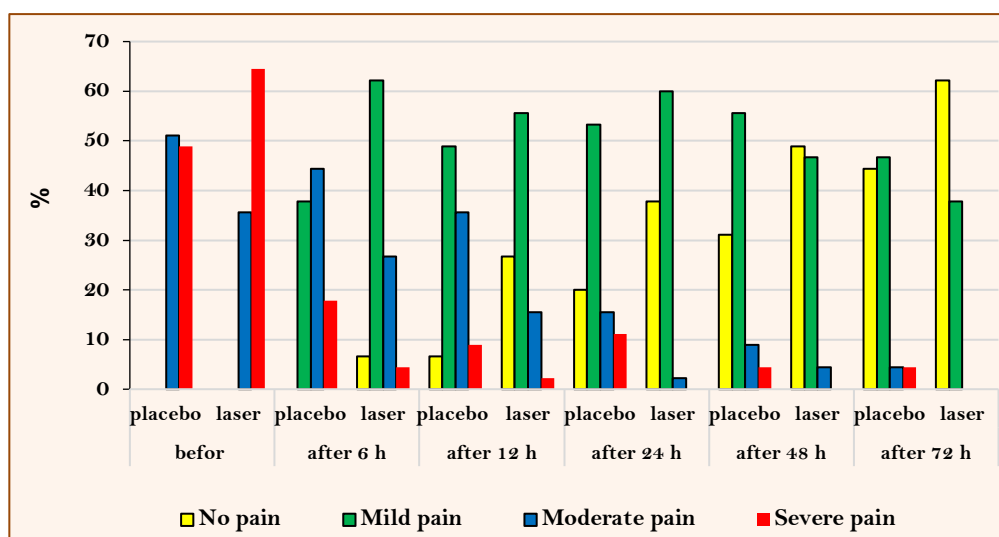


Figure 2. Comparison of the frequency of pain scores between the laser and placebo groups at various intervals.

The Mann-Whitney test was used to compare the mean pain score in males and females in the two groups. The results showed that females experienced significantly lower mean pain scores than the placebo at 12 and 24 hours ( $p = 0.01$ ). However, this difference was not significant at 6, 48 and 72 hours ( $p > 0.05$ ). The mean pain score in males in the PBM group was significantly lower than that of males in the placebo group at all time points ( $p < 0.05$ ) (Table 1).

Table 1. Comparison of the mean pain score of males and females in laser and placebo groups at various time intervals.

Time	Group	Female			Male		
		Mean	SD	p-value	Mean	SD	p-value
Before treatment	Placebo	6.55	1.41	0.355	6.39	1.67	0.109
	Laser	6.95	1.50		7.09	1.16	
After 6h	Placebo	4.59	2.42	0.066	4.17	2.29	0.011
	Laser	3.41	1.65		2.57	1.78	
After 12h	Placebo	3.64	2.11	0.013	2.91	2.41	0.034
	Laser	2.23	1.45		1.52	1.88	
After 24h	Placebo	3.05	2.50	0.010	2.43	2.45	0.011
	Laser	1.41	1.40		0.96	1.11	
After 48h	Placebo	1.91	1.95	0.125	1.70	2.24	0.028
	Laser	1.14	1.25		0.57	0.79	
After 72h	Placebo	1.36	1.87	0.375	1.09	1.76	0.028
	Laser	0.95	1.05		0.22	0.52	

SD: Standard Deviation.

## Discussion

Adopting a clinical approach in endodontic treatment can affect the efficacy and biological consequences of treatment and decrease the patient discomfort. Thus, single-session root canal treatment is now a common modality with numerous advantages, such as decreased frequency of flare-ups, fewer treatment sessions, and eliminating the risk of leakage between sessions by temporary restoration of the tooth [13]. However, post-

endodontic pain and subsequent healing are common concerns in single-session endodontic treatment of teeth because patients undergoing single-session endodontic treatment have shown a higher frequency of analgesic intake for pain control [12,14].

Our results showed that 100% of patients in both groups had moderate to severe pain before endodontic treatment and were clinically considered to have significant pain. However, in the first 6 hours after endodontic treatment, 37.78% of patients in the placebo group had mild pain and 68.89% of patients in the PBM group had no pain or mild pain. In the first 24 hours postoperatively, 73.33% of patients in the placebo group and 97.8% in the PBM group had no pain or mild pain.

When focusing on pain mechanisms (pulpotomy, root canal therapy), a significant reduction in pain after treatment is expected, irrespective of the treatment technique. However, pain control strategies (pharmacotherapy and Photobiomodulation) seem necessary to decrease the continuous stimulation of nociceptors [15].

Our results showed that the level of pain experienced by patients significantly decreased in the first 6 hours after treatment; this reduction was mainly due to definitive dental treatment in both groups. However, the mean pain score in the PBM group was significantly lower than that in the placebo group at all time points.

In this study, a diode laser with a 940 nm wavelength was used for PBM. PBM has shown optimal efficacy for significant reduction of inflammatory pain due to third molar extraction surgery [16], post-endodontic pain [17,18], post-orthodontic pain [19], mucositis [20], myofascial pain [21], temporomandibular disorders [22] and dentin hypersensitivity [23]. Our results were in agreement with those of Doğanay Yıldız and Arslan [18], who evaluated teeth with irreversible pulpitis that were treated within a single session. They reported significant reduction of pain at 1 and 3 days, postoperatively due to PBM. However, Asnaashari et al. [12] found no significant difference in pain scores between the PBM and placebo groups. It should be noted that our study was conducted on vital teeth while they evaluated teeth that had undergone primary endodontic treatment.

Evidence shows that laser irradiation with 500 to 1200 nm wavelength (LLL) is optimal for PBM purposes. LLLs are non-thermal. Although their exact analgesic mechanism has not yet been clearly elucidated, there is a popular theory stating that LLL has low absorption by the skin. It penetrates deep into the underlying tissues and exerts PBM effects [24].

Laser can cause the release of serotonin and acetylcholine at the site of its concentration and exert neuro-pharmacological analgesic effects [25]. Moreover, evidence shows that laser irradiation of non-myelinated nerve fibers with small diameters, such as nociceptors, decreases neural stimulation compared with conventional stimuli [26]. On the other hand, laser irradiation for less than 10 minutes is sufficient to inhibit and control inflammation by 20% to 30% [27]. It causes a reduction in the level of prostaglandin E<sub>2</sub>, which is a detectable parameter to describe pain reduction in rheumatoid arthritis patients [28]. Moreover, a low-power laser can affect the synthesis of prostaglandins and increase the conversion of prostaglandin D<sub>2</sub> and H<sub>2</sub> to prostaglandin I<sub>2</sub>, which has vasodilatory, anti-inflammatory and immunosuppressive effects [29]. Moreover, the analgesic effects of laser can be attributed to the reduction in concentration of chemical agents such as histamine, acetylcholine, serotonin, H<sup>+</sup>, and K<sup>+</sup> and increased activity of acetylcholine esterase. LLLs can also cause vasodilation and increase the blood supply to the tissues. On the other hand, they increase the lymphatic drainage and decrease edema. By reduction of edema and elimination of pressure from the nerve ends, they are less stimulated; consequently, the sensitivity of pain receptors decreases. Moreover, LLLs decrease the permeability of cell membranes for Na<sup>+</sup> and K<sup>+</sup> and cause hyperpolarization of neurons and increase the pain threshold. On

the other hand, electromagnetic laser energy increases the metabolism of the injured tissue by the production of ATP and repolarization of cell membrane. It exerts analgesic effects by adjusting the activity of the adrenaline-noradrenaline system and increasing the urinary excretion of serotonin and glucocorticoids and the production of beta-endorphins [30].

Considering the abovementioned possible mechanisms, the reduction in the mean pain score in the PBM group compared with the placebo can be justified. Pain relief caused by laser irradiation may be associated with an increased level of plasma beta-endorphins [31]. Also, the immediate, delayed and long-term effects of PBM are associated with increased activity of macrophages at the site, which causes faster resorption of hematoma and edema and enhanced auto-immunological reactions at the site of injury [32].

Some studies have reported a higher prevalence of postoperative pain in females compared with males [15,24-26], while some others reported that gender had no effect on the level of pain experienced after endodontic treatment [18,33,34]. In our study, no significant difference existed in the mean pain score of females in the two groups in the first 6 hours. However, the mean pain score of females in the PBM group was significantly lower than that in the placebo group at 12 and 24 hours postoperatively. This difference was no longer significant at 48 and 72 hours postoperatively. However, the mean pain score in males in the PBM group was significantly lower than that in the placebo group at all time points. This difference may be attributed to higher expression of pain by females in the first hours after treatment or may be due to delayed expression of PBM effects of laser on females, which did not continue for the first 24 hours postoperatively. Alternatively, it may be due to the biphasic dose-response pattern of LLL [35]. Evidence shows that when the number of laser irradiation sessions and energy density of laser are adjusted individually for each case based on patient requirements, the peak of beneficial neurological effects can be observed according to the biphasic pattern of LLLs [11].

In order to compensate the inefficacy of laser in the first 6 hours, postoperatively in females, a higher total energy may be used. Also, laser irradiation can be repeated to prolong the effects of laser after treatment. This approach can be evaluated in future studies. However, repetition of laser irradiation for several days after treatment may not be practical and the easiest way may be the analgesic intake by patients considering the fact that patients often experience mild pain during this time period, which quickly responds to simple analgesics [17].

No previous study is available on the difference in response of male and female patients to laser irradiation. Also, it is not known what percentage of laser is transmitted, referred, scattered or absorbed by different tissues. This can be related to the thickness and molecular composition of tissues [17]. Differences in the abovementioned parameters may be responsible for the difference in response of males and females to laser irradiation. Future studies are required to focus on the biphasic dose-response pattern of laser.

Although the study had a well-developed methodologically and had few biases, there were limitations. The limitations of this clinical research were related to the difficulty in evaluating post-endodontic pain, since the level of subjectivity in measuring pain is high. Each person's pain threshold is unique. For this reason, the choice of the questionnaire is essential and must ensure that the questions are fully understood by the patients and can be interpreted by the researchers. In the present study, the VAS was chosen because it is widely used in the scientific and endodontic literature [36-39] and for being simple, efficient, easy to understand and reliable for assessing pain intensity. The other factors that could influence the presence and intensity of pain were the preoperative conditions of the teeth and their anatomical condition. To minimize the effects of these variables, only mandibular molars were selected and those diagnosed with irreversible pulpitis. The randomization of the





patients ensured that variables such as gender, age, and preoperative pain were equally distributed among the groups and not considered confounding factors.

There is not enough evidence on the ideal standard laser parameters (i.e., wavelength, power, energy density, radiation duration), and the distance from the target surface, and the number of therapeutic sessions. Thus, it seems that more well-conducted studies with larger samples and different settings are required for a comprehensive conclusion to be drawn about the effects of photobiomodulation lasers on post-endodontic pain.

## Conclusion

The photobiomodulation can be used for pain control after primary endodontic treatment of mandibular molars with symptomatic irreversible pulpitis.

## Authors' Contributions

NFM	 <a href="https://orcid.org/0000-0002-6174-1473">https://orcid.org/0000-0002-6174-1473</a>	Conceptualization, Methodology, Formal Analysis, Investigation, Data Curation, Writing - Original Draft and Writing - Review and Editing.
EAS	 <a href="https://orcid.org/0000-0002-4832-0965">https://orcid.org/0000-0002-4832-0965</a>	Conceptualization, Methodology, Formal Analysis, Investigation, Data Curation, Writing - Original Draft and Writing - Review and Editing.
BA	 <a href="https://orcid.org/0000-0003-3948-1131">https://orcid.org/0000-0003-3948-1131</a>	Conceptualization, Methodology, Formal Analysis, Investigation, Data Curation, Writing - Original Draft and Writing - Review and Editing.
FF	 <a href="https://orcid.org/0000-0002-0545-4808">https://orcid.org/0000-0002-0545-4808</a>	Conceptualization, Methodology, Formal Analysis, Investigation, Data Curation, Writing - Original Draft and Writing - Review and Editing.
All authors declare that they contributed to critical review of intellectual content and approval of the final version to be published.		

## Financial Support

None.

## Conflict of Interest

The authors declare no conflicts of interest.

## Data Availability

The data used to support the findings of this study can be made available upon request to the corresponding author.

## Acknowledgements

This study was part of an academic thesis for a Master's degree in Endodontics which was accepted by the Deputy of Research of Dental School, Zahedan University of Medical Sciences (IR.ZAUMS.REC.1395.24).

## References

- [1] Sathorn C, Parashos P, Messer HJ. The prevalence of postoperative pain and flare-up in single- and multiple-visit endodontic treatment: a systematic review. *Int Endod J* 2008; 41(2):91-9. <https://doi.org/10.1111/j.1365-2591.2007.01316.x>
- [2] Lopes LPB, Herkrath FJ, Vianna ECB, Gualberto Júnior EC, Marques AAF, Sponchiado Júnior EC. Effect of photobiomodulation therapy on postoperative pain after endodontic treatment: a randomized, controlled, clinical study. *Clin Oral Investig* 2019; 23(1):285-92. <https://doi.org/10.1007/s00784-018-2435-9>
- [3] Anagha CS, Koshy M, Varghese R, Anirudhan S. Comparison of postoperative pain following single-visit and two-visit root canal therapy in controlled diabetic patients with irreversible pulpitis: A randomized control trial. *J Conserv Dent* 2022; 25(4):392-7. [https://doi.org/10.4103/jcd.jcd\\_18\\_22](https://doi.org/10.4103/jcd.jcd_18_22)
- [4] Fazlyab M, Esmaeili Shahmirzadi S, Esnaashari E, Azizi A, Moshari AA. Effect of low-level laser therapy on postoperative pain after single-visit root canal retreatment of mandibular molars: A randomized controlled clinical trial. *Int Endod J* 2021; 54(11):2006-15. <https://doi.org/10.1111/iej.13608>
- [5] Ryan JL, Jureidini B, Hodges JS, Baisden M, Swift JQ, Bowles WR. Gender differences in analgesia for endodontic pain. *J Endod* 2008; 34(5):552-6. <https://doi.org/10.1016/j.joen.2008.01.021>
- [6] Arslan H, Gündoğdu EC, Sümbüllü M. The effect of preoperative administration of antihistamine, analgesic and placebo on postoperative pain in teeth with symptomatic apical periodontitis: A randomized controlled trial. *Eur Endod J* 2016; 1(1):1-5. <https://doi.org/10.5152/ej.2016.16012>



- [7] Aneja K, Gupta A, Abraham D, Aggarwal V, Sethi S, Chauhan P, et al. Influence of vehicle for calcium hydroxide on postoperative pain: a scoping review. *J Dent Anesth Pain Med* 2022; 22(2):75-86. <https://doi.org/10.17245/jdapm.2022.22.2.75>
- [8] Tunc F, Yildirim C, Alacam T. Evaluation of postoperative pain/discomfort after intracanal use of Nd:YAG and diode lasers in patients with symptomatic irreversible pulpitis and asymptomatic necrotic pulps: a randomized control trial. *Clin Oral Investig* 2021; 25(5):2737-44. <https://doi.org/10.1007/s00784-020-03588-8>
- [9] Sadaf D, Ahmad MZ, Onakpoya IJ. Effectiveness of intracanal cryotherapy in root canal therapy: A systematic review and meta-analysis of randomized clinical trials. *J Endod* 2020; 46(12):1811-1823.e1. <https://doi.org/10.1016/j.joen.2020.08.022>
- [10] Ingle JI, Bakland LK, Baumgartner JC. Ingle's Endodontics 6. BC Decker; 2008. 1555p.
- [11] Huang YY, Sharma SK, Carroll J, Hamblin MR. Biphasic dose response in low level light therapy - an update. *Dose Response* 2011; 9(4):602-18. <https://doi.org/10.2203/dose-response.11-009.Hamblin>
- [12] Asnaashari M, Ashraf H, Daghighyeghi AH, Mojahedi SM, Azari-Marhabi S. Management of post endodontic retreatment pain with low level laser therapy. *J Lasers Med Sci* 2017; 8(3):128-31. <https://doi.org/10.15171/jlms.2017.23>
- [13] Sipavičiūtė E, Manelienė R. Pain and flare-up after endodontic treatment procedures. *Stomatologija* 2014; 16(1):25-30.
- [14] Shahnaz N, Masoodi A, Amin K, Baba IA. Management of post endodontic pain following single visit endodontics: areview. *Int J Dent Health Sci* 2015; 2(2):396-405.
- [15] Alqaderi H, Lee CT, Borzangy S, Pagonis TC. Coronal pulpotomy for cariously exposed permanent posterior teeth with closed apices: A systematic review and meta-analysis. *J Dent* 2016; 44:1-7. <https://doi.org/10.1016/j.jdent.2015.12.005>
- [16] Domah F, Shah R, Nurmatov UB, Tagiyeva N. The use of low-level laser therapy to reduce postoperative morbidity after third molar surgery: A systematic review and meta-analysis. *J Oral Maxillofac Surg* 2021; 79(2):313.e1-313.e19. <https://doi.org/10.1016/j.joms.2020.09.018>
- [17] Kreisler MB, Haj HA, Noroozi N, Willershausen Bd. Efficacy of low level laser therapy in reducing postoperative pain after endodontic surgery—A randomized double blind clinical study. *Int J Oral Maxillofac Surg* 2004; 33(1):38-41. <https://doi.org/10.1054/ijom.2002.0449>
- [18] Doğanay Yıldız E, Arslan H. Effect of low-level laser therapy on postoperative pain in molars with symptomatic apical periodontitis: A randomized placebo-controlled clinical trial. *J Endod* 2018; 44(11):1610-5. <https://doi.org/10.1016/j.joen.2018.07.002>
- [19] Alam MK. Laser-assisted orthodontic tooth movement in Saudi population: A prospective clinical intervention of low-level laser therapy in the 1st week of pain perception in four treatment modalities. *Pain Res Manag* 2019; 2019:6271835. <https://doi.org/10.1155/2019/6271835>
- [20] Biala M. Low-level laser therapy: A literature review of the prevention and reduction of oral mucositis in patients undergoing stem cell transplantation. *Clin J Oncol Nurs* 2022; 26(3):293-9. <https://doi.org/10.1188/22.CJON.293-299>
- [21] Bradley P, Heller GJP. The effect of 830 nm laser on chronic myofascial pain. *Pain* 2006; 124(1):2.
- [22] Tunér J, Hosseinpour S, Fekrazad R. Photobiomodulation in temporomandibular disorders. *Photobiomodul Photomed Laser Surg* 2019; 37(12):826-36. <https://doi.org/10.1089/photob.2019.4705>
- [23] El Mobadder M, Namour A, Namour M, Dib W, El Mobadder W, Maalouf E, et al. Dentinal hypersensitivity treatment using diode laser 980 nm: In vivo study. *Dent J* 2019; 7(1):5. <https://doi.org/10.3390/dj7010005>
- [24] Pawar SS, Pujar MA, Makandar SD, Khaiser MI. Postendodontic treatment pain management with low-level laser therapy. *J Dent Lasers* 2014; 8(2):60-3. <https://doi.org/10.4103/0976-2868.145141>
- [25] Pires de Sousa MV, Ferraresi C, Kawakubo M, Kaippert B, Yoshimura EM, Hamblin MR. Transcranial low-level laser therapy (810 nm) temporarily inhibits peripheral nociception: photoneuromodulation of glutamate receptors, prostatic acid phosphatase, and adenosine triphosphate. *Neurophotonics* 2016; 3(1):015003. <https://doi.org/10.1117/1.NPh.3.1.015003>
- [26] Baxter D, Walsh D, Wright A. A microneurographic investigation of the neurophysiological effects of low-intensity laser. Abstracts London Laser 1992; Second Meeting of the International Laser Therapy Association #30.
- [27] Honmura A, Yanase M, Obata J, Haruki E. Therapeutic effect of Ga-Al-As diode laser irradiation on experimentally induced inflammation in rats. *Lasers Surg Med* 1992; 12(4):441-9. <https://doi.org/10.1002/lsm.1900120414>
- [28] Barberis G, Gamron S, Acevedo G, Cadile I, Juri H, Campana V, et al. In vitro synthesis of prostaglandin E2 by synovial tissue after helium-neon laser radiation in rheumatoid arthritis. *J Clin Laser Med Surg* 1996; 14(4):175-7. <https://doi.org/10.1089/clm.1996.14.175>
- [29] Dorris SL, Peebles RS Jr. PGI2 as a regulator of inflammatory diseases. *Mediators of inflammation* 2012; 2012:926968. <https://doi.org/10.1155/2012/926968>
- [30] Khalighi HR, Anbari F, Beygom Taheri J, Bakhtiari S, Namazi Z, Pouralibaba F. Effect of low-power laser on treatment of orofacial pain. *J Dent Res Dent Clin Dent Prospects* 2010; 4(3):75-8. <https://doi.org/10.5681/joddd.2010.019>
- [31] Kisselev SB, Moskvina SV. The use of laser therapy for patients with fibromyalgia: A critical literary review. *J Lasers Med Sci* 2019; 10(1):12-20. <https://doi.org/10.15171/jlms.2019.02>

- [32] Shiroto C, Sugawara K, Kumae T, Ono Y, Sasaki M, Ohshiro TJLT. Effect of diode laser radiation in vitro on activity of human neutrophils. *Laser Therapy* 1989; 1(3):135.
- [33] Cheng Y, Cheung GS, Bian Z, Peng B. Incidence and factors associated with endodontic inter-appointment emergency in a dental teaching hospital in China. *J Dent* 2006; 34(7):516-21. <https://doi.org/10.1016/j.jdent.2005.12.003>
- [34] Alves Vde O. Endodontic flare-ups: a prospective study. *Oral Surg Oral Med Oral Pathol Oral Radiol Endod* 2010; 110(5):e68-72. <https://doi.org/10.1016/j.tripleo.2010.05.014>
- [35] de Oliveira AR, Vanin AA, Tomazoni SS, Miranda EF, Albuquerque-Pontes GM, De Marchi T, et al. Pre-exercise infrared photobiomodulation therapy (810 nm) in skeletal muscle performance and postexercise recovery in humans: What is the optimal power output? *Photomed Laser Surg* 2017; 35(11):595-603. <https://doi.org/10.1089/pho.2017.4343>
- [36] Coelho MS, Vilas-Boas L, Tawil PZ. The effects of photodynamic therapy on postoperative pain in teeth with necrotic pulps. *Photodiagnosis Photodyn Ther* 2019; 27:396-401. <https://doi.org/10.1016/j.pdpdt.2019.07.002>
- [37] Cruz Junior JA, Santos Coelho M, Shoji Kato A, Vivacqua-Gomes N, Fontana CE, Pedro Rocha DG, et al. The effect of foraminal enlargement of necrotic teeth with the reciproc system on postoperative pain: A prospective and randomized clinical trial. *J Endod* 2016; 42(1):8-11. <https://doi.org/10.1016/j.joen.2015.09.018>
- [38] Saini HR, Sangwan P, Sangwan A. Pain following foraminal enlargement in mandibular molars with necrosis and apical periodontitis: A randomized controlled trial. *Int Endod J* 2016; 49(12):1116-1123. <https://doi.org/10.1111/iej.12583>
- [39] Yaylali IE, Kurnaz S, Tunca YM. Maintaining apical patency does not increase postoperative pain in molars with necrotic pulp and apical periodontitis: A randomized controlled trial. *J Endod* 2018; 44(3):335-40. <https://doi.org/10.1016/j.joen.2017.11.013>