

## The effects of boric acid and quercetin on contrast media-induced nephropathy in rats

Kenan Yilmaz<sup>1</sup>, Selcuk Yazici<sup>2</sup>, Teoman Ozcan<sup>3</sup>, Eren Altun<sup>4</sup>

<sup>1</sup>Balikesir University, Faculty of Medicine, Department of Pediatric Nephrology, Turkey,

<sup>2</sup>Balikesir University, Faculty of Medicine, Department of Child Health and Diseases, Turkey,

<sup>3</sup>Balikesir University, Faculty of Medicine, Department of Pediatric Surgery, Turkey,

<sup>4</sup>Balikesir University, Faculty of Medicine, Department of Pathology, Turkey

We aimed to determine the effects of boric acid and quercetin on contrast media-induced nephropathy in rats. Thirty-two rats were divided into four equal groups with eight rats in each group: the control (C) group, contrast media (CM) group, contrast media plus boric acid (CMB) group, and contrast media plus quercetin (CMQ) group. Boric acid ( $H_3(BO)_3$ , 4% solution) at a dose of 200 mg/kg was administered by oral gavage to rats in the group CMB once daily for 4 consecutive days (days 1 to 4). Quercetin at a dose of 50 mg/kg was administered by oral gavage to rats in the CMQ group once daily for 4 consecutive days (days 1 to 4). A significant decrease was found in the serum urea and creatinine levels in the CMQ group compared with the CM group ( $P < 0.01$ ). The serum nitrite and nitrate levels were higher in the CM group than in the C group and were lower in the CMQ group than in the CM group ( $P < 0.01$ ). A significant decrease in the severity of tubular necrosis was found in the CMQ group compared to the CM group ( $P < 0.05$ ). Quercetin had protective effects against contrast nephropathy, but no beneficial effect of boric acid was found.

**Keywords:** Boric acid. Contrast media. Kidney. Rat. Quercetin.

### INTRODUCTION

Contrast media nephropathy (CMN), known as acute renal failure excluding all other causes, may lead to renal insufficiency after intravascular contrast media use. CMN is the third most common cause of hospital-acquired acute renal failure (Pistolesi *et al.*, 2018). CMN is defined as a 0.5 mg/dL increase in serum creatinine level or a 25% increase in basal creatinine values within 48-72 hours after contrast agent administration. CMN develops in 5-6.4% of patients exposed to contrast media (van der Molen *et al.*, 2018). CMN can lead to prolonged hospitalization, morbidity, mortality and even irreversible renal insufficiency. The mortality rate of CMN is approximately 30% (Hocine

*et al.*, 2016). CMN usually improves within one to two weeks. Prolonged hospitalization increases the risk of complications. Therefore, determining the risk factors for CMN, taking necessary precautions and identifying effective treatments are important. Hence, preventive treatment strategies for CMN have been investigated in many studies (Pistolesi *et al.*, 2018; Andreucci *et al.*, 2014). The effects of boron and its compounds on human organisms are still discussed today. In addition, boron has many physiological effects such as pain and edema reducing effects, fracture healing effects and some anticancer effects due to its antiproliferative properties (Feng *et al.*, 2016; Chen *et al.*, 2015; Demirci *et al.*, 2016). In some studies, boric acid has been shown to cause toxicity in the kidneys as a result of accumulation (Sabuncuoglu *et al.*, 2006; Pazirandeh, Jameie, Zargar, 2009). In contrast, different experimental studies have reported that boric acid has some nephroprotective effects (Cengiz, 2018). To date, no experimental study

\*Correspondence: K. Yilmaz. Department of Pediatric Nephrology, Faculty of Medicine, Balikesir University, Cagis Campus, 10145, Balikesir-Turkey. Phone: 90 5444432826. E-mail: kenanylmz68@hotmail.com

investigating the effects of boric acid on contrast media-induced nephropathy has been conducted. Therefore, we aimed to determine the effect of boric acid application on contrast nephropathy in rats.

Quercetin is a polyphenolic bioactive agent found in many fruits and vegetables. Quercetin has a wide range of biological activities including antioxidant, antihypertensive, anti-inflammatory, antiapoptotic, cardioprotective and antibacterial activities (Li *et al.*, 2014; Al-Rasheed *et al.*, 2017; Harwood *et al.*, 2007). The nephroprotective activity of quercetin has been determined in different experimental models (Shoskes, 1998; Gomes *et al.*, 2014; Mahesh, Menon, 2004). A study of low osmolar iodine-induced renal toxicity by Guss *et al.* (2017) showed that quercetin does not have adequate protective effects. Hence, we aimed to determine the effects of quercetin on nephropathy induced by high-osmolar meglumine-sodium diatrizoate.

## MATERIAL AND METHODS

### Animals

Thirty-two female albino Wistar rats (weighing 220-250 g on average) were used in the study. The experimental animals were kept in individual cages and were maintained on a 12-hour light/dark cycle at a room temperature of 22-24°C.

### Experimental protocols and drugs

Thirty-two rats were divided into four equal groups with eight rats in each group: group 1 (the control (C) group), group 2 (the contrast media (CM) group), group 3 (the contrast media plus boric acid (CMB) group), and group 4 (the contrast media plus quercetin (CMQ) group). Boric acid ( $H_3(BO)_3$ , 4% solution; (Sigma-Aldrich, USA, CAS no. 10043-35-3) was administered at a dose of 200 mg/kg by oral gavage to the rats in the CMB group once daily for 4 consecutive days (days 1 to 4). Quercetin (Sigma-Aldrich) was administered at a dose of 50 mg/kg by oral gavage to the rats in the CMQ group once daily for 4 consecutive days (days 1

to 4). Twenty-four hours before contrast administration, animals were allowed limited access to water. After this period, animals from the CM, CMB and CMQ groups received high-osmolar contrast medium, meglumine-sodium diatrizoate (76% Urografin, Bayer), at a dose of 6 ml/kg through the tail vein (day 2). All rats were given unrestricted access to standard rat food. After 5 days, the rats were sacrificed, and blood samples were collected from the abdominal aorta and right kidneys and stored in 10% neutral buffered formalin.

All procedures performed in the studies involving animals were in accordance with the ethical standards of the institution or practice at which the studies were conducted (decision number: 2018/4-1).

### Biochemical analysis

The levels of serum urea and creatinine were measured with an autoanalyzer (Beckman Coulter AU 680) at Medical Biochemistry Laboratories. We analyzed serum nitrite and nitrate concentrations by the Griess reaction method according to the kit instructions (Sigma-Aldrich, USA, catalog number: 23479). All work was repeated twice (Kiss *et al.*, 2010; Kovacs *et al.*, 2015).

### Histopathological analysis

The right kidneys were evaluated for histopathological changes. Slides were examined and photographed under a light microscope (Nikon Eclipse CI, Amsterdam, The Netherlands) by a blinded pathologist. Histopathological changes (tubular necrosis, proteinaceous casts and medullary congestion) were scored in accordance with the following scale: negative: 0; mild: 1; moderate: 2; severe: 3; very severe: 4.

### Statistical analyses

IBM SPSS, version 25.0 was used for biochemical and histopathologic scoring analysis. Comparisons between groups were performed by one-way ANOVA followed by post hoc Tukey's multiple comparison test. Identical letters in the colons indicate statistical insignificance; different letters in the colons indicate

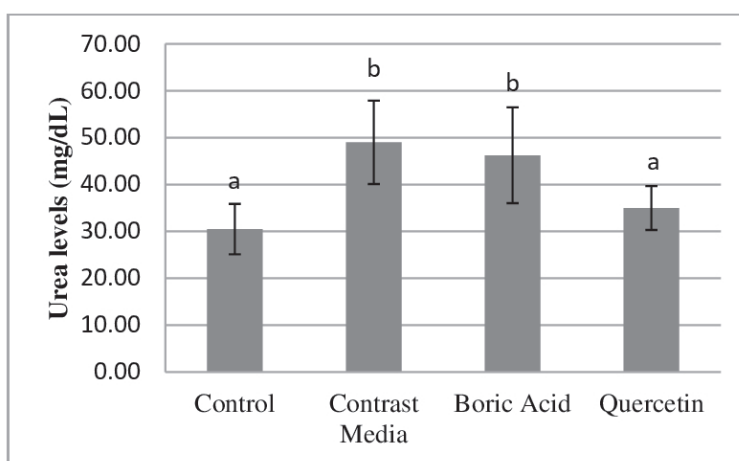
statistical significance. The mean and standard deviation values were used for analysis.  $P < 0.05$  was considered significant.

## RESULTS

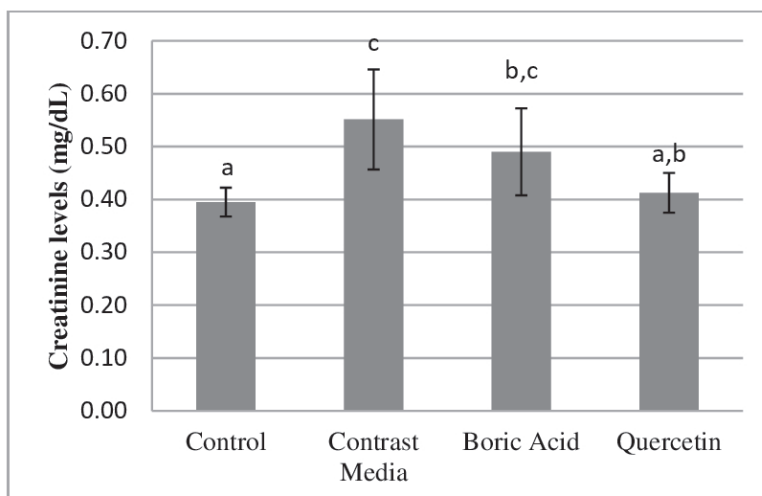
### Biochemical analyses

Serum urea and creatinine levels were significantly increased in the CM group compared to the C group

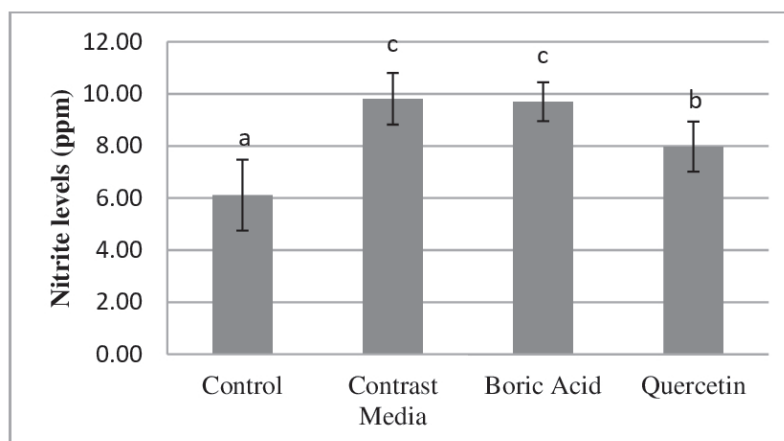
( $P < 0.01$ ). There were no significant differences in the serum urea or creatinine levels in the CMB group compared to the CM group ( $P > 0.05$ ), but there were significant decreases in the CMQ group ( $P < 0.01$ ) (Figure 1 and 2). Serum nitrite and nitrate levels were significantly increased in the CM group compared to the C group ( $P < 0.01$ ). There were no significant differences in serum nitrite or nitrate levels in the CMB group compared to the CM group ( $P > 0.05$ ), but significant decreases were found in the CMQ group ( $P < 0.01$ ) (Figure 3 and 4).



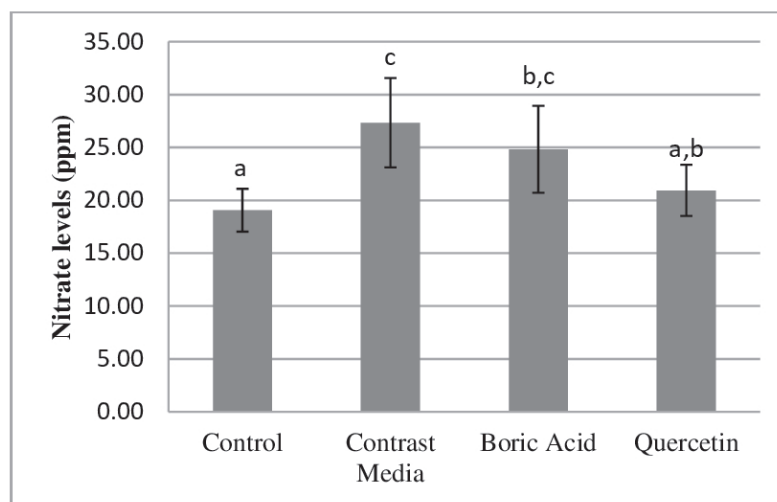
**FIGURE 1** - Changes in serum urea levels among the groups in our study. Statistically insignificant differences are indicated by identical letters, and statistically significant differences are indicated by different letters.  $P < 0.05$  was considered statistically significant.



**FIGURE 2** - Changes in serum creatinine levels among the groups in our study. Statistically insignificant differences are indicated by identical letters, and statistically significant differences are indicated by different letters.  $P < 0.05$  was considered statistically significant.



**FIGURE 3** - Changes in serum nitrite levels among the groups in our study. Statistically insignificant differences are indicated by identical letters, and statistically significant differences are indicated by different letters.  $P < 0.05$  was considered statistically significant.



**FIGURE 4** - Changes in serum nitrate levels among the groups in our study. Statistically insignificant differences are indicated by identical letters, and statistically significant differences are indicated by different letters.  $P < 0.05$  was considered statistically significant.

### Histopathological analyses

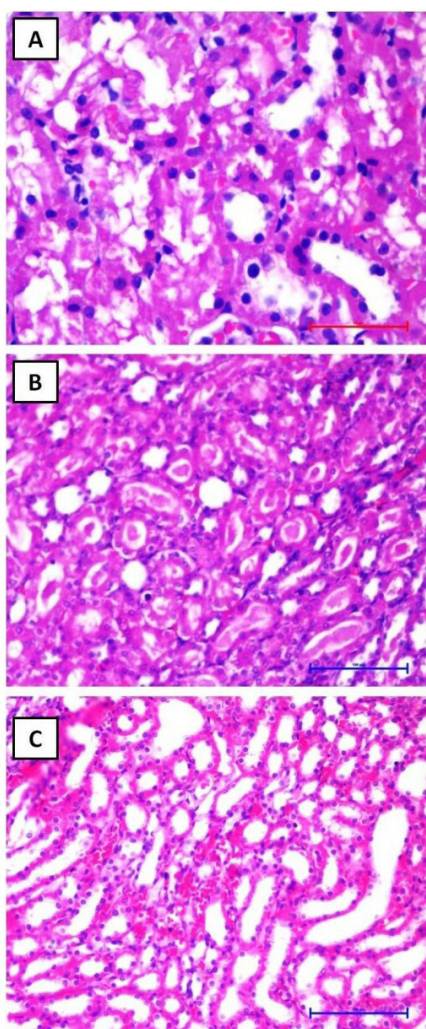
Histopathological changes in the right kidneys were evaluated under a light microscope as described by Yamasowa *et al.* (2005) (Table I and Figure 5). Mild to moderate tubular necrosis was observed in the CM group compared to the C group ( $P < 0.05$ ). Quercetin

administration significantly protected tubules against contrast media-induced kidney damage. Boric acid administration did not show any protective effects on contrast media-induced nephropathy. Additionally, there were no statistically significant differences in medullary congestion or proteinaceous casts between the groups ( $P > 0.05$ ).

**TABLE I** - Pathology Scoring eligible

	Control	Contrast Media	Boric Acid	Quercetin	P
Tubular necrosis	0.75±0.46 <sup>+</sup>	1.5±0.75*	1.14±0.37	0.75±0.46 <sup>+</sup>	<b>0.027</b>
Medullar congestion	1.5±0.19	1.75±0.7	2.14±0.69	1.62±0.91	0.566
Proteinaceous cast	0.5±0.75	1.37±1.30	0.85±1.21	1.37±1.06	0.327

\*compared to controls, <sup>+</sup>compared to contrast media (0:none, 1:mild, 2:moderate, 3:severe), P <0.05 was considered statistically significant.



**FIGURE 5** - (a) Severe tubular necrosis in CM group rats (H&E, 200×). (b) Numerous proteinaceous casts in tubular lumens in CM group rats. The tubules were dilated with numerous proteinaceous casts (H&E, 400×). (c) Medullary congestion and moderate tubular necrosis (H&E, 200×). H&E: hematoxylin-eosin.

## DISCUSSION

In our study, quercetin was shown to improve both biochemical and pathological findings in contrast nephropathy. Boric acid had no significant negative or positive effect on contrast nephropathy.

Nephrotoxicity caused by the use of contrast agents has been reported for approximately 60 years, and contrast nephropathy is one of the most important causes of restrictions on the use of intravascular contrast agents. CMN, which is one of the most common causes of iatrogenic acute renal failure, has significant morbidity and mortality (Wood, 2012; Ali *et al.*, 2018). In general, diabetes mellitus, chronic kidney disease, age, and congestive heart failure are risk factors for the development of CMN. The incidence of nephropathy after contrast media use is directly proportional to the risk factors (Katoh *et al.*, 2019).

Increases in serum creatinine and urea levels, within the first 72 hours following the application of contrast agent, are necessary for the diagnosis of CMN (van der Molen *et al.*, 2018). Toprak *et al.* (2008) showed that, after 72 hours of dehydration, rats lost 30% of their body weight and that diatrizoate (6 ml/kg administered intravenously after dehydration) significantly increased serum creatinine and urea levels compared to those in the control group. In our study, serum urea and creatinine levels were significantly higher in the CM group compared to the C group.

Hazman *et al.* (2018) induced nephrotoxicity with cisplatin and administered different doses of boric acid. There were no significant differences in serum urea or creatinine levels upon treatment with cisplatin alone or 100 mg/kg boric acid. However, serum urea and creatinine levels were increased significantly in the

200 mg/kg boric acid-treated group compared to the cisplatin-treated group. This study showed that high-dose boric acid has an additional nephrotoxic effect. However, the protective effect of decreased apoptosis against nephrotoxicity was significantly higher in the 200 mg/kg boric acid-treated group only. In our study, there were no significant differences in serum urea or creatinine levels between the CM group and the CMB group (administered 200 mg/kg boric acid). There was no protective effect of boric acid against CMN in kidney tissues. In other words, no nephroprotective or nephrotoxicity-enhancing effect of boric acid was observed. Contrary to our work, Cengiz (2018) showed that boric acid administration significantly reduced serum creatinine levels after cyclophosphamide-induced renal damage.

Guss *et al.* (2017) showed that serum urea levels did not decrease but that serum creatinine levels decreased after quercetin was administered to the contrast nephropathy group. In our study, we showed that both serum urea and creatinine levels were decreased. This may be due to the higher dose of quercetin used in our study. Hou *et al.* (2014) showed that the same dose of quercetin as that used in our study significantly decreased serum urea and creatinine levels in nephrotoxicity induced by dichlorvos.

NO has an important role in homeostasis under normotensive and hypertensive conditions in the kidney. Free NO in the plasma is oxidized into nitrite in a few hours and is then quickly converted to nitrate (Butov *et al.*, 2016). Nitrite and nitrate are important indicators of NO in the blood (Rassaf, Feelisch, Kelm, 2004). Renal hypoxia and increased reactive oxygen products induced by high oxidative stress have been shown to play important roles in the pathogenesis of CMN. It has been reported that renal medullary hypoxia and free oxygen radicals cause direct tubular toxicity. It has also been found that contrast agents also produce tubular damage through a direct cytotoxic effect (Seeliger, Persson, 2019). It has been shown that NO and its metabolites, nitrite and nitrate, are increased during hypoxia and high oxidative stress in CMN. It has been suggested that nitrite and nitrate, which have vasodilator effects, are increased to prevent ischemia (Atanda, Olafiranye, 2017; Rassaf *et al.*, 2014; Murillo *et al.*, 2011). In our study, serum

nitrite and nitrate levels were significantly increased in the CM group, as has been reported in the literature. Several studies have shown that antioxidant agents play a protective role against CMN formation by reducing reactive oxygen products (Toprak *et al.*, 2008; Hong *et al.*, 2017; Samadian *et al.*, 2018; Deng *et al.*, 2015). Ince *et al.* (2010) found that a 100 mg/kg dose of boric acid had no effect on NO levels. Similarly, no significant differences in serum nitrite or nitrate levels were found between the CMB group and the CM group in our study. It is known that quercetin both clears free oxygen radicals (antioxidant effect) and inhibits NO production (anti-inflammatory effect) (Aluani *et al.*, 2016; Ebihara *et al.*, 2018). In our study, serum nitrite and nitrate levels were significantly decreased in the CMQ group compared to the CM group.

Contrast media directly effects renal tubular cells. Irregularities in glomerular structures, dilatation of the tubules, and separation and distortions of the tubular epithelium occur after CMN (Yang *et al.*, 2018; Yao *et al.*, 2013). In our study, severe tubular necrosis was observed in the contrast nephropathy group. However, mild histopathological changes in medullary congestion and proteinaceous casts were. Quercetin has been shown to have a pronounced curative effect on tubular necrosis in contrast-induced nephropathy. Boric acid only slightly improved tubular necrosis and proteinaceous casts, but did not have any significant protective effect.

In conclusion, it has been observed that boric acid does not have a protective effect on contrast media-induced nephropathy but does not increase the severity of nephropathy. The dose of boric acid used in this study may have been insufficient, or the application route may not have been effective; hence, more detailed studies are needed. However, quercetin showed protective effects against contrast nephropathy. In conclusion, our study should be supported by advanced experimental and clinical studies.

The authors declare that there are no conflicts of interest. This research did not receive any specific grant from funding agencies in the public, commercial, or not-for-profit sectors.

## REFERENCES

- Ali A, Bhan C, Malik MB, Ahmad MQ, Sami SA. The Prevention and Management of Contrast-induced Acute Kidney Injury: A Mini-review of the Literature. *Cureus*. 2018;10(9):e3284.
- Al-Rasheed NM, Fadda LM, Attia HA, Ali HM, Al-Rasheed NM. Quercetin inhibits sodium nitrite-induced inflammation and apoptosis in different rats organs by suppressing Bax, HIF1-alpha, TGF-beta, Smad-2, and AKT pathways. *J Biochem Mol Toxicol*. 2017;31(5).
- Aluani D, Tzankova V, Yordanov Y, Zhelyazkova A, Georgieva E, Yoncheva K. Quercetin: an overview of biological effects and recent development of drug delivery systems. *Pharmacia*. 2016;63(4):52-60.
- Andreucci M, Faga T, Pisani A, Sabbatini M, Michael A. Acute kidney injury by radiographic contrast media: pathogenesis and prevention. *Biomed Res Int*. 2014;2014:362725. doi: 10.1155/2014/362725.
- Atanda AC, Olafiranye O. Contrast-induced acute kidney injury in interventional cardiology: Emerging evidence and unifying mechanisms of protection by remote ischemic conditioning. *Cardiovasc Revasc Med*. 2017;18(7):549-53.
- Butov DO, Kuzhko M, Butova T, Stepanenko G. Changes in nitric oxide synthase and nitrite and nitrate serum levels in patients with or without multidrug-resistant tuberculosis undergoing the intensive phase of antituberculosis therapy. *Int J Mycobacteriol*. 2016;5(Suppl 1):154-5.
- Cengiz M. Boric acid protects against cyclophosphamide-induced oxidative stress and renal damage in rats. *Cell Mol Biol (Noisy-le-grand)*. 2018;64(12):11-4.
- Chen X, Zhao Y, Geng S, Miron RJ, Zhang Q, Wu C, et al. In vivo experimental study on bone regeneration in critical bone defects using PIB nanogels/boron-containing mesoporous bioactive glass composite scaffold. *Int J Nanomed*. 2015;10:839-46.
- Demirci S, Dogan A, Aydin S, Dulger EC, Sahin F. Boron promotes streptozotocin-induced diabetic wound healing: roles in cell proliferation and migration, growth factor expression, and inflammation. *Mol Cell Biochem*. 2016;417(1-2):119-33.
- Deng J, Wu G, Yang C, Li Y, Jing Q, Han Y. Rosuvastatin attenuates contrast-induced nephropathy through modulation of nitric oxide, inflammatory responses, oxidative stress and apoptosis in diabetic male rats. *J Transl Med*. 2015;13:53.
- Ebihara N, Takahashi K, Takemura H, Akanuma Y, Asano K, Sunagawa M. Suppressive effect of quercetin on nitric oxide production from nasal epithelial cells *in vitro*. *Evid Based Complement Alternat Med*. 2018;2018:6097625. doi: 10.1155/2018/6097625. eCollection 2018.
- Feng S, Zhang H, Yan T, Huang D, Zhi C, Nakanishi H, et al. Folate-conjugated boron nitride nanospheres for targeted delivery of anticancer drugs. *Int J Nanomed*. 2016;11:4573-82.
- Gomes IB, Porto ML, Santos MC, Campagnaro BP, Pereira TM, Meyrelles SS, et al. Renoprotective, anti-oxidative and anti-apoptotic effects of oral low-dose quercetin in the C57BL/6J model of diabetic nephropathy. *Lipids Health Dis*. 2014;13:184.
- Guss KL, Pavanni S, Prati B, Dazzi L, de Oliveira JP, Nogueira BV, et al. Ultrasound-assisted extraction of Achyrocline satureioides prevents contrast-induced nephropathy in mice. *Ultrason Sonochem*. 2017;37:368-74.
- Harwood M, Danielewska-Nikiel B, Borzelleca JF, Flamm GW, Williams GM, Lines TC. A critical review of the data related to the safety of quercetin and lack of evidence of *in vivo* toxicity, including lack of genotoxic/carcinogenic properties. *Food Chem Toxicol*. 2007;45:2179-205.
- Hazman Ö, Bozkurt MF, Fidan AF, Uysal FE, Çelik S. The effect of boric acid and borax on oxidative stress, inflammation, ER stress and apoptosis in cisplatin toxication and nephrotoxicity developing as a result of toxication. *Inflammation*. 2018;41(3):1032-48.
- Hocine A, Defrance P, Lalmand J, Delcour C, Biston P, Piagnerelli M. Predictive value of the RIFLE urine output criteria on contrast-induced nephropathy in critically ill patients. *BMC Nephrol*. 2016;17:36.
- Hong YA, Bae SY, Ahn SY, Kim J, Kwon YJ, Jung WY, et al. Resveratrol Ameliorates Contrast Induced Nephropathy Through the Activation of SIRT1-PGC-1 $\alpha$ -Foxo1 Signaling in Mice. *Kidney Blood Press Res*. 2017;42(4):641-53.
- Hou Y, Zeng Y, Li S, Qi L, Xu W, Wang H, et al. Effect of quercetin against dichlorvos induced nephrotoxicity in rats. *Exp Toxicol Pathol*. 2014;66:211-8.
- Ince S, Kucukkurt I, Cigerci IH, Fatih Fidan A, Eryavuz A. The effects of dietary boric acid and borax supplementation on lipid peroxidation, antioxidant activity, and DNA damage in rats. *J Trace Elem Med Biol*. 2010;24(3):161-4.
- Katoh H, Nozue T, Horie K, Sozu T, Inoue N, Michishita I. RenalGuard system to prevent contrast-induced acute kidney injury in Japanese patients with renal dysfunction; RESPECT KIDNEY study. *Cardiovasc Interv Ther*. 2019;34(2):105-12.
- Kiss A, Juhasz L, Seprenyi G, Kupai K, Kaszaki J, Vegh A. The role of nitric oxide, superoxide and peroxynitrite in the anti-arrhythmic effects of preconditioning and peroxynitrite infusion in anaesthetized dogs. *Br J Pharmacol*. 2010;160(5):1263-72.

- Kovacs M, Kiss A, Gonczi M, Miskolczi G, Seprényi G, Kaszaki J, et al. Effect of sodium nitrite on ischaemia and reperfusion-induced arrhythmias in anaesthetized dogs: is protein S-nitrosylation involved? *PloS one*. 2015;10(4):e0122243.
- Li X, Zheng T, Sang S, Lv L. Quercetin inhibits advanced glycation end product formation by trapping methylglyoxal and glyoxal. *J Agric Food Chem*. 2014;62(50):12152-8.
- Mahesh T, Menon VP. Quercetin alleviates oxidative stress in streptozotocin-induced diabetic rats. *Phytother Res*. 2004;18(2):123-7.
- Murillo D, Kamga C, Mo L, Shiva S. Nitrite as a mediator of ischemic preconditioning and cytoprotection. *Nitric Oxide*. 2011;25(2):70-80.
- Pazirandeh A, Jameie B, Zargar M. Determination of boron distribution in rat's brain, kidney and liver. *Appl Radiat Isot*. 2009;67(7-8 Suppl):S369-73.
- Pistolessi V, Regolisti G, Morabito S, Gandolfini I, Corrado S, Piotti G et al. Contrast medium induced acute kidney injury: a narrative review. *J Nephrol*. 2018;31(6):797-812.
- Rassaf T, Feelisch M, Kelm M. Circulating NO pool: assessment of nitrite and nitroso species in blood and tissues. *Free Radic Biol Med*. 2004;36(4):413-22.
- Rassaf T, Totzeck M, Hendgen-Cotta UB, Shiva S, Heusch G, Kelm M. Circulating nitrite contributes to cardioprotection by remote ischemic preconditioning. *Circ Res*. 2014;114(10):1601-10.
- Sabuncuoglu BT, Kocaturk PA, Yaman O, Kavas GO, Tekelioglu M. Effects of subacute boric acid administration on rat kidney tissue. *Clin Toxicol (Phila)*. 2006;44(3):249-53.
- Samadian F, Dalili N, Mahmoudieh L, Ziaei S. Contrast-induced Nephropathy: Essentials and Concerns. *Iran J Kidney Dis*. 2018;12(3):135-41.
- Seeliger E, Persson PB. Kidney damage by iodinated contrast media. *Acta Physiol (Oxf)*. 2019 Jan 28:e13259.
- Shoskes DA. Effect of bioflavonoids quercetin and curcumin on ischemic renal injury: a new class of renoprotective agents. *Transplantation*. 1998;66(2):147-52.
- Toprak O, Cirit M, Tanrisev M, Yazici C, Canoz O, Sipahioglu M et al. Preventive effect of nebivolol on contrast-induced nephropathy in rats. *Nephrol Dial Transplant*. 2008;23(3):853-9.
- van der Molen AJ, Reimer P, Dekkers IA, Bongartz G, Bellin MF, Bertolotto M et al. Post-contrast acute kidney injury - Part I: Definition, clinical features, incidence, role of contrast medium and risk factors: Recommendations for updated ESUR Contrast Medium Safety Committee guidelines. *Eur Radiol*. 2018;28(7):2845-55.
- Wood SP. Contrast-induced nephropathy in critical care. *Crit Care Nurse*. 2012;32(6):15-23.
- Yamasawa H, Shimizu S, Inoue T, Takaoka M, Matsumura Y. Endothelial nitric oxide contributes to the renal protective effects of ischemic preconditioning. *J Pharmacol Exp Ther*. 2005;312(1):153-9.
- Yang JS, Peng YR, Tsai SC, Tyan YS, Lu CC, Chiu HY, et al. The molecular mechanism of contrast-induced nephropathy (CIN) and its link to in vitro studies on iodinated contrast media (CM). *BioMedicine*. 2018;8(1):1.
- Yao L, Kolluru GK, Kevil CG, Zhang WW. Intravascular radiocontrast iodixanol increases permeability of proximal tubule epithelium: a possible mechanism of contrast-induced nephropathy. *Vascular Endovascular Surgery*. 2013;47(8):632-8.

Received for publication on 11<sup>th</sup> October 2018

Accepted for publication on 12<sup>th</sup> July 2019