






Auditory perception and oral language in brainstem auditory implant users: a scoping review

Percepção auditiva e desenvolvimento de linguagem oral após cirurgia de implante auditivo de tronco encefálico: uma revisão de escopo

Vanessa Luisa Destro Fidêncio¹ , Ingrid Moura de Jesus Pereira¹ , Victoria Maia Rodrigues¹ ,
Francisca Samara Freitas Oliveira¹ , Maria Renata José² 

ABSTRACT

Purpose: This scope review aims to map current evidence in relation to auditory perception of speech and oral language development in users of Auditory Brainstem Implant - ABI, to answer the following guiding question: “what do we know about the ability of auditory perception of speech and oral language in auditory brainstem implants users?” **Research strategy:** The search was performed in the BVSalud, PubMed and SciELO databases and for gray literature the source of information Google Academic, using the descriptors: auditory brainstem implantation, language, hearing and auditory perception. **Selection criteria:** Studies were included in which tests were applied to assess auditory perception or to verify oral language development in children and/or adults using ABI. Articles published in the last five years were included and secondary studies were excluded. **Results:** 1767 articles were found in the databases and source of information, of which 27 studies were included. It was observed that most users of ABI become able to perceive some environmental sounds, some become able to recognize words, but few reach the recognition of sentences. **Conclusion:** Most ABI users do not advance towards the open set auditory recognition skill and there is unanimity in recommending visual communication methods for these individuals.

Keywords: Auditory Braistem Implant; Hearing; Auditory Perception; Language; Neurofibromatosis 2

RESUMO

Objetivo: mapear as evidências atuais em relação à percepção auditiva da fala e desenvolvimento de linguagem oral em usuários de implante auditivo de tronco encefálico (*auditory brainstem implant* – ABI), para responder à seguinte questão norteadora: “O que se sabe sobre a habilidade de percepção auditiva da fala e de linguagem oral em indivíduos usuários de implante auditivo de tronco encefálico?” **Estratégia de pesquisa:** a busca foi realizada nas bases de dados BVSalud, PubMed e SciELO e, para literatura cinzenta, utilizou-se a fonte de informação *Google Acadêmico*, por meio dos descritores: implante auditivo de tronco encefálico (*auditory brainstem implantation*), linguagem (*language*), audição (*hearing*) e percepção auditiva (*auditory perception*). **Crterios de seleção:** foram incluídos estudos nos quais foram aplicados testes para avaliação da percepção auditiva ou para verificar desenvolvimento de linguagem oral em crianças e/ou adultos usuários de ABI. Foram incluídos artigos publicados nos últimos cinco anos e excluídos estudos secundários. **Resultados:** Foram encontrados 1767 artigos nas bases de dados e fonte de informação, dos quais, 27 foram incluídos na revisão. Observou-se que a maioria dos usuários de ABI torna-se capaz de perceber alguns sons ambientais, alguns tornam-se capazes de reconhecer vocábulos, porém, poucos atingem o reconhecimento de frases. **Conclusão:** a maioria dos usuários de ABI não avança para a habilidade de reconhecimento auditivo em conjunto aberto e há unanimidade na recomendação de métodos de comunicação visual para esses indivíduos.

Palavras-chave: Implante Auditivo de Tronco Encefálico; Audição; Percepção Auditiva; Linguagem; Neurofibromatose 2

Study carried out at Centro Universitário Planalto do Distrito Federal – UNIPLAN - Brasília (DF), Brasil.

¹Centro Universitário Planalto do Distrito Federal – UNIPLAN - Brasília (DF), Brasil.

²Universidade Tuiuti do Paraná – UTP - Curitiba (PR), Brasil.

Conflict of interests: No.

Authors' contribution: VLDF foi responsável pela idealização do trabalho e orientação em todas as etapas, revisão crítica do manuscrito e aprovação da versão final; IMJP foi responsável pela elaboração do projeto, coleta e tabulação dos dados e escrita do manuscrito; VMR e FSFO participaram ativamente da coleta e tabulação de dados e escrita da versão inicial do manuscrito; MRJ foi responsável pela revisão crítica do manuscrito e aprovação da versão final.

Funding: None.

Corresponding author: Vanessa Luisa Destro Fidêncio. E-mail: vanessa.destrof@gmail.com

Received: September 08, 2021; **Accepted:** September 30, 2022

INTRODUCTION

Hearing aids are effective in the treatment of hearing impairment⁽¹⁾. However, some individuals with severe and/or profound sensorineural hearing loss do not benefit from their use. They need to resort to other methods, such as cochlear implant (CI), which is a surgically implanted electronic device⁽²⁾ that replaces the hair cell functions in the inner ear by directly stimulating the auditory nerve.

Furthermore, there are cases in which CI is not indicated, and the need for an auditory brainstem implant (ABI) can be evaluated. Auditory brainstem implants were developed to restore hearing⁽²⁾: in individuals diagnosed with neurofibromatosis type 2 (NF-2) for manifesting bilateral vestibular *schwannomas*; and individuals with cochlear ossification, but with the integrity of the VIII cranial pair (vestibulocochlear nerve), absence or malformation of the auditory nerve⁽³⁻⁵⁾, and trauma injuries or auditory neuropathy spectrum disorder (ANS⁽⁴⁾).

The first ABI model was developed with only a single-channel electrode in California. It was used from 1979 to 1992 with inconsistent results^(1,6). Even though the first surgery was performed in 1979, the approval for clinical use by the *Food and Drug Administration* (FDA) in the United States occurred in 2000. The devices arrived in Brazil only in 2005^(4,6).

For outcomes after ABI, one must consider, among other factors, the age of implantation, presence of other comorbidities, family expectation and support, and hearing and language rehabilitation⁽⁷⁾. The patient must be aware that hearing will not be fully restored⁽⁶⁾.

Knowing the evolution of the hearing and oral language abilities of individuals implanted with ABI is essential to define a good therapeutic plan. Thus, the family and the individual must be adequately oriented regarding the case's prognosis. Thus, due to the inconclusive results of studies with ABI users regarding the improvement of speech perception and oral language development (in children), there is a need to search the literature and compile the data found.

PURPOSE

According to the surveyed literature, there were questions about the benefits obtained regarding auditory speech perception and oral language development in ABI users. Moreover, there was a need for a scoping review to map the observed limitations, methodological flaws, and gaps in scientific knowledge in studies on this topic. Therefore, this scoping review aimed to map the research on this topic to answer the following guiding question: "What do we know about auditory speech perception and oral language skills in individuals using auditory brainstem implants?"

RESEARCH STRATEGY

Information sources and search strategy

Descriptors in Portuguese were selected from the Descriptors in Health Sciences (DeCS). Descriptors in English were selected from the *Medical Subject Headings* (MeSH). The search was

conducted in July 2020 and comprised the following databases: Latin American and Caribbean Literature in Health Sciences (LILACS); *Public Medicine Library* (PubMed); and *Scientific Electronic Library Online* (SciELO). Grey literature included the *Google Scholar* using the following combinations of descriptors: (1) implante auditivo de tronco encefálico AND linguagem; (2) auditory brainstem implant AND language; (3) implante auditivo de tronco encefálico AND audição AND percepção auditiva; and (4) auditory brainstem implant AND hearing AND auditory perception.

SELECTION CRITERIA

We used the strategy with the PICOS⁽⁸⁾ anagram to construct the studies' eligibility criteria and considered:

- Population: studies in which the sample comprised individuals with profound bilateral sensorineural hearing loss;
- Intervention: studies with ABI users;
- Comparison: studies comparing ABI users with individuals using cochlear implants;
- Outcome: studies analyzing auditory perception and oral language development in ABI users with tests and/or questionnaires to evaluate these skills;
- Types of study: interventional or observational studies; articles available in full in open access and/or by *Virtual Private Network* (VPN) in Portuguese and/or English languages; and studies published since 2015.

We excluded literature review studies, those conducted only with individuals using devices other than the ABI, and studies dealing only with the ABI device but without explaining its users' results in auditory perception and/or language tests.

Selecting evidence sources

Three reviewers carried out the selection phases independently. Disagreements regarding which studies to include were resolved by a fourth reviewer with experience in the hearing (re)habilitation area.

First, the studies were pre-selected by titles and had their abstracts read to verify whether they met this review's proposed objective. Then, the studies were fully read.

DATA ANALYSIS

Mapping and data collection process

We developed a table in an Excel file to insert the data of interest from the included studies for evidence mapping. Three reviewers collected the following information from the studies selected for inclusion: casuistry (number of participants, age group, gender, and diagnosis), tests used, main results, and conclusion. Complementary data included: a) type of research, b) publication year, c) nationality of the research, and d) published language⁽⁹⁾. This study does not include an evaluation of the

methodological quality and the classification of the level of evidence of the included studies.

RESULTS

Selecting evidence sources

We found 1,767 articles in the databases and the information source. Eighty-one studies were selected by title. After reading the abstracts, 35 were selected to be read in full. Finally, 27 studies⁽¹⁰⁻³⁶⁾ met the eligibility criteria and were included in this review (Figure 1).

Characteristics of the evidence sources

Considering the 27 studies included in this review, most (n=8) were conducted in the United States (USA), followed by Turkey (n=4). There are only two^(29,36) Brazilian-authored studies. They are from the same research team of a center that is currently one of the few performing ABI placement surgery in Brazil via the Unified Health System (SUS). This fact justifies the lack of research in the area at a national level.

On average, the selected studies included 13 participants, ranging from 1 to 60 participants, with age groups from 1 to 76 years old, and comprised male and female participants.

Individual results from evidence sources

Table 1 shows the main data from the included studies.

DISCUSSION

ABI in children

We evaluated 251 ABI-using children. There were 97.60% (n=245) with pre-lingual deafness and 2.40% (n=6) with post-lingual deafness.

A total of 15.93% (n=40) of the evaluated children had associated comorbidities: 17.50% (n=7/40) with Charge syndrome^(14,22,24,25); 2.50% (n=1/40) with Down syndrome⁽³⁴⁾; 5.0% (n=2/40) with Goldenhar syndrome^(13,25); 25% (n=10/40) with mental retardation, cognitive and/or developmental delays^(10,23,25,36); 2.50% (n=1/40) with autistic spectrum disorder (ASD)⁽²⁵⁾; 12.50% (n=5/40) with attention deficit hyperactivity

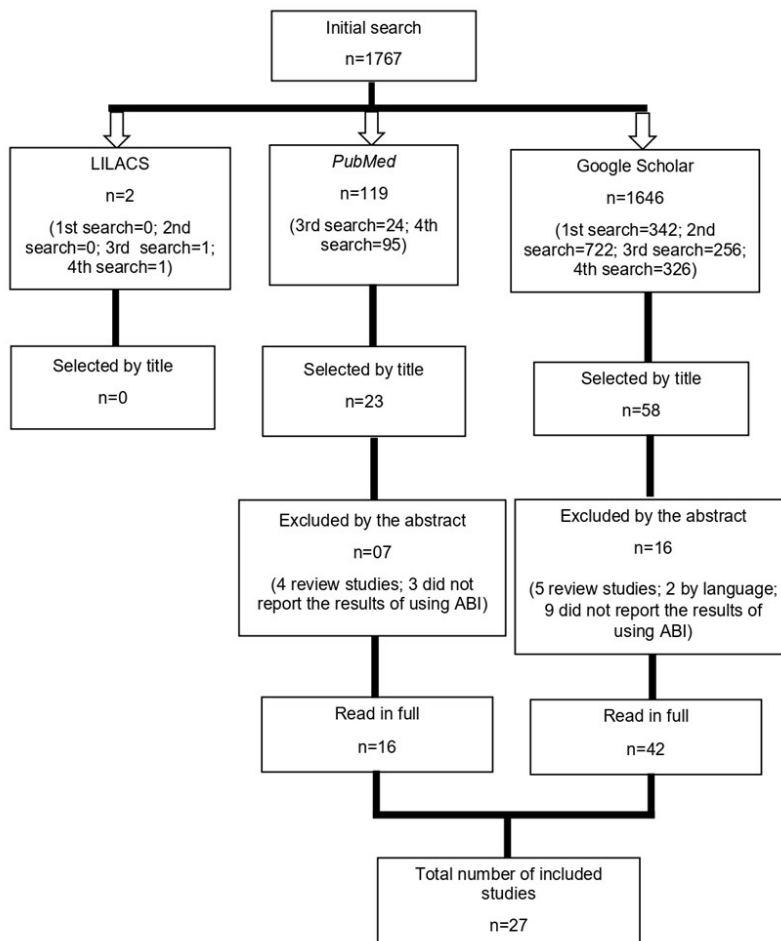


Figure 1. Article selection flowchart
Subtitle: ABI = auditory brainstem implantation

Table 1. Key data from the studies included in the review (n= 27)

Year	First author	Country	n	Age (years)	Gender	Etiology	Tests applied	Main Results	Conclusion
2015	Yücel et al. ⁽¹⁰⁾	Turkey	36	3 to 12	F/M	Aplasia and/or hypoplasia of the cochlea or auditory nerve.	<i>Categories of Auditory Perception – CAP</i> <i>Speech Intelligibility Rating – SIR</i> <i>Functioning After Pediatric Cochlear Implantation – FAPCI</i> <i>Children's Auditory Perception Skills Test in Turkish – CIAT</i>	Most achieved auditory recognition of vocabulary words in a closed set. Twelve children achieved sentence recognition in an open set. Three children talk on the phone. They all have poor vocabulary and require visual communication.	Main ABI disadvantage: speech intelligibility.
2015	Puram et al. ⁽¹¹⁾	USA	5	20 to 66	F/M	NF-2	Behavioral hearing assessment tests	Two participants achieved auditory recognition of open-set vocabulary words.	All patients achieved minimal sound awareness, with most patients achieving reasonable hearing thresholds over a wide range of frequencies if the device is worn daily.
2016	Lundin et al. ⁽¹²⁾	Sweden	11	23 to 73	F/M	NF-2	<i>Categories of Auditory Perception – CAP</i>	Eight adults (73%) used the ABI. Most could discriminate speech from music but could not distinguish between two voices or similar sounds. One child was able to recognize familiar voices.	Auditory brainstem implant is a valuable treatment in patients with NF-2 and children with congenital malformations of the inner ear and cochlear ossification.
			0	6 to 8	M	S. of Goldenhar Cochlear ossification			
2016	Sennaroğlu et al. ⁽¹³⁾	Turkey	60	1 to 5	F/M	Hypoplasia of the cochlea and/or auditory nerve.	<i>Categories of Auditory Perception – CAP</i> <i>Speech Intelligibility Rating – SIR</i> <i>Functioning After Pediatric Cochlear Implantation – FAPCI</i>	Children with more than one year of ABI can achieve simple sentence recognition in an open set. Language scores did not reach those of a CI user. Sign language use is required.	Auditory brainstem implant is an acceptable and effective treatment modality for the pediatric population with inner ear malformations.
2016	Lundin et al. ⁽¹⁴⁾	Sweden	4	3 to 5	F/M	Cochlear ossification Cochlear aplasia	<i>Categories of Auditory Perception – CAP</i>	Two children achieved discrimination of Ling sounds. One became responsive to environmental sounds after three months. The first 12 months included vague reactions.	Three out of four children benefited from ABI.
2016	Puram et al. ⁽¹⁵⁾	USA	4	Average of 3.	F/M	Cochlear and/or auditory nerve aplasia or hypoplasia.		All patients achieved sound detection, and some demonstrated vocalizations and imitation.	The patients achieved some detection with the ABI.
2016	Thong et al. ⁽¹⁶⁾	China	8	18 to 51	F/M	NF-2	<i>Infant-Toddler Meaningful Auditory Integration Scale – IT-MAIS</i>	Patients achieved closed-set vocabulary recognition. No patients achieved open-set recognition. Patients reported that they could distinguish everyday sounds (phone vs. television).	Environmental sound awareness and improved lip-reading were the main benefits observed in this study.

Subtitle: n = number of participants; F = female; M = male; USA = United States of America; NF-2 = Neurofibromatosis type 2; ABI = auditory brainstem implant; CI = cochlear implant; S = syndrome

Table 1. Continued...

Year	First author	Country	n	Age (years)	Gender	Etiology	Tests applied	Main Results	Conclusion
2016	Ramsden et al. ⁽¹⁷⁾	England	49	18 to 71	F/M	NF-2	<i>Three alternative forced choice syllable test (3AFC)</i> <i>Arthur Boothroyd (AB) monosyllabic words test</i> <i>City University of New York (CUNY) sentences test</i>	Twenty-nine patients became full-time users. Twelve became non-users. 51% achieved environmental sound discrimination. 22% achieved phoneme discrimination with ABI alone. 45% discriminated using lip-reading support.	Most NF-2 patients implanted with ABI find the device a useful aid coupled with lipreading. Almost a third of patients may end up as non-users.
2017	Wilkinson et al. ⁽¹⁸⁾	USA	4	2 to 5	F/M	Hypoplasia or aplasia of the cochlea or auditory nerve Cochlear ossification	<i>Infant-Toddler Meaningful Auditory Integration Scale – IT-MAIS</i> <i>Meaningful Auditory Integration Scale – MAIS</i>	None of the children could distinguish speech from non-speech sounds or discriminate between two speakers. The authors recommend using visual communication.	The results indicate that ABI can be feasible if performed by a competent multidisciplinary team.
2017	Goyal et al. ⁽¹⁹⁾	India	12	10 or more	F/M	Aplasia of the cochlea and/or auditory nerve	<i>Categories of Auditory Perception – CAP</i> <i>Speech Intelligibility Rating – SIR</i>	Few ABI patients could achieve recognition in an open set.	Complications that hinder the placement of ABI electrodes can adversely affect postoperative subjective outcomes.
2017	Al-Momani et al. ⁽²⁰⁾	Saudi Arabia	1	4	F	Cochlear aplasia	Open and closed set word recognition (does not specify test).	The results revealed good sound detection for test stimuli and environmental sounds. During the first two years, the child reached thresholds at about 30 dBHL for frequencies from 250 to 8000 Hz. The child could issue two sentences that helped her communicate more effectively.	The ABI performance of most patients is equivalent to the single-channel CI performance. At around 10%, the ABI performance is equivalent to the 2-3 channel CI performance.
2017	Jung et al. ⁽²¹⁾	Korea	4 11	20 to 56 1 to 18	F/M	Cochlear ossification Auditory nerve aplasia or hypoplasia.	<i>Infant-Toddler Meaningful Auditory Integration Scale – IT-MAIS</i> <i>Meaningful Use of Speech Scale – MUSS</i> <i>Categories of Auditory Perception – CAP</i>	All but two patients improved hearing function at the last follow-up/visit. Ten of the 11 children demonstrated crying or increased attention. One of the four adult patients could achieve speech discrimination, mainly with lip-reading assistance.	Auditory brainstem implants have shown favorable functional outcomes and long-term safety in non-tumor deaf patients.
2017	Teagle et al. ⁽²²⁾	USA	5	1.6 to 5	F/M	Auditory nerve aplasia	<i>Categories of Auditory Perception – CAP</i> <i>Early Speech Perception Test – ESP</i> Visual reinforcement audiometry (VRA) and/or conditioned audiometry	Detection time ranged from two weeks to 18 months. They did not score on the IT-MAIS. No child evolved to open set recognition. They did not evolve language, and visual communication was required.	Auditory brainstem implants are safe in children without NF-2, but the benefits appear slowly and include sound perception and suprasegmental aspects.

Subtitle: n = number of participants; F = female; M = male; USA = United States of America; NF-2 = Neurofibromatosis type 2; ABI = auditory brainstem implant; CI = cochlear implant; S = syndrome

Table 1. Continued...

Year	First author	Country	n	Age (years)	Gender	Etiology	Tests applied	Main Results	Conclusion
2018	Sung et al. ⁽²³⁾	China	11	1.6 to 3.7	F/M	Hypoplasia of the cochlea and/or auditory nerve.	<i>Cantonese Basic Speech Perception Test</i> – CBSPT	Five children achieved closed-set vocabulary recognition. Three children failed the tests, and the authors recommend the use of visual communication.	Encouraging results of vocalization development were found, especially with ABI's continued use.
2018	Asfour et al. ⁽²⁴⁾	USA	12	1.8 to 17	F/M	Auditory nerve hypoplasia	<i>Glendonal Auditory Integration Scale</i> – GASP <i>Infant-Toddler Meaningful Auditory Integration Scale</i> – IT-MAIS <i>Early Speech Perception Test</i> – ESP	Eleven of the 12 patients achieved auditory sound awareness. Some patients achieved about 50% speech perception in an open set.	Auditory brainstem implants are good options for patients who are ineligible or fail CI. Results show that despite varying degrees of performance, the ratings were positive.
2018	Eisenberg et al. ⁽²⁵⁾	USA	10	2 to 5	F/M	Aplasia and/or hypoplasia of the cochlea and/or auditory nerve	<i>Infant-Toddler Meaningful Auditory Integration Scale</i> – IT-MAIS <i>Meaningful Auditory Integration Scale</i> – MAIS <i>Early Speech Perception Test</i> – ESP Visual reinforcement audiometry (VRA) and/or conditioned audiometry	The children demonstrated varying levels of perception in a closed set. One child could identify 100% of sentences in a closed set after two years with the ABI and 80% in an open set after three years. All children began producing basic word patterns within one to two years after the ABI.	Results indicate that spoken communication skills take time to develop and that visual communication remains essential for post-ABI intervention.
2018	Friedmann et al. ⁽²⁶⁾	USA	4	5 to 9	F/M	Auditory nerve aplasia or hepatoplasia	<i>Glendonal Auditory Integration Scale</i> – GASP	All four children achieved sound detection between 20-40 dB. One of the children could detect Ling's sounds 100% of the time and discriminate 80% of the time. Three of the four used sign language.	There was a continuous improvement in CI performance over time, even though no benefit was evident before the ABI decision.
2018	Peng et al. ⁽²⁷⁾	USA	10	22 to 66	F/M	NF-2	<i>Iowa tests of vowel and consonant recognition</i> <i>Northwestern University Children's Perception of Speech</i> (NU-CHIPS) <i>City University of New York (CUNY) sentences</i>	In most patients, the CI performance in the first few years after implantation exceeded the ABI performance in the first few years after implantation. However, four patients showed a reduction in CI performance, and only one was confirmed to have a functional CI.	The study concluded that ABI remains the primary method of surgical hearing rehabilitation in patients with NF-2.

Subtitle: n = number of participants; F = female; M = male; USA = United States of America; NF-2 = Neurofibromatosis type 2; ABI = auditory brainstem implant; CI = cochlear implant; S = syndrome

Table 1. Continued...

Year	First author	Country	n	Age (years)	Gender	Etiology	Tests applied	Main Results	Conclusion
2018	Malerbi et al. ⁽²⁸⁾	Brazil	10	2 to 18	F/M	Meningitis	Speech perception tests (speakerphone) using vowels, words, and sentences.	Eight patients (80%) improved tonal audiometry and word and vowel perception tests after a mean follow-up of 3.3 years. Two patients recognized up to 40% of closed sentences without lipreading. Two patients showed no auditory responses.	Auditory brainstem implants improved hearing performance in tonal audiometry and speech perception tests in cases of post-meningitis hearing loss. In this study, although only 25% of the patients could identify closed sentences, all eight hearing-responsive patients used the ABI daily for more than eight hours a day and reported benefits in daily communication.
2019	Raghunandhan et al. ⁽²⁹⁾	India	24	Average of 4.1	F/M	Auditory nerve aplasia	<i>Categories of Auditory Perception</i> – CAP <i>Speech Intelligibility Rating</i> – SIR	All candidates showed gradual improvement in audiological and verbal scores after the ABI.	Variants during surgery can hinder the bonding of ABI electrodes. However, all implants showed promising results.
2019	Faes and Gillis ⁽³⁰⁾	Belgium	2	6 to 12		Auditory nerve agenesis	<i>Categories of Auditory Perception</i> – CAP Recordings with parents.	One year of ABI use until the first word appears. Two years after the ABI, the average hearing thresholds had improved to 37 dBHL. However, the two children were using sign language.	Results show that children with ABI still have lagging oral language development compared to same-age children with CI.
2019	Faes and Gillis ⁽³¹⁾	Belgium	2	3 and 4	F	Auditory nerve agenesis	Recordings with parents.	After one year of use, the first child reached the vocabulary that the second child had at the beginning of the study. They both use sign language. Vocalizations predominate at 12 months, babbling at 24 months, and words at 36 months.	The study showed that the improvement in speech perception after ABI results in oral language production combined with sign language use.
2019	van der Straaten et al. ⁽³²⁾	Netherlands	10	1.4 to 6.2	F/M	Cochlear and/or auditory nerve hypoplasia.	<i>Infant-Toddler Meaningful Auditory Integration Scale</i> – IT-MAIS <i>Meaningful Use of Speech Scale</i> – MUSS <i>Categories of Auditory Perception</i> – CAP <i>Speech Intelligibility Rating</i> – SiR	Seven children completed the evaluations. After one year, the children could recognize sounds, respond to speech, and use vocalizations to attract attention. Poorly evolved oral language compared to the development of CI children with other comorbidities.	Children with ABIs can develop receptive and expressive language skills comparable to those with CIs with additional disabilities.

Subtitle: n = number of participants; F = female; M = male; USA = United States of America; NF-2 = Neurofibromatosis type 2; ABI = auditory brainstem implant; CI = cochlear implant; S = syndrome

Table 1. Continued...

Year	First author	Country	n	Age (years)	Gender	Etiology	Tests applied	Main Results	Conclusion
2020	Rajeswaran e Kameswaran ⁽³³⁾	India	10	1.6 to 18	F/M	Cochlear aplasia, auditory nerve hypoplasia, and Michel's aplasia.	<i>Meaningful Auditory Integration Scale – MAIS</i> <i>Meaningful Use of Speech Scale – MUSS</i> <i>Speech Intelligibility Rating – SiR</i> <i>Categories of Auditory Perception – CAP</i>	After 12 months, nine children detected Ling sounds and recognized /a/, /i/, and /u/.	The provision and use of ABI are safe and allow for significant auditory development in children without NF-2 who are not candidates for CI.
2020	Batuk et al. ⁽³⁴⁾	Turkey	12	Average from 2.5 to 7	F/M	Cochlear nerve aplasia; Cochlear ossification;	<i>Meaningful Auditory Integration Scale – MAIS</i> <i>Categories of Auditory Perception – CAP</i> <i>Speech Intelligibility Rating – SIR</i> <i>Children's Auditory Perception Skills Test in Turkish – CIAT</i>	The MAIS test scores improved significantly from unilateral CI to bimodal stimulation (with the ABI). Children obtained better scores in pattern perception, word recognition, and speech intelligibility with ABI and CI combined.	Children with inner ear malformation performed better with CI and contralateral ABI.
2020	Aslan et al. ⁽³⁵⁾	Turkey	30	7 to 9	F/M	Aplasia and/or hypoplasia of the cochlea and/or auditory nerve	<i>Categories of Auditory Performance—II (CAP II)</i> <i>The Auditory Integration Scale (MAIS)</i> <i>Children's Auditory Perception Test Battery</i> <i>Test of Early Language Development—3 (TELD-3)</i> <i>Test of Early Language Development and Speech Intelligibility Rating (SIR)</i>	All acquired basic auditory skills, such as environmental sound detection and name recognition. The group that implanted earlier could recognize familiar phrases, while the other group could only recognize familiar sounds after five years of use. Those who implanted earlier can have an understandable language if the listener pays close attention and does orofacial reading, while for late implanters, visual communication would be necessary.	Auditory brainstem implants are feasible for providing auditory sensations in children with cochlear anomalies. Surgery under three years of age is associated with improved auditory perception and language development compared to older users.
2020	Fernandes et al. ⁽³⁶⁾	Brazil	12	2 to 11	F/M	Cochlear aplasia and cochlear ossification.	<i>Infant-Toddler Meaningful Auditory Integration Scale – IT-MAIS</i> <i>Meaningful Auditory Integration Scale – MAIS</i> <i>Meaningful Use of Speech Scale – MUSS</i>	In the first month of using the ABI, 33% of the children responded positively. Four children in the first month detected environmental sounds. In the third month, five children (41%) showed auditory responses and answered names with visual support.	Pediatric patients show a slow progressive development of auditory and language skills after ABI activation.

Subtitle: n = number of participants; F = female; M = male; USA = United States of America; NF-2 = Neurofibromatosis type 2; ABI = *auditory brainstem implant*; CI = cochlear implant; S = syndrome

disorder (ADHD)⁽¹⁰⁾; and 37.50% (n=15/40) with unspecified comorbidities^(10,19,22).

Regarding the anatomical changes presented by the pediatric population, 28.68% (n=72/251) had unspecified changes, 13.94% (n=35/251) had auditory nerve agenesis, and 13.94% (n=35/251) had cochlear agenesis. Then, we observed: auditory nerve hypoplasia in 13.14% (n=33/251); cochlear hypoplasia in 13.14% (n=33/251); Michel aplasia in 2.78% (n=7/251); and cochlear ossification in 1.59% (n=4/251).

In the studies conducted with the pediatric population (n= 23), the most commonly used protocols for assessing listening and language skills were: *Categories of Auditory Perception (CAP)*^(10,12,13,19,21,22,29,30,32-34); *Speech Intelligibility Rating (SIR)*^(10,13,19,29,32-35); *Infant-Toddler Meaningful Auditory Integration Scale (IT-MAIS)*^(16,18,21,24,25,32,36); *Meaningful Auditory Integration Scale (MAIS)*^(18,25,33,34,36); *Meaningful Use of Speech Scale (MUSS)*^(21,32,33,36); and *Early Speech Perception Test (ESP)*^(22,24,25).

Regarding the CI, 11.95% (n=30) stopped using it to use the ABI, and 12.35% (n=31) were using both devices concurrently. One study⁽²²⁾ evaluated five children between 1.6 and 5 years old with cochlear hypoplasia. Three used CI (two unilateral and one bilateral) before the ABI implantation. The two children using unilateral CI were not using their devices due to a lack of benefits. They underwent surgery to place the ABI on the contralateral side. The child using bilateral CI showed hearing detection. However, the child no longer benefited from the devices, even after four years in intensive auditory rehabilitation therapy. This child underwent the removal of both devices and had the ABI implanted bilaterally. In children using unilateral CI, after placing the ABI, the scores remained low. Only vocalizations developed, but there was no evolution toward vocabulary emission. The child who underwent bilateral ABI placement started recognizing consonants after three years of using these devices. There were some visual communication methods indicated for these patients.

Another study⁽²¹⁾ evaluated 12 children with varied etiologies. Eight were using CI before undergoing ABI placement. The CI was removed in five of the eight children, and the ABI was implanted ipsilaterally. The ABI was implanted contralaterally in the remaining children, with both devices remaining. Most of the children showed hearing detection when using the ABI and a better score on the CAP. Only one of the children using CI and ABI showed development in auditory skills, achieving recognition of familiar sentences without lip-reading aids. The authors concluded that ABI might be a feasible treatment option for individuals who cannot be treated with CI.

Another study evaluated 12 patients⁽³⁴⁾, and nine had used CI before ABI. The authors considered that using CI “failed” when, after six months of using the device, users did not show any evolution in the development of auditory and oral language skills. All 12 patients had auditory nerve hypoplasia. Among them, 11 advanced to auditory detection with the ABI, four scored 50% on open-set speech perception tests, and two scored 50% on closed-set auditory discrimination tests.

Another study⁽²⁵⁾ evaluated ten children. All of them had previous CI experience. Six of them stopped using CI to use the ABI, and the other four children continued with CI only, without opting for the ABI, even though three showed no benefits with the device. Four of the six children who used the ABI had auditory nerve hypoplasia. After three years of ABI use, only one of these four children could auditory recognize open-set words. All the children could emit basic isolated everyday

vocabulary after one to two years of using the ABI. However, their speech intelligibility was impaired.

It is worth noting that many children with anatomical alterations of the cochlea or auditory nerve stopped using CI and migrated to ABI. They aimed for better results in developing hearing and language skills. Experience with CI before ABI implantation may favor the development of auditory perception skills. In one of the studies⁽³⁴⁾ included in this review, the authors state that the combined use of CI and ABI can bring better scores regarding vocabulary recognition for children with pre-lingual deafness. However, all the children evaluated in this study were learning sign language or another visual communication method. The authors of all the papers included in this review were unanimous in indicating a communication method other than oral for children using ABI.

Most children had hearing thresholds between 90 and 120 dBHL before ABI implantation. They started to present minimum free-field response levels between 20 and 45 dBHL with the device, reinforcing the importance of speech therapy in this population since the improvement in tonal auditory thresholds does not represent good performance in auditory speech perception and oral language development.

Most of the ABI users’ performance is equivalent to single-channel CI performance. Even though post-surgical outcomes are well documented as significantly poorer than CI outcomes worldwide, the device can improve the individual’s communication and socialization. It improves the children’s physical and psychological safety, helping them to better connect to the environment and the people around them⁽²⁰⁾.

One of the studies⁽³²⁾ concluded that the performance of children with ABI without other comorbidities could be matched with that of a CI-using child who has comorbidities other than hearing impairment.

The results in the specific literature vary, even though most authors agree that most children who undergo ABI implantation achieve limited results. There is a slow evolution regarding the development of auditory skills, with almost no evolution in the first year, differing from the evolution that occurs when the cochlear implant⁽¹⁸⁾ is used.

ABI in adults

Regarding the studies comprising adult samples (n=6), 104 individuals were evaluated. In terms of etiology, neurofibromatosis type 2 (NF-2) predominated in 84.61% (n=88), followed by cochlear ossification in 11.53% (n=12), and other unspecified etiologies in 3.86% (n=4).

A study⁽²⁷⁾ conducted with adults suffering from NF-2 evaluated ten individuals, and nine of them had previously used CI. We observed that CI was more beneficial regarding auditory speech perception in the first years. However, four individuals showed regression in auditory skills, and the CI ceased providing benefits in this regard. On the other hand, ABI demonstrated benefits for neuroplasticity related to auditory skills about eight years post-implantation in all nine participants and no subsequent decline. Nevertheless, users who have had experiences with both devices have reported preferring the CI’s sound quality to that of the ABI. The study concluded that although CI has easier electrode placement and outperforms ABI in benefits in the early years, ABI remains the best treatment option for patients with NF-2.

A study⁽³⁷⁾ conducted in 2012 evaluated four adults with NF-2, one CI user and three ABI users. The three ABI users had an average age of 26 years and an average of six years of deafness. They regularly used their devices. Auditory performance varied. One of the participants could not recognize open-set sentences and only recognized 20% in closed sets. The other two recognized 100% closed-set sentences and 10% and 20% in open sets. Only one could communicate over the phone. The CI-using participant was 36 years old, had progressive deafness for ten years, used the CI regularly, and had been using the contralateral hearing aids for seven months. After 12 months, the patient had only developed the ability to detect environmental sounds. This study concluded that when the auditory nerve is not preserved, ABI is the best option for auditory rehabilitation in patients with NF-2. This fact had already been confirmed by a study⁽³⁸⁾ conducted in 2008, in which nine adults with NF-2 were evaluated (four CI users and five ABI users). The participants were matched according to chronological age, which ranged from 22 to 47 years. The authors concluded that the results presented by ABI users, even if limited, were superior to those of CI users.

The articles were published in 17 journals, and all had an impact factor of *Journal Citation Reports* (JCR) 2019. Five of these journals had more than one article published. The impact factor has been prioritized in the evaluation of current scientific information published⁽³⁹⁾.

Study limitation

Given that this is a scoping review, this study has potential limitations regarding the heterogeneity and publication bias of the included studies.

CONCLUSION

When possible, children who are candidates for ABI may have the development of auditory skills favored when using a contralateral CI. There was little or no evolution in the development of auditory skills and oral language during the first years of ABI use. Most users do not achieve open-set auditory recognition ability. In other words, they do not acquire the ability to recognize speech audibly without any response clue/alternative, even after years of use.

The ABI is reported to be the best hearing device option for cases of adults who have neurofibromatosis type 2.

There is slow progress and poor prognosis regarding oral language development. Individuals need to use orofacial reading during communication, especially when it comes to children with pre-lingual hearing loss. Researchers unanimously recommend visual communication methods, such as sign language or alternative communication.

REFERENCES

- Bento RF, Brito R No, Castilho AM, Gómez VG, Giorgi SB, Guedes MC. Resultados auditivos com o implante coclear multicanal em pacientes submetidos a cirurgia no Hospital das Clínicas da Faculdade de Medicina da Universidade de São Paulo. *Rev Bras Otorrinolaringol*. 2004;70(5):632-7. <http://dx.doi.org/10.1590/S0034-72992004000500009>.
- Silva BCS, Moret ALM, Silva LTDN, Costa OAD, Alvarenga KF, Silva-Comerlato MPD. Glendonald Auditory Screening Procedure (GASP): marcadores clínicos de desenvolvimento das habilidades de reconhecimento e compreensão auditiva em crianças usuárias de implante coclear. *Codas*. 2019 Ago 15;31(4):e20180142. <http://dx.doi.org/10.1590/2317-1782/20192018142>. PMID:31433038.
- Bento RF, Brito RV No, Tsuji RK, Gomes MQT, Goffi-Gomez MVS. Implante auditivo de tronco cerebral: técnica cirúrgica e resultados auditivos precoces em pacientes com neurofibromatose tipo 2. *Rev Bras Otorrinolaringol*. 2008;74(5):647-51. <http://dx.doi.org/10.1590/S0034-72992008000500002>.
- Malerbi AS. Implante auditivo de tronco encefálico em pacientes com perda auditiva neurossensorial profunda por meningite e ossificação coclear total bilateral [tese]. São Paulo: Faculdade de Medicina, Universidade de São Paulo; 2017. <http://dx.doi.org/10.11606/T.5.2017.tde-25082017-094437>.
- Fernandes NF, Goffi-Gomez MV, Magalhães AT, Tsuji RK, De Brito RV, Bento RF. Satisfação e qualidade de vida em usuários de implante auditivo de tronco cerebral. *CoDAS*. 2017;29(2):e20160059. <http://dx.doi.org/10.1590/2317-1782/20172016059>. PMID:28355382.
- Santos SN, Tochetto TM. Implante auditivo do tronco encefálico: revisão de literatura. *Rev CEFAC*. 2007;9(4):543-9. <http://dx.doi.org/10.1590/S1516-18462007000400015>.
- Fernandes NF. Benefícios do implante auditivo de tronco cerebral em adultos e crianças [tese]. São Paulo: Faculdade de Medicina, Universidade de São Paulo; 2018. <http://dx.doi.org/10.11606/T.5.2018.tde-02082018-125921>.
- Galvão TF, Pereira BMG. Revisões sistemáticas da literatura: passos para sua elaboração. *Epidemiol Serv Saude*. 2014;23(1):183-4. <http://dx.doi.org/10.5123/S1679-49742014000100018>.
- Mandrá PP, Moretti TCF, Avezum LA, Kuroishi RCS. Terapia assistida por animais: revisão sistemática da literatura. *CoDAS*. 2019;31(3):e20180243. <http://dx.doi.org/10.1590/2317-1782/20182018243>. PMID:31271584.
- Yücel E, Aslan F, Özkan HB, Sennaroglu L. Recent rehabilitation experience with pediatric ABI users. *J Int Adv Otol*. 2015;11(2):110-3. <http://dx.doi.org/10.5152/iao.2015.915>. PMID:26380998.
- Puram SV, Herrmann B, Barker FG 2nd, Lee DJ. Retrosigmoid craniotomy for auditory brainstem implantation in adult patients with neurofibromatosis Type 2. *J Neurol Surg B Skull Base*. 2015;76(6):440-50. <http://dx.doi.org/10.1055/s-0034-1544121>. PMID:27054058.
- Lundin K, Stillesjö F, Nyberg G, Rask-Andersen H. Self-reported benefit, sound perception and quality-of-life in patients with auditory brainstem implants (ABIs). *Acta Otolaryngol*. 2016;136(1):62-7. <http://dx.doi.org/10.3109/00016489.2015.1079925>. PMID:26426855.
- Sennaroglu L, Sennaroglu G, Yücel E, Bilginer B, Atay G, Bajin MD, et al. Long-term results of ABI in children with severe inner ear malformations. *Otol Neurotol*. 2016;37(7):865-72. <http://dx.doi.org/10.1097/MAO.0000000000001050>. PMID:27273392.
- Lundin K, Stillesjö F, Nyberg G, Rask-Andersen H. Experiences from Auditory Brainstem Implantation (ABIs) in four paediatric patients. *Cochlear Implants Int*. 2016;17(2):109-15. <http://dx.doi.org/10.1080/14670100.2016.1142693>. PMID:26841821.
- Puram SV, Barber SR, Kozin ED, Shah P, Remenschneider A, Herrmann BS, et al. Outcomes following Pediatric Auditory Brainstem Implant Surgery. *Otolaryngol Head Neck Surg*. 2016 Jul;155(1):133-8. <http://dx.doi.org/10.1177/0194599816637599>. PMID:27095049.
- Thong JF, Sung JKK, Wong TKC, Tong MCF. Auditory brainstem implantation in chinese patients with neurofibromatosis Type II: the

- Hong Kong Experience. *Otol Neurotol*. 2016;37(7):956-62. <http://dx.doi.org/10.1097/MAO.0000000000001101>. PMID:27273391.
17. Ramsden RT, Freeman SRM, Lloyd SKW, King AT, Shi X, Ward CL, et al. Auditory brainstem implantation in neurofibromatosis Type 2: experience from the Manchester Programme. *Otol Neurotol*. 2016;37(9):1267-74. <http://dx.doi.org/10.1097/MAO.0000000000001166>. PMID:27525707.
 18. Wilkinson EP, Eisenberg LS, Krieger MD, Schwartz MS, Winter M, Glater JL, et al. Initial results of a safety and feasibility study of auditory brainstem implantation in congenitally deaf children. *Otol Neurotol*. 2017;38(2):212-20. <http://dx.doi.org/10.1097/MAO.0000000000001287>. PMID:27898605.
 19. Goyal S, Krishnan SS, Kameswaran M, Vasudevan MC, Ranjith, Natarajan K. Does cerebellar flocculus size affect subjective outcomes in pediatric auditory brainstem implantation. *Int J Pediatr Otorhinolaryngol*. 2017;97:30-4. <http://dx.doi.org/10.1016/j.ijporl.2017.03.027>. PMID:28483247.
 20. Al-Momani MO. Five years audiological outcomes of the first Saudi Auditory Brainstem Implant (ABI). *Saudi J Otorhinolaryngol Head Neck Surg*. 2017;19(1):32-4. <http://dx.doi.org/10.4103/1319-8491.275311>.
 21. Jung NY, Kim M, Chang WS, Jung HH, Choi JY, Chang JW. Favorable long-term functional outcomes and safety of auditory brainstem implants in nontumor patients. *Oper Neurosurg (Hagerstown)*. 2017;13(6):653-60. <http://dx.doi.org/10.1093/ons/oxp046>. PMID:29186598.
 22. Teagle HFB, Henderson L, He S, Ewend MG, Buchman CA. Pediatric Auditory brainstem implantation: surgical, electrophysiological and behavioral outcomes. *Ear Hear*. 2018;39(2):326-36. <http://dx.doi.org/10.1097/AUD.0000000000000501>. PMID:29023243.
 23. Sung JKK, Luk BPK, Wong TKC, Thong JF, Wong HT, Tong MCF. Pediatric auditory brainstem implantation impact on audiological rehabilitation and tonal language development. *Audiol Neurootol*. 2018;23(2):126-34. <http://dx.doi.org/10.1159/000491991>. PMID:30227389.
 24. Asfour L, Friedmann DR, Shapiro WH, Roland JT Jr, Waltzman SB. Early experience and health related quality of life outcomes following auditory brainstem implantation in children. *Int J Pediatr Otorhinolaryngol*. 2018;113:140-9. <http://dx.doi.org/10.1016/j.ijporl.2018.07.037>. PMID:30173973.
 25. Eisenberg LS, Hammes Ganguly D, Martinez AS, Fisher LM, Winter ME, Glater JL, et al. Early communication development of children with auditory brainstem implants. *J Deaf Stud Deaf Educ*. 2018;23(3):249-60. <http://dx.doi.org/10.1093/deafed/eny010>. PMID:29718280.
 26. Friedmann DR, Asfour L, Shapiro WH, Roland JT Jr, Waltzman SB. Performance with an auditory abrainstem implant and contralateral cochlear implant in pediatric patients. *Audiol Neurootol*. 2018;23(4):216-21. <http://dx.doi.org/10.1159/000493085>. PMID:30391957.
 27. Peng KA, Lorenz MB, Otto SR, Brackmann DE, Wilkinson EP. Cochlear Implantation and Auditory Brainstem Implantation in Neurofibromatosis Type 2. *Laryngoscope*. 2018;128(9):2163-9. <http://dx.doi.org/10.1002/lary.27181>. PMID:29573425.
 28. Malerbi AFDS, Goffi-Gomez MVS, Tsuji RK, Gomes MQT, Brito R No, Bento RF. Auditory brainstem implant in postmeningitis totally ossified cochleae. *Acta Otolaryngol*. 2018;138(8):722-6. <http://dx.doi.org/10.1080/00016489.2018.1449964>. PMID:29607748.
 29. Raghunandhan S, Madhav K, Senthilvadivu A, Natarajan K, Kameswaran M. Paediatric auditory brainstem implantation: the South Asian experience. *Eur Ann Otorhinolaryngol Head Neck Dis*. 2019;136(3S):S9-14. <http://dx.doi.org/10.1016/j.anorl.2018.08.015>. PMID:30293957.
 30. Faes J, Gillis S. Expressive vocabulary growth after pediatric auditory brainstem implantation in two cases' spontaneous productions: a comparison with children with cochlear implants and typical hearing. *Front Pediatr*. 2019;7:191. <http://dx.doi.org/10.3389/fped.2019.00191>. PMID:31157193.
 31. Faes J, Gillis S. Auditory brainstem implantation in children with hearing loss: effect on speech production. *Int J Pediatr Otorhinolaryngol*. 2019;119:103-12. <http://dx.doi.org/10.1016/j.ijporl.2019.01.014>. PMID:30690306.
 32. van der Straaten TFK, Netten AP, Boermans PPBM, Briaire JJ, Scholing E, Koot RW, et al. Pediatric auditory brainstem implant users compared with cochlear implant users with additional disabilities. *Otol Neurotol*. 2019;40(7):936-45. <http://dx.doi.org/10.1097/MAO.0000000000002306>. PMID:31295204.
 33. Rajeswaran R, Kameswaran M. Auditory brainstem implantation (ABI) in children without neurofibromatosis type II (NF2): communication performance and safety after 24 months of use. *Cochlear Implants Int*. 2020;21(3):127-35. <http://dx.doi.org/10.1080/14670100.2019.1690264>. PMID:31847793.
 34. Batuk MO, Cinar BC, Yarali M, Aslan F, Ozkan HB, Sennaroglu G, et al. Bimodal stimulation in children with inner ear malformation: one side cochlear implant and contralateral auditory brainstem implant. *Clin Otolaryngol*. 2020;45(2):231-8. <http://dx.doi.org/10.1111/coa.13499>. PMID:31854074.
 35. Aslan F, Ozkan HB, Yucel E, Sennaroglu G, Bilginer B, Sennaroglu L. Effects of age at auditory brainstem implantation: impact on auditory perception, language development, speech intelligibility. *Otol Neurotol*. 2020;41(1):11-20. <http://dx.doi.org/10.1097/MAO.0000000000002455>. PMID:31789803.
 36. Fernandes NF, de Queiroz Teles Gomes M, Tsuji RK, Bento RF, Goffi-Gomez MVS. Auditory and language skills in children with auditory brainstem implants. *Int J Pediatr Otorhinolaryngol*. 2020;132:110010. <http://dx.doi.org/10.1016/j.ijporl.2020.110010>. PMID:32234651.
 37. Monteiro TA, Goffi-Gomez MV, Tsuji RK, Gomes MQ, Brito Neto RV, Bento RF. Neurofibromatosis 2: hearing restoration options. *Braz J Otorhinolaryngol*. 2012;78(5):128-34. <http://dx.doi.org/10.5935/1808-8694.20120020>. PMID:23108832.
 38. Vincenti V, Pasanisi E, Guida M, Di Trapani G, Sanna M. Hearing rehabilitation in neurofibromatosis type 2 patients: cochlear versus auditory brainstem implantation. *Audiol Neurootol*. 2008;13(4):273-80. <http://dx.doi.org/10.1159/000115437>. PMID:18259080.
 39. Marziale MHP, Mendes IAC. O fator de impactos das publicações científicas. *Rev Latino-am Enfermagem*. 2002;10(4):466-7. <http://dx.doi.org/10.1590/S0104-11692002000400001>.