

# Dystroglycanopathies: Genetic Bases of Muscular Dystrophies Due to Alteration in the O-Glycosylation of $\alpha$ -Dystroglycan

M.A. Cubilla<sup>1,2</sup>, G.M. Papazoglu<sup>1,2</sup> and C.G. Asteggiano<sup>1,2,3</sup> 

## Abstract

Congenital muscular dystrophies (CMDs) are inherited, progressive and heterogeneous muscle disorders. A group of CMDs are dystroglycanopathies, also called  $\alpha$ -dystroglycanopathies, where there is an abnormal glycosylation of protein  $\alpha$ -dystroglycan. Hypoglycosylation of  $\alpha$ -DG results in different severities of congenital muscular dystrophies and they present with progressive muscle weakness and loss of motor functions. This article first focuses on the CMDs, their classification according to the observed symptoms or the protein involved in the resulting phenotype. We then focus on dystroglycanopathies, the importance of its correct O-glycosylation of the  $\alpha$ -dystroglycan given its important structural function, considering the enzymes involved in said glycosylation and the phenotypes that can result, to finally address current therapeutics for these diseases with the aim of increasing current knowledge.

## Keywords:

Congenital muscular dystrophies (CMDs),  $\alpha$ -dystroglycan protein ( $\alpha$ DG), glycosylation, muscle disorders, dystroglycanopathies.

## Introduction

Congenital muscular dystrophies (CMDs) are inherited, progressive and heterogeneous muscle disorders [1]. They affect children at birth or appear during the first months of life with a predominant autosomal recessive mode of inheritance, except for laminopathies (L-CMD) and some Ullrich congenital muscular dystrophies (U-CMDs) [2]. These disorders are characterized by congenital hypotonia, delayed motor development and early onset of progressive muscle weakness, and they can comprise the involvement of brain and eyes [1].

In principle, the CMDs were classified by histological and clinical criteria.

The classification of these diseases is complex [2], and in general it is based on phenotype characteristics defined by clinical criteria and histochemical analysis considering the following criteria:

1. Involvement or non-involvement of the Central Nervous System.
2. Increased muscle enzyme, Creatine Kinase (CK).
3. Neuro-radiological abnormalities.
4. Protein expression (Laminin  $\alpha$ 2, Dytroglycan, collagen).

Clinical features, immunohistochemical staining, Western blot, brain and muscle's Magnetic Resonance Imaging (MRI) are all useful tools to direct genetic testing.

They can be also classified according to the subcellular location of the mutated protein and/or the consequences at the skeletal muscle level (extracellular matrix, sarcolemma, basal lamina, endoplasmic reticulum, and nuclear envelope). The CK levels are low or remain unchanged [1,3].

In 2018, Quijano-Roy *et al* set out a global algorithm that facilitates the classification into five main forms of CMDs according to the affected gene [1] but there are several genes that have been discovered in the last years [1,4] (Figure 1).

<sup>1</sup> Centro de Estudio de las Metabolopatías Congénitas Hospital de Niños de la Santísima Trinidad, Córdoba, Argentina.

<sup>2</sup> Consejo Nacional de Investigaciones Científicas y Técnicas, Buenos Aires, Argentina.

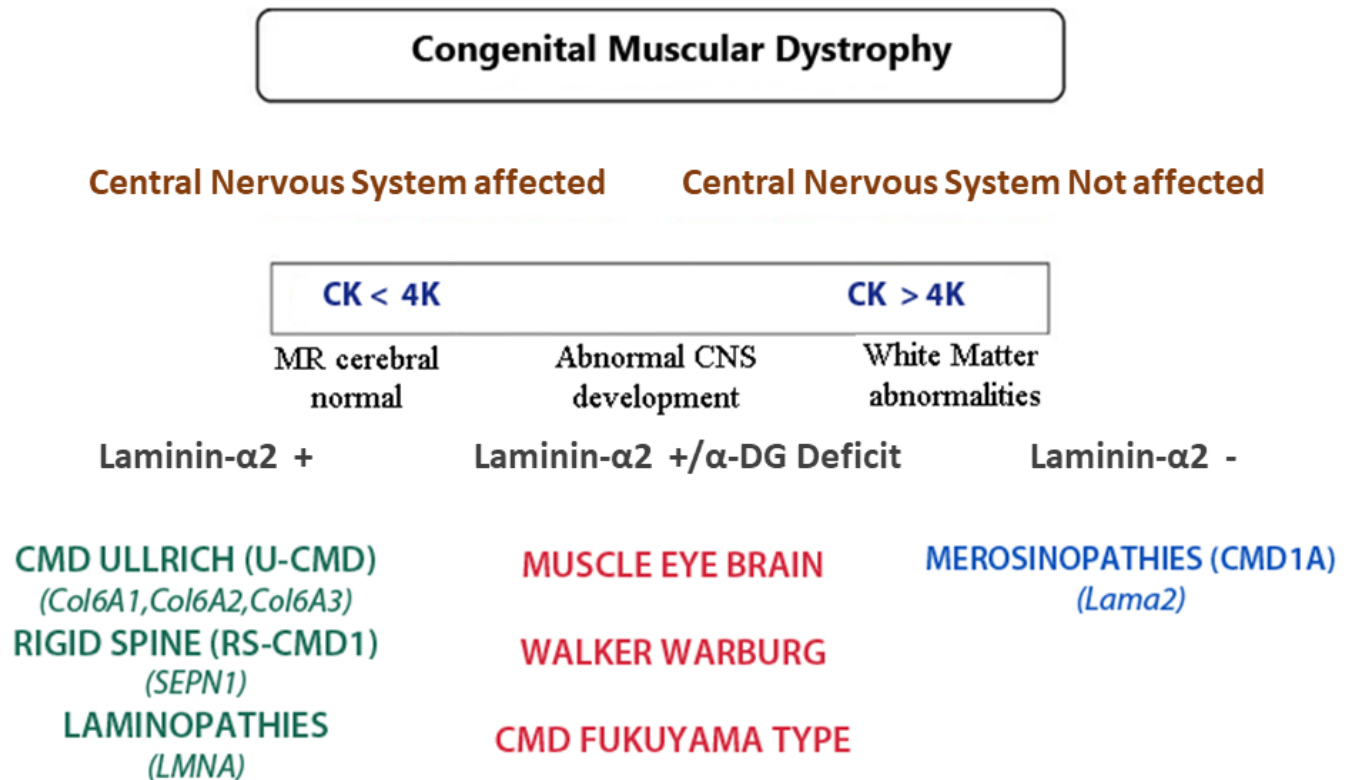
<sup>3</sup> Universidad Católica de Córdoba, Facultad de Ciencias de la Salud, Carrera Medicina, Catedra de Farmacología, Córdoba, Argentina.

Received May 20, 2022. Accepted for publication March 07, 2023.

## Corresponding Author:

C.G. Asteggiano, E-mail: [asteggianocarla@gmail.com](mailto:asteggianocarla@gmail.com)





**Figure 1.** Classification of Congenital Muscular Dystrophies. Adapted from Quijano *et al* 2018.

A summary proposal by Zamboni and Mutoni considers the subcellular location of the mutated protein and they classified CMDs as follows [4]:

*Defective structural proteins of basal membrane or extracellular matrix of muscle fibers*

**LAMA2-RD:** The laminin  $\alpha$ 2-related muscular dystrophies (LAMA2-RDs), previously known as merosin-deficient congenital muscular dystrophy type 1A (MDC1A), are autosomal recessive disorders caused by pathogenic variants in the LAMA2 gene [5–6]. LAMA2 encodes for the alpha-2 subunit of heterotrimeric laminin-2 protein (made up of  $\alpha$ 2,  $\beta$ 1, and  $\gamma$ 1 subunits) with the  $\alpha$ 2 subunit called laminin-211 or merosin serving as a tissue-specific component of the extracellular matrix with a key role in myotubes stability and apoptosis [7]. The spectrum of LAMA2-RD ranges from severe CMD (90% of cases) to milder, later childhood-onset LGMD largely due to the amount of residual Lm-211 protein in muscle (complete vs partial deficiency, CD vs PD) [4]. To date, there are no effective treatments for LAMA2-RDs [7]. With an estimated prevalence of 0.6-0.7/100,000, LAMA2-RD is one of the most common types of CMDs. It is clinically manifested by hypotonia and weakness at birth, the development of contractures of large joints, and progressive respiratory involvement. Muscle atrophy and severe weakness typically prevent independent ambulation [7–9].

**COL6-RD:** Collagen VI-related myopathies are hereditary myopathies caused by mutations in either COL6A1, COL6A2

or COL6A gene, each encoding a subunit of collagen VI [10–11]. The clinicopathological hallmarks include distal hyperlaxity, proximal joint contractures, protruding calcanei, skin hyperkeratosis, scoliosis and respiratory insufficiency [12]. Approximately three quarters of individuals with congenital/severe COL6-RD acquire the ability to walk independently, but subsequently their motor skills decline, with loss of ambulation occurring around 9–11 years of age [4].

**Integrin  $\alpha$ -7 deficient CMD:** This CMD is caused by mutation in integrin  $\alpha$ 7 (ITGA7) and it is a rare subtype. This gene has 28 exons, among which 26 code for protein [13]. Only a few patients diagnosed with CMD were found to have ITGA7 mutation [6,13–16] and it is not clear whether all variants are pathogenic mutations. Variants of ITGA7 present microcephaly, agenesis of the corpus callosum, cerebellar hypoplasia, seizures, scoliosis, hemivertebrae, asymmetric extremities, and hypopigmented skin macules [16]. These had various symptoms and different grades of severity. The consistent clinical features were muscle weakness and increased CK level [13].

**Integrin  $\alpha$ -9 deficient CMD:** The  $\alpha$ -9 integrin is one of the younger evolutionary additions to the integrin family of receptors. This integrin subunit is expressed in a variety of cell types and binds to a plethora of ligands, some of which are restricted to specific tissues, or are upregulated during development or in pathophysiological conditions. There have not been many reports describing mutations in integrin  $\alpha$ -9 [17]. This could indicate that mutations in  $\alpha$ -9 is a rare event, and that it is the  $\alpha$ -9 expression level (or a lack of it) that is important in

developing pathophysiological conditions, which was already suggested when ITGA9 was first cloned [18].

**Dystroglycanopathies (DGP)/defects of  $\alpha$ -DG glycosylation:** They are a group of muscular dystrophies where there is an abnormal glycosylation of  $\alpha$ -dystroglycan protein ( $\alpha$ -DG). This protein is a fundamental component of the Dystrophin glycoprotein complex (DGC), which is essential to link the extracellular matrix (ECM) to the intracellular actin cytoskeleton [4]. The clinical symptoms are diverse, ranging from severe congenital to adult-onset limb-girdle types [19–20]. Primary dystroglycanopathy is due to defects in the coding sequence of  $\alpha$ -DG [21–22]. Around 20 genes have been associated with secondary dystroglycanopathies, including glycosyltransferases for O-mannitol type glycosylation, a kinase, enzymes involved in nucleotide sugar synthesis (dolichol—P-Mannose), proteins necessary for joining the  $\alpha$ -DG-linked core glycan structure with distal ligand-binding region and Golgi membrane trafficking proteins [23–24].

### *Endoplasmic reticulum protein*

**SEPN1-related Myopathy:** SEPN1 or SELENON is a ubiquitous endoplasmic/sarcoplasmic reticulum (ER/SR) protein encoded by the *SELENON* (or *SEPN1*) gene. It protects cells against oxidative stress or ER-stress and defends calcium homeostasis by counteracting ERO1-mediated oxidation of the ATP-dependent  $\text{Ca}^{2+}$  pump SERCA [25]. Mutations of the SEPN1 gene are characterized by muscle weakness and fatigue leading to scoliosis and life-threatening respiratory failure. Core lesions and focal areas of mitochondria depletion in skeletal muscle fibers are the most common histopathological lesions [26]. This myopathy comprises a spectrum of pathological conditions encompassing rigid spine muscular dystrophy, multi-minicore disease, congenital fiber-type disproportion and desmin-related myopathy with Mallory body-like inclusions [4]. This a Study reveals SEPN1-RM as a more severe and progressive disease than previously thought. While motor abilities were reported to be stable, it was found loss of ambulation in 10% of the cases with full follow-up data. Muscle functional performance and respiratory function (particularly diaphragmatic fatigue) declined systematically from the end of the third decade, even in mild cases. But lifespan was reduced even in 2 mild cases with optimum respiratory support [27].

### *Nuclear envelope proteins*

**LMNA-Related CMD:** A-type lamins (lamin A and C) are intermediate filament proteins expressed in differentiated cells [28]. Together with B-type lamins, they form the nuclear lamina, an organized meshwork found under neath the inner nuclear envelope [29]. Laminopathies are a heterogeneous group of disorders caused by mutations in the LMNA gene encoding lamin A/C. This includes striated skeletal and cardiac muscles, and it includes Emery–Dreifuss muscular dystrophy (EDMD), limb-girdle muscular dystrophy type 1B (previously

known as LGMD1B) and isolated dilated cardiomyopathy with conduction system defects and arrhythmias (DCMCD). LMNA-related congenital muscular dystrophy (L-CMD) has been described as an autosomal dominant muscle disorder related to a dominant de novo mutation in LMNA, so far, the most severe form of striated muscle laminopathies [30]. L-CMD group can operationally be defined as having an onset of skeletal muscle manifestations within the first two years of life, when early motor development, that includes walking and running, should be typically attained. It is of great medical importance to distinguish this group of patients due to the potential of early life-threatening complications involving nutritional, respiratory and cardiac compromise [31].

**SYNE-Related CMD (nesprin):** EDMD is associated with at least seven gene mutations, of which SYNE1 mutation is relatively less common [32]. The SYNE1 (Spectrin Repeat Containing Nuclear Envelope Protein 1) gene has an autosomal dominant inheritance pattern, and its mutations might result in defects in the expression product nesprin-1 [33], a protein characterized by the presence of multiple spectrin repeats which is highly expressed in striated muscles [34]. Besides, the mutations in the SYNE1 gene cause spinocerebellar ataxia type 8, myogenic multiplex arthrogryposis congenital with features of EDMD, intellectual disability with spastic paraplegia, and axonal neuropathy [35–37].

### *Proteins involved in ER to Golgi apparatus trafficking*

There are two genes that represent the first membrane trafficking proteins implicated in  $\alpha$ -DG hypoglycosylation. TRAPPC11 and GOSR2, that each have a role in membrane trafficking in the biosynthetic pathway, have been implicated as candidate dystroglycanopathy genes [4].

**TRAPPC11:** Transport protein particle (TRAPP) is a supramolecular protein complex that functions in the localization of proteins to the Golgi compartment. The TRAPPC11 subunit has been implicated in muscle disease through the identification of homozygous and compound heterozygous deleterious mutations in individuals with limb girdle muscular dystrophy and congenital muscular dystrophy. These individuals also display membrane trafficking defects in cultured fibroblasts; this gene should be considered in the diagnostic evaluation of patients with CMD [24,38].

**GOSR2:** Pathogenic variants in the Golgi SNAP receptor complex 2 gene (GOSR2, also known as Membrin) are well-known to be associated with autosomal recessive progressive myoclonic epilepsy (PME) [39], but some new compound heterozygous variants in the GOSR2 gene have expanded the clinical spectrum [24,40]. This variant has progressive muscle weakness and areflexia, and it developed seizures in early childhood. Muscle biopsy showed an active dystrophic process and hypoglycosylation of alpha-dystroglycan. This is suggestive of a dystroglycanopathy, which is a known cause of congenital muscular dystrophy [41].

There are another condition (called **CMD PLUS**) that share clinical features with CMD, for example, Megaconial CMD or Marinesco-Sjogren Syndrome (MSS) [4]. These conditions have overlapping pathological and clinical changes that often lead to diagnostic difficulties with CMD. Some of them are listed in Table 1.

This review focuses on dystroglycanopathies, also called  $\alpha$ -dystroglycanopathies (CMD- $\alpha$ DG).

## Dystroglycanopathies

These pathologies owe their etiology to mutations in genes involved in the O-glycosylation of  $\alpha$ -DG protein [42]. At least 20 genes are involved in the correct O-glycosylation of  $\alpha$ -DG. They are classified into primary and secondary dystroglycanopathies [20] (Table 2). The first ones are due to mutations of the *DAG1* gene that alter the state of the DG core protein with potential repercussions on the glycosylation state of  $\alpha$ -DG. The second ones are due to mutations in the genes that participate in the O-glycosylation of  $\alpha$ -DG including enzymes involved in nucleotide sugar synthesis and Golgi membrane trafficking proteins [23–24]. Primary dystroglycanopathies are comparatively less studied due to the small number of cases identified so far. *DAG1* mutations are rare, recessive mutations that are found in consanguineous families. Dystroglycanopathies exhibit a broad clinical spectrum [43], because of the mutation on the activity of the protein involved. One of the characteristics of these dystrophies is the involvement of central nervous system disorders, such as malformation of the brain (type II lissencephaly) and mental retardation (although there are times that this occurs without structural abnormalities). Cases with heart failure and eye symptoms have also been observed [44–48].

The glycosylation status of  $\alpha$ -DG is strictly regulated with respect to both developmental stage and tissue (in brain, heart, skeletal muscle, and kidney,  $\alpha$ -DG is modified in a way that it can function as an ECM-receptor) [49].

### Functional Importance and Genetic Bases of $\alpha$ -Dystroglycan

The dystrophin glycoprotein complex (DGC), which is essential to link the extracellular matrix (ECM) to the intracellular actin cytoskeleton, takes center stage in several physiological and pathological contexts, playing a particularly important role in skeletal muscle. This gives stability to a big number of tissues, such as skeletal and smooth muscles, the brain and peripheral nervous system, the neuromuscular junction, the interface between endothelial cells and the surrounding astrocytes end-feet at the blood-brain barrier, the kidney glomeruli basement membrane, and the lungs at the epithelia-connective border [20,50–51].

*DAG1* gene has a highly conserved sequence between species and has been mapped to human chromosome 3p21 [52]. Coding sequence is organized into two exons, separated by a large intron. The derived 5.8 kb transcript contains an 895-residue open reading frame. This propeptide is post-translationally cleaved by an unknown protease at residue 653 (P) to yield  $\alpha$ - and  $\beta$ -dystroglycan ( $\alpha$ -DG and  $\beta$ -DG) [51,53–54].  $\beta$ -DG protein contains a single transmembrane domain, one potential N-linked glycosylation site, and a 121-residue C-terminal cytoplasmic tail that is enriched in proline.  $\alpha$ -DG is an extracellular protein that contains three potential N-linked glycosylation sites. DGC complexes associated with various proteins via  $\alpha$ -DG y  $\beta$ -DG.

**Table 1.** Genes and Protein implicated in CMDs called CMD plus.

OtherCMDs/CMD spectrum	Gene symbol	OMIN ref	Protein/Function
Mitochondrial CMD	CHKB	602,541	Choline kinase
MD with cerebellar involmente	MSTO1	617,675	Mitochondrial fusion
MD with extrapiramidal signs	MICUI	615,673	Mitochondrial Ca <sup>2+</sup> uptake/ mitochondria mediated sarcolemma repair
CMD with cataracts and intellectual disability	INPP5K	617,404	Inositol polyphosphate-5-phosphatase K
Marinesco-Sjogren syndrome	SIL-1	248,800	Protein Folding
Mucopolipidosis type IV	MCOLN1	252,650	Nonselective cation chanel in lysosomal endosomal trafficking
MD/hearing Loss/Ovarian insufficiency Syndrme	GGPSI	606,982	Mevalonat/isoprenoid pathway

**Table 2.** Genes associated to dystroglycanopathies.

Gene	OMIM ref	Protein Functions
<b>Primary dystroglycanopathy</b>		
DAG1	616,538	Dystroglycan
<b>Secondary dystroglycanopathy</b>		
POMT1	607,423	Protein O-mannosyltransferase
POMT2	607,439	Protein O-mannosyltransferase
POMGnT1	606,822	Protein O-mannose $\beta$ 1,2-N-acetylglucosaminyltransferase; Core M1 synthesis
POMGnT2	614,828	Protein O-mannose $\beta$ 1,2-N-acetylglucosaminyltransferase; Core M3 synthesis
B3GALT2	610,194	$\beta$ -1,3-N-acetylgalactosaminyltransferase; Core M3 synthesis
POMK	615,247	Protein O-mannose kinase; Phosphorylation of Core M3
FKTN	607,440	Ribitol phosphate transferase, tandem ribitol synthesis
FKRP	606,596	Ribitol phosphate transferase, tandem ribitol synthesis
ISPD/CRPPA	614,631	CDP-ribitolpyrophosphorylase; synthesis of CDP-ribitol (donor substrate of FKTN/FKRP)
TMEM5/RXYLT1	605,862	$\beta$ -1,4-xylosyltransferase; synthesis of linker structure between tandem ribitol and matriglycan
B4GAT1	615,287	$\beta$ -1,4-Glucuronyltransferase; synthesis of linker structure between tandem ribitol and matriglycan
LARGE1	603,590	$\alpha$ 3-Xylosyl and $\beta$ 3-glucuronyltransferase; matriglycan synthesis
GMPPB	615,320	GDP-mannose pyrophosphorylase required for the formation of GDP-Man; Dolichol-phosphate-mannose synthesis
DPM1	603,503	Dolichol-phosphate-mannose synthase; Dolichol-phosphate-mannose synthesis
DPM2	603,564	Dolichol-phosphate-mannose synthase; Dolichol-phosphate-mannose synthesis
DPM3	605,951	Dolichol-phosphate-mannose synthase; Dolichol-phosphate-mannose synthesis
DOLK	610,768	Dolichol kinase required for formation of dolichol -phosphate; Dolichol-phosphate-mannose synthesis

$\beta$ -DG (Figure 2) subunit binds intracellularly to dystrophin, that joins to the intracellular actin cytoskeleton; and it extracellularly binds to  $\alpha$ -DG, which in turn binds via Laminin 2 to the extracellular matrix [20,54] (Figure 3). The core skeletal muscle DGC also contains the sarcoglycans ( $\alpha$ -SG,  $\beta$ -SG,  $\delta$ -SG and  $\gamma$ -SG [50–51]), the sarcospan [55] and the syntrophins [56]. In addition, several extra- and intracellular proteins are less tightly associated with the DGC, such as nitric oxide synthase (nNOS) and dystrobrevin [54,57–59].

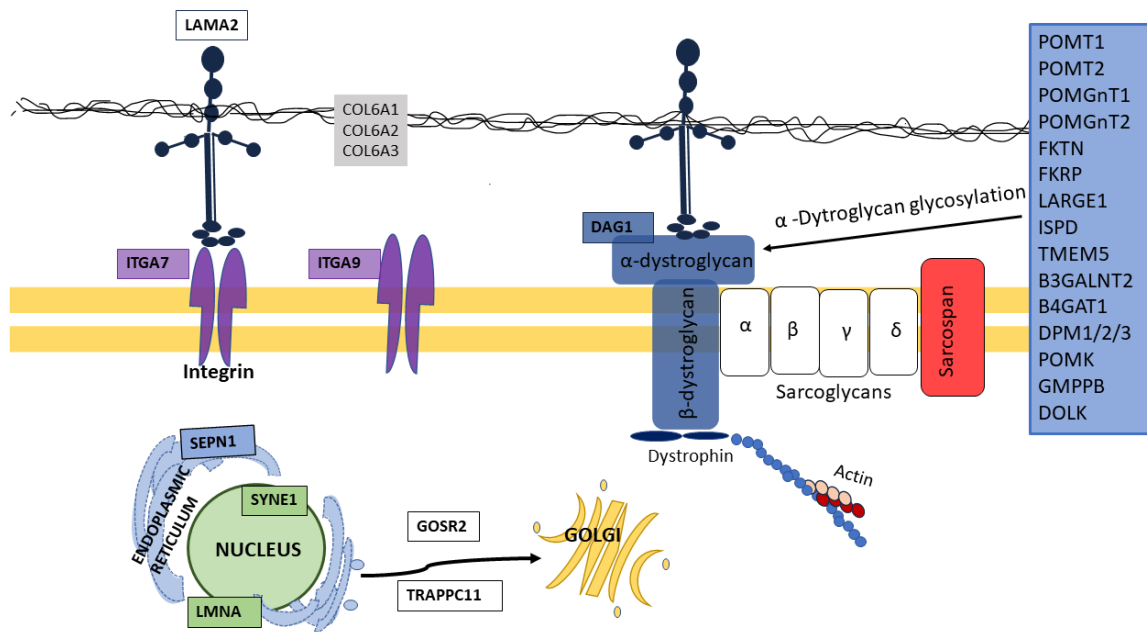
### Sugar Chain Structure of $\alpha$ -DG

$\alpha$ -DG has a mucin-type O-glycosylation site in the central region of the molecule and it contains more than 40 Ser/Thr residues that form an O-glycan cluster [53]. O-glycosylation is an even more complex process [60].  $\alpha$ -DG is heavily N- and O-glycosylated, as well as O-mannosylated [61–62]. The first 18 amino acids of the mucin-like domain have been shown to be important for this O-mannosylation of  $\alpha$ -DG to be carried

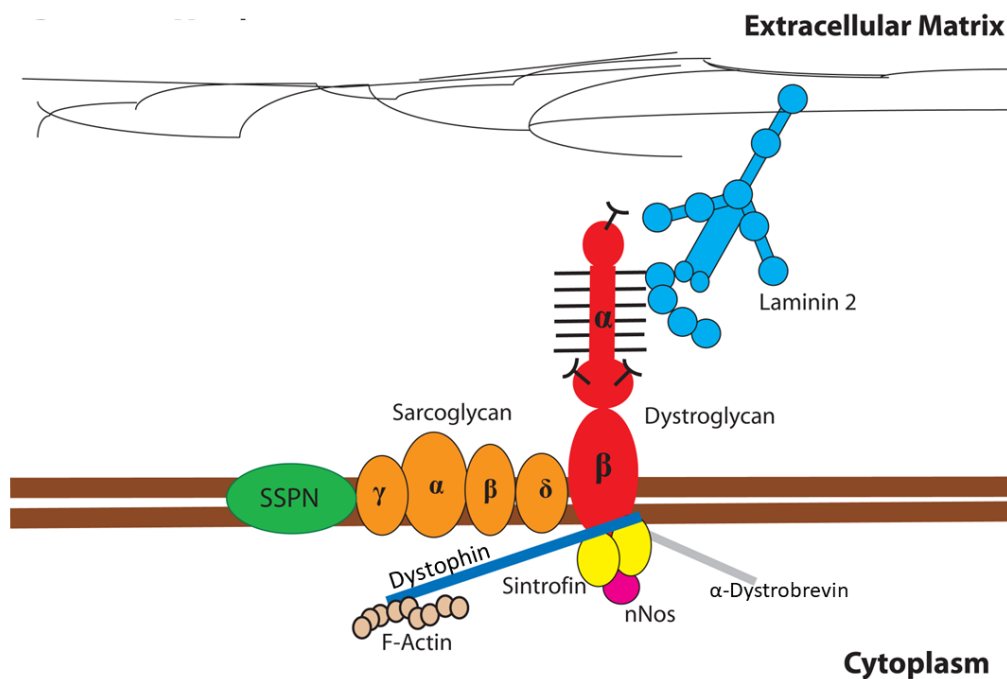
out correctly [21]. The sequential O-glycosylation process of  $\alpha$ -DG forms different structures called nuclei or Core (Core 1 to 3). Core 1 is crucial for the binding of the extracellular components [50].

### Core M1 and Core M2

The O-mannosylation initiates in the endoplasmic reticulum where POMT1 and POMT2 (O-mannosyl-transferases) form a complex that transfer a O-Man in an alpha linkage to serine and threonine residues of  $\alpha$ -DG [63]. POMT1-POMT2 complex uses dolichol phosphate mannose (Dol-P-Man) as a donor substrate. The synthesis of Dol-P-Man is carried out by GMPPB (GDP-mannose pyrophosphorylase), DPM1/2/3 (Dolichol-phosphate-mannose synthase), and DOLK (Dolichol Kinase) [43]. POMGnT1 acts in the Golgi, where it transfers  $\beta$ 2-linked GlcNAc residues to the mannose residues added by POMT1 and POMT2 during synthesis of the core M1 and M2 glycans [64]. Core M2 structure is found specifically in the brain [65].



**Figure 2.** Schematic representation of the Dystrophin glycoprotein complex (CDGP) in skeletal muscle. The two dystroglycan subunits ( $\alpha$ -DG and  $\beta$ -DG) interact non-covalently to form a bridge between the extracellular matrix and the actin cytoskeleton. The cytosolic domain of  $\beta$ -DG is anchored to actin through interaction with dystrophin.  $\alpha$ -DG interacts with the ectodomain of  $\beta$ -DG on the extracellular side of the plasma membrane. DG acts as a receptor for extracellular matrix proteins such as laminins. Adapted from Brancaccio 2019.



**Figure 3.** Scheme of genes implicated in CMDs and their localization in skeletal muscle cell. Adapted from Zamboni and Mutoni 2021. LAMA2, Laminin-2 protein; COL6A1, COL6A2 and COL6A3,  $\alpha$ -chains of Callagen VI monomers and tetramers; ITGA7, integrin  $\alpha$ -7; ITGA9, integrin  $\alpha$ -9; SEP1, Selenoprotein 1; SYNE1, Spectrin Repeat Containing Nuclear Envelope Protein 1; LMNA, Laminin a/c; TRAPPC11, Transport protein particle 11; GOSR2, Golgi SNAP receptor complex 2; DAG1, Dystroglycan; POMT1, Protein O-mannosyl-transferase 1; POMT2, Protein O-mannosyl-transferase 2; POMGNT1, Protein O-mannose  $\beta$ 1,2-N-acetylglucosaminyltransferase 1; POMGNT2, Protein O-mannose  $\beta$ 1,4-N-acetylglucosaminyltransferase 2; TMEM5, transmembrane protein 5; RXYLT1, ribitol-5-phosphate xylosyltransferase 1; B4GAT1,  $\beta$ 1,4-glucuronyltransferase; B3GALNT2,  $\beta$ 1,3-N-acetylgalactosaminyltransferase; POMK, Protein O-mannose Kinase; FKTN, Fukutin; FKRP, Fukutin related protein; LARGE1, like-acetylglucosaminyltransferase/LARGE xylosyl- and glucuronyltransferase 1; ISPD, isoprenoid synthase domain-containing protein; CDP-ribitylpyrophosphorylase A.

### Core M3 and Matriglycan Importance

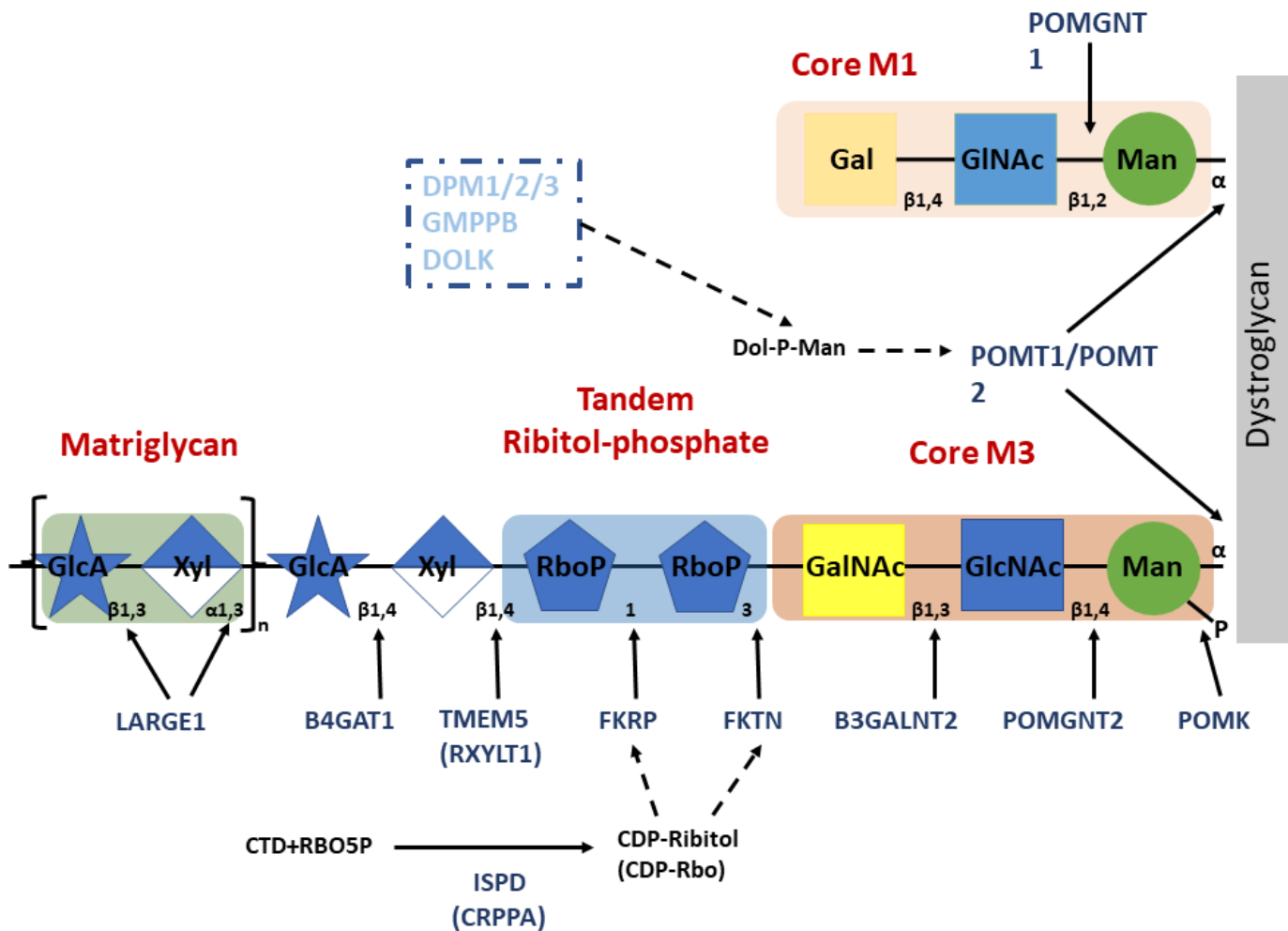
A small subset of O-Man modified sites, apparently exclusively on  $\alpha$ -DG, are extended in the endoplasmic reticulum by a GlcNAc in a beta-1,4 linkage by POMGNT2 to generate the Core M3 glycans [49]. This is further elaborated into a trisaccharide by the action of a beta-1,3-N-acetylgalactosamine (GalNAc) transferase, B3GALNT2 [53,66]. Core M3 has a phosphorylation at the C6 position of O-mannose, being POMK [67] the one that transfers a phosphate group from adenosine 5'-triphosphate (ATP), forming the phospho-nucleus structure [68].

The  $\beta$ 1,4 branch is subsequently modified by a series of Golgi enzymes [69] that include B3GALNT2 ( $\beta$ 1,3-N-acetylgalactosaminyl transferase), the ribitol transferases FKTN (Fukutin) and FKR (Fukutin-related protein), TMEM5 (Ribitol-

5-phosphate xylosyltransferase), and B4GAT1 ( $\beta$ 1,4-glucuronic acid transferase). Finally, the LARGE1 lengthens the previous linear carbohydrate branch by synthesizing a unique repeating disaccharide structure [ $-3$ -xylose- $\alpha$ 1,3-glucuronic acid- $\beta$ 1-] $_n$ , called matriglycan [53] (Figure 4). This complex mediates  $\alpha$ -DG interactions with LG domains of extracellular matrix (ECM) proteins such as laminins, agrin and perlecan and pikachurin [50–51,70].

This unique heteropolysaccharide is expressed in most tissues and it plays diverse roles, from acting as viral receptor to neuronal development [71–76].

Multiple studies, carried out in cultured cells and mouse skeletal muscles, have demonstrated that forced expression of LARGE increases the MW of  $\alpha$ -DG and its binding ability to LG domains [77–78].



**Figure 4.** Representation of the sequence of genes involved in the O-Glycosylation of  $\alpha$ -DG and matriglycan formation. Man, mannose; GlcNAc, N-acetylglucosamine; GalNAc, N-acetylgalactosamine; RboP, ribitol phosphate; Xyl, xylose; GlcA, glucuronic acid; Gal, galactose; Rbo5P, ribitol-5-phosphate; POMT1, Protein O-mannosyl-transferase 1; POMT2, Protein O-mannosyl-transferase 2; POMGNT1, Protein O-mannose  $\beta$ 1,2-N-acetylglucosaminyltransferase 1; POMGNT2, Protein O-mannose  $\beta$ 1,4-N-acetylglucosaminyltransferase 2; TMEM 5, transmembrane protein 5; RXYL1, ribitol-5-phosphate xylosyltransferase 1; B4GAT1,  $\beta$ 1,4-glucuronyltransferase; B3GALNT2,  $\beta$ 1,3-N-acetylgalactosaminyltransferase; POMK, Protein O-mannose Kinase; FKTN, Fukutin; FKRP, Fukutin related protein; LARGE1, like-acetylglucosaminyltransferase/LARGE xylosyl- and glucuronyltransferase 1; ISPD, isoprenoid synthase domain-containing protein; CDP-ribitylpyrophosphorylase A.

LARGE is a type II transmembrane protein that contains two distinct domains: one with homology to  $\beta$ 3GNT1, and another with homology to proteins belonging to glycosyltransferase family 8. LARGE has two glycosyltransferase activities: a  $\alpha$ 3-xylosyltransferase activity and a  $\beta$ 3-glucuronyltransferase activity. The LARGE paralog, LARGE2, possesses the same enzymatic function, although its optimal pH and pattern of expression differ from those of LARGE [79–80].

## Dystroglycanopathies & Congenital Disorders of Glycosylation

Congenital Disorders of Glycosylation (CDG) are a group of rare inborn errors of metabolism and include some forms of dystroglycanopathies [60].

These disorders (CDG) are genetic diseases caused by deficient glycoprotein and glycolipid glycan synthesis and attachment [81–82]. Most are multisystem disorders with variable phenotype severity and neurological involvement. CMDs due to CDG are clinically and genetically heterogeneous diseases and present progressive muscle weakness and loss of motor functions [1–2]. These present a stereotyped phenotype with early-onset muscle deficit with or without central nervous system involvement [83–85].

The glycosylation is a complex biological process involving many pathways. CDG are sub-grouped into defects of protein N-glycosylation, protein O-glycosylation, lipid glycosylation, GDP-anchor glycosylation and multiple glycosylation defects [81,86]. O-glycosylation is a common covalent modification of serine and threonine residues of mammalian glycoproteins [53].

Many of the described mutations for muscular dystrophy affect the O-glycosylation pathways for the biosynthesis of  $\alpha$ -dystroglycan. It has been described that new types of CDG result in defects in the O-mannosyl glycosylation pathway [87–92].

The multitude of clinical phenotypes resulting from defective O-mannosylation highlights the biomedical significance of this unique modification [47,93]. The understanding of this modification is important for the development of novel therapeutics [91,94–96].

Elucidation of the molecular pathological mechanisms of CDG associated with DG glycosylation abnormalities will be an important issue in understanding the mechanisms of dystroglycanopathies. Characterizing a glycoproteome profile of patients prior to and on treatment will help to better understand the changes of a plethora of glycoproteins and related clinical observations in dystroglycanopathies [81–82,86,97].

### Phenotypes Resulting from Defects in $\alpha$ -Dg Glycosylation

When the enzymes that participate in the O-glycosylation pathway of the  $\alpha$ -DG subunit show failures [98–99] or a

pathogenic variant is observed in *DAG1* gene, a decrease in the binding capacity of  $\alpha$ -DG to the other proteins of the CDGP complex is observed, including in laminin. This generates a severe clinical phenotype of muscular dystrophy, brain abnormalities, and often optic abnormalities. DMCs such as Walker-Warburg Syndrome (WWS), Muscle-Eye-Brain disease (SEM) and Fukuyama Congenital Muscular Dystrophy (FC-CMD) [100] are assumed to be  $\alpha$ -dystroglycanopathies. They all present a severe degree of muscular dystrophy with deterioration in the muscles, brain, and eye, and they have overlapping phenotypes that make their specific diagnosis difficult.

Dystroglycanopathies present a broad phenotypic spectrum that can even overlap, making diagnosis difficult. This is probably because of mutations involving the functions of gene products (enzyme activity), rather than variation in the causative genes [43]. In addition to the changes in the *DAG1* gene, changes in the enzymes involved in the glycosylation of  $\alpha$ -DG must be considered. Moreover, it is important not to forget the effect of variations in genes (such as *ISPD* or *GMPPB*) and their corresponding enzymes responsible for the manufacture of carbohydrate building blocks in the cytosol, indirectly modifying  $\alpha$ -DG glycosylation [20,24,91,101].

There is a clinical-radiological imaging technology classification that divides dystroglycanopathies into seven groups, including CMDs and limb girdle dystrophies [22,102–103,106].

1. Walker-Warburg Syndrome (WWS): onset prenatally or at birth. With eye abnormalities and severe structural brain abnormalities, including complete agyria or severe lissencephaly with only rudimentary cortical folding, it marked hydrocephalus, severe cerebellar involvement and complete or partial absence of the corpus callosum. Patients assigned to this category are incompatible with life or have very limited survival.
2. CMDs muscle-eye-brain/Fukuyama (MEB/CMD-FC) type: multiple malformations of the CNS (brain, cerebellum, or trunk) of less severity than the previous group.
3. CMDs with mental retardation and localized structural CNS involvement (CRB-CMD).
4. CMDs with intellectual disability and without CNS morphological abnormality (MR-CMD), possible microcephaly and/or moderate involvement of the cerebral white matter.
5. CMDs without intellectual disability (no MR-CMD): this category includes CMD-1C.
6. Girdle dystrophies with intellectual disability (LGMD-MR). It may include microcephaly and/or moderate brain and white matter abnormalities.
7. Limb Girdle muscular dystrophies without intellectual impairment (LGMD-not MR). It includes LGMD2I (FKRP), 2L (ISPD [107–112]) and 2M (FKTN).



### Walker-Warburg Syndrome: WWS

It is the most severe phenotype, and clinical manifestations appear early and can be detected in the prenatal stage by imaging techniques [113]. The clinical manifestations include congenital muscular dystrophy, brain, and eye anomalies: hydrocephalus, abnormal migration, retinal dysplasia and encephalocele [45,114]. The eye anomalies involve both anterior and posterior chambers with retinal detachment and blindness. Microphthalmia, thalamus, optic nerve hypoplasia, colobomas and iris malformation, cataract, and cornea defects may also be found. Mutations in B3GLNT2, B4GAT1, DAG1, FKRP, FKTN, GMPPB, ISPD, or LARGE are associated to Walker-Warburg Syndrome with brain and eye abnormalities [48]. The clinical features may also be associated, even if not frequently, to facial dysmorphism and cleft lip or palate [19]. It has been shown that mutations in POMT1 [115], FKTN, FKRP [116] and B3GALNT2 [117–118] can each give rise to the clinical WWS phenotype, even this phenotype should also be suspected when mutations in POMGnT1 and LARGE1 [45] are present [119]. The most common known causes of WWS are mutations in glycosyltransferases protein O-mannosyltransferase 1 and 2 (POMT1 and POMT2 [120]) [45,63,121]; these mutations have been observed in a few patients [114,122].

### Muscle-Eye-Brain Syndrome: MEB

This disease is characterized by structural ophthalmological abnormalities and brain malformation. It was first reported in Finnish patients with poor psychomotor development, hypotonia and loss of reflexes at the age of 1 [123]. Patients are unable to sit still and they have seizures, and high levels of CK are detected [124].

Ophthalmologic abnormalities are very common. The EMG usually shows myopia, corneal opacity, cataracts and dysgenesis of the anterior chamber, congenital glaucoma, hypoplastic choroid and optic atrophy, among other alterations. Brain malformations such as argyric hemispheres, polymicrogyria in various cortical segments, and severe cortical disorganization are observed on MRI [125–127]. Muscle Eye Brain disease involves genetic mutations in B3GLNT2, B4GAT1, DAG1, FKRP, FKTN, GMPPB, ISPD, or LARGE. There are frequent mutations [103–106,128–129] in genes that have been associated with this pathology [116,130].

### CMD Fukuyama (CMD-F)

This pathology is caused by mutations in the FKTN [131] gene. This disease is highly prevalent in Japan, where the founder mutation was detected, a 3 kb insertion in 3'UTR [127], although there are others associated with this phenotype. This homozygous mutation is present in 80% of patients [131]. Other mutations in non-Japanese patients have been detected and involve a loss of localization in the Golgi or missense mutations [132–133].

Some mutations involve total or partial loss of function. This depends on how involved it is its glycosyltransferase enzymatic domain, which is essential in the binding of the first Rob 5 to the M3 core of  $\alpha$ -DG [93].

This phenotype is characterized by the appearance of congenital muscle weakness, severe mental retardation and delayed motor development with severe epilepsy associated with significant muscle involvement of the facial muscles and marked hypotonia in the extremities [134].

### Muscular Dystrophy 1C (CMD-1C)

This subtype of CMD was first reported by Brockington *et al*, who identified a new member of the fukutin family of proteins, FKRP [135–136]. The clinical manifestations appear in the first weeks of life with a pronounced increase in CK. Some patients present normal brain structure, cardiac anomalies and respiratory failure, severe weakness in the muscles of the shoulder girdle, calves, and thighs in young age with null ambulation [19].

Although there is a decrease in  $\alpha$ -DG levels, there would be a mechanism by which this deficiency would be compensated in the brain, so there is no significant impact on the CNS, although there would be a subgroup that would present neurological abnormalities resulting from mutations in FKRP [19].

### Muscular Dystrophy 1D (CMD-1D)

It is caused by mutations in the LARGE1 gene [137–138], which encodes the enzyme acetyl-glucosaminyl transferase. In this pathology, there is profound mental retardation and sometimes retinopathy [19,77]. The first human mutation reported for LARGE1 gave rise to the new classification of (DMC-1D) [19]. It was reported in a 17-year-old girl with congenital muscular dystrophy, profound mental retardation, white matter changes, and very subtle structural abnormalities on MRI of the brain. A significant reduction in  $\alpha$ -DG was observed at biopsy [139]. A missense mutation (c.G1525A) and a 1 bp insert (c.1999insT) in the human LARGE1 gene homologous to mouse LARGE were described in this patient [48,139–140].

### Limb Girdle Muscular Dystrophy LGMD2I

It is caused by mutations in the FKRP gene [141], which also implies a secondary deficit of  $\alpha$ -DG and merosin [139]. In patients with LGMD2I, symptoms appear between the ages of 6 and 13 [142]. Frequent muscular pseudohypertrophy (calves, tongue) is observed. There are cases of severe respiratory failure that can precede loss of gait with an elevated risk of cardiomyopathy. Near half of the patients develop weakness in the ventricles [143].

In Table 3 we list some disease-causing variants associated to phenotypes more frequent to dystroglycanopathies.

**Table 3.** DISEASE-CAUSING VARIANTS associated to dystroglycanopathies Phenotypes. These variants are interpreted as pathogenic in ClinVar (Genomic variation as it relates to human health). NM\_ correspond to NCBI Reference Sequence used in the construction of this table.

Gene	Phenotype	Disease-causing variants	Reference
DAG1 NM_004393.6	WWS MEB CMD-1C CMD-1D	c.15G>A (p.Val5=); c.41C>A(p.Ser14Ter); c.235C>T (p.Arg79Ter); c.285+1G>A c.330G>A (p.Trp110Ter); c.440del(p.Gln147fs); c.454_467del (p.Phe152fs) c.556G>T (p.Glu186Ter) c.721_722del (p.Phe241fs) c.743del (p.Ala248fs) c.839del (p.Pro280fs)	[164] [165] [166] [167]
POMT2 NM_013382.7	WWS CMD-MR LGMD 2N	c.49_50delinsA (p.Arg18fs) c.248+1G>C; c.248+2T>C; c.248+5G>C c.311A>T (p.Asp104Val) c.431T>G (p.Met144Arg) c.462G>A (p.Trp154Ter) c.648C>A (p.Cys216Ter) c.673del (p.Trp225fs) c.678del (p.Trp226fs) c.737G>A (p.Gly246Asp) c.791del (p.Leu264fs) c.879_880del (p.Thr295fs) c.881A>G (p.Tyr294Cys) c.924-2A>C; c.958C>T (p.Gln320Ter) c.1006+1G>A c.1034_1035del (p.Val345fs) c.1117G>T (p.Val373Phe) c.1123_1124dup (p.Tyr376fs) c.1237C>T (p.Arg413Ter) c.1253+1G>A c.1261del (p.Arg421fs) c.1261C>T (p.Arg421Trp) c.1293dup (p.Met432fs) c.1300del (p.Arg434fs) c.1417C>T (p.Arg473Ter) c.1445G>T (p.Gly482Val) c.1555G>T (p.Glu519Ter) c.1577-5_1577-1delinsTGA c.1912C>T (p.Arg638Ter) c.1941G>A (p.Trp647Ter) c.1997A>G (p.Tyr666Cys) c.2177G>A (p.Gly726Glu)	[120] [168] [169] [170] [171] [172] [173] [174] [175]

**Table 3.** Cont.

Gene	Phenotype	Disease-causing variants	Reference
POMT1 NM_001077365.2	WWS LGMD	c.58dup (p.Val20fs)	
		c.72del (p.Met25fs)	
		c.97C>T (p.Arg33Ter)	
		c.130G>A (p.Glu44Lys)	
		c.193G>A (p.Gly65Arg)	
		c.264G>A (p.Trp88Ter)	
		c.270_280delAATTGGAGCAG (p.Gly92fs)	
		c.280+1G>T	
		c.414del (p.Leu138_Leu139insTer)	
		c.418_420del (p.Met140del)	
		c.430A>G (p.Asn144Asp)	
		c.443C>A (p.Thr148Asn)	
		c.579_580del (p.Val195fs)	
		c.598G>C (p.Ala200Pro)	
		c.606del (p.Ile203fs)	
		c.699+62del; c.699+67G>A	
		c.841C>T (p.Gln281Ter)	
		c.859_871del (p.Gly287fs)	
		c.978C>A (p.Tyr326Ter)	[22]
		c.990T>A (p.Tyr330Ter)	[45]
		c.1087C>T (p.Gln363Ter)	[60]
		c.1091del (p.Leu364fs)	[96]
		c.1093_1094insGGAGCACGGTGTGGAACGTGGG (p.Val365fs)	[97]
		c.1175C>T (p.Thr392Met)	[104]
		c.1175+3del	[112]
		c.1195_1196del (p.Leu399fs)	[116]
		c.1204dup (p.His402fs)	[98]
		c.1272+1G>A	
		c.1361T>G (p.Leu454Ter)	
		c.1364del (p.Lys455fs)	
		c.1391G>C (p.Trp464Ser)	
		c.1417G>C (p.Gly473Arg)	
		c.1457G>A (p.Trp486Ter)	
c.1474C>T (p.Arg492Ter)			
c.1671del (p.Ile557fs)			
c.1680G>C (p.Trp560Cys)			
c.1798C>T (p.Arg600Ter)			
c.1837_1852dup (p.Gly618fs)			
c.1892C>T (p.Pro631Leu)			
c.1921C>T (p.Leu641Phe)			
c.1939G>A (p.Ala647Thr)			
c.2097C>A (p.Tyr699Ter)			
c.2101dup (p.Asp701fs)			
c.2144_2147dup (p.Asp716fs)			

Table 3. Cont.

Gene	Phenotype	Disease-causing variants	Reference
POMGNT1 NM_017739.4	MEB LGMD	c.187C>T (p.Arg63Ter) c.593del (p.Ser198fs) c.595C>T (p.Gln199Ter) c.643C>T (p.Arg215Ter) c.931C>T (p.Arg311Ter) c.932G>A (p.Arg311Gln) c.1282C>T (p.Gln428Ter) c.1324C>T (p.Arg442Cys) c.1325G>A (p.Arg442His) c.1350_1354del (p.Trp451fs) c.1469G>A (p.Cys490Tyr) c.1478C>G (p.Pro493Arg) c.1694_1695del (p.Ser565fs) c.1738C>T (p.Arg580Ter) c.1769G>A (p.Trp590Ter) c.1719del (p.His573fs) c.1814G>A (p.Arg605His) c.1832del (p.Leu611fs) c.1895+1G>A c.1895C>G (p.Ser632Ter) c.1876del (p.Val626fs)	[47] [102] [103] [104] [105] [106] [128]
POMGNT2 NM_032806.6	LGMD	c.118C>T (p.Arg40Ter) c.410_411delinsG (p.Ala137fs) c.494T>C (p.Met165Thr) c.503T>C (p.Phe168Ser) c.509del (p.Asp170fs) c.590G>A (p.Trp197Ter) c.745C>T (p.Gln249Ter) c.758C>T (p.Pro253Leu) c.820_821del (p.Lys274fs) c.1000_1003del (p.Leu334fs) c.1232_1233del (p.Gln411fs) c.1333C>T (p.Arg445Ter) c.494T>C; c.758C>T	[94] [167] [168]
B3GALNT2 NM_152490.5	WWS MEB LGMD	c.51_73dup (p.Ser25fs) c.199C>T (p.Arg67Ter) c.308_309del (p.Val103fs) c.448C>T (p.Arg150Ter) c.753del (p.Val252fs) c.755T>G (p.Val252Gly) c.824_825dup (p.Ile276fs) c.875G>C (p.Arg292Pro) c.1066_1067del (p.Thr355_Asp356insTer) c.1423C>T (p.Gln475Ter)	[178] [117] [179] [180] [181] [118]

**Table 3.** Cont.

Gene	Phenotype	Disease-causing variants	Reference
POMK NM_032237.5	WWS LGMD	c.10C>T (p.Gln4Ter) c.43dup (p.Arg15fs) c.152del (p.Asp51fs) c.238_239del (p.Glu80fs) c.288del (p.Leu97fs) c.325C>T (p.Gln109Ter) c.386_387del (p.Leu129fs) c.410T>G (p.Leu137Arg) c.452_455dup (p.His152fs) c.907C>T (p.Arg303Ter) c.917dup (p.Leu306fs)	[67] [182] [183] [184]
Fukutin (FKTN) NM_001079802.2	WWS CMD-F	c.42del (p.Thr14_Leu15insTer) c.78C>G (p.Tyr26Ter) c.93T>A (p.Tyr31Ter) c.139C>T (p.Arg47Ter) c.180dup (p.Phe61fs) c.187_188del (p.Met63fs) c.330dup (p.Thr111fs) c.346C>T (p.Gln116Ter) c.369+1G>C c.369+1G>T c.411C>A (p.Cys137Ter) c.454dup (p.Ser152fs) c.456_457del (p.Ser154fs) c.509C>A (p.Ala170Glu) c.527T>C (p.Phe176Ser) c.585dup (p.Asp196Ter) c.607C>T (p.Arg203Ter) c.642dup (p.Asp215Ter) c.648-1243G>T c.658C>T (p.Gln220Ter) c.756T>A (p.Tyr252Ter) c.766C>T (p.Arg256Ter) c.868A>T (p.Lys290Ter) c.914G>A (p.Trp305Ter) c.919C>T (p.Arg307Ter) c.920G>A (p.Arg307Gln) c.942T>G (p.Tyr314Ter) c.1022del (p.Pro341fs) c.1099del (p.Val367fs) c.1106del (p.Phe369fs) c.1167_1168dup (p.Phe390fs) c.1317_1318dup (p.Pro440fs) c.1363del (p.Asp455fs) c.5374_5846del	[45] [131] [93] [134] [132] [133]

Table 3. Cont.

Gene	Phenotype	Disease-causing variants	Reference
FKRP NM_024301.5	WWS MEB CMD-1C LGMD 2I	c.77G>A (p.Trp26Ter)	
		c.151G>T (p.Val51Phe)	
ISPD(CRPPA) NM_001101426.4	LGMD WWS	c.158_162dup (p.Glu55fs)	
		c.162_165dup (p.Phe56fs)	
		c.224del (p.Pro75fs)	
		c.266C>T (p.Pro89Leu)	
		c.313C>T (p.Gln105Ter)	
		c.511_523del (p.Leu171fs)	
		c.515dup (p.Asn172fs)	
		c.526C>T (p.Arg176Ter)	[22]
		c.540_570dup (p.Cys191fs)	[45]
		c.650dup (p.Val218fs)	[69]
		c.826C>A (p.Leu276Ile)	[141]
		c.919del (p.Tyr307fs)	[116]
		c.919T>A (p.Tyr307Asn)	[185]
		c.928G>T (p.Glu310Ter)	[127]
		c.939G>A (p.Trp313Ter)	[143]
		c.948del (p.Cys317fs)	[144]
		c.970G>T (p.Glu324Ter)	
		c.1075del (p.Trp359fs)	
		c.1077_1078dup (p.Asp360fs)	
		c.1154C>A (p.Ser385Ter)	
c.1170_1171del (p.Gly391fs)			
c.1213G>T (p.Val405Leu)			
c.1256_1257del (p.Pro419fs)			
c.1335_1336del (p.Leu446fs)			
c.1387A>G (p.Asn463Asp)			
c.1394A>C (p.Tyr465Ser)			
TMEM5/ RXYLT1 NM_014254.3	Cobblestone Lissencephaly	c.258-2A>G	
		c.364G>C (p.Ala122Pro)	
		c.466G>A (p.Asp156Asn)	
		c.550C>T (p.Arg184Ter)	
		c.638T>G (p.Met213Arg)	[107]
		c.643C>T (p.Gln215Ter)	[122]
		c.647C>A (p.Ala216Asp)	[108]
		c.704_705del (p.Glu235fs)	[110]
		c.773C>A (p.Ser258Ter)	[111]
		c.789+2T>G	[112]
		c.802C>T (p.Arg268Ter)	[109]
		c.835+2T>C	
		c.(534+1_535-1)_(933+1_934-1)del	
		c.1120-1G>T	
c.1123_1126del (p.His375fs)			
c.1354T>A (p.Ter452Arg)			
B4GAT1 NM_006876.3 NM_006876.2	WWS	c.169+2T>C	
		c.279del (p.Gly94fs)	
		c.429-2A>G	[154]
		c.649del (p.Arg217fs)	[186]
		c.795del (p.Arg266fs)	[187]
		c.1018C>T (p.Arg340Ter)	
c.1064_1091del (p.Asp355fs)			
B4GAT1 NM_006876.3 NM_006876.2	WWS	c.1207G>T (p.Glu403Ter)	
		c.1168A>G;	[188]
		c.1217C>T	[189]
		c.864T>A (p.Tyr288Ter)	
c.821_822insTT (p.Glu274fs)			

**Table 3.** Cont.

Gene	Phenotype	Disease-causing variants	Reference
LARGE1 NM_133642.5	WWS MEB CMD-1D	c.265C>T (p.Arg89Ter) c.283C>T (p.Arg95Ter) c.334G>T (p.Glu112Ter) c.620_621del (p.Glu207fs) c.871del (p.Gly292fs) c.992C>T (p.Ser331Phe) c.1102C>T (p.Gln368Ter) c.1209del (p.Phe404fs) c.1483T>C (p.Trp495Arg) c.1525G>A (p.Glu509Lys) c.1699del (p.Leu567fs) c.1811del (p.Leu604fs) c.1999dup (p.Cys667fs) c.2089G>T (p.Val697Leu)	[129] [148] [149] [138] [137] [130]
GMPPB NM_021971.4	LGMD	c.395C>G (p.S132C) c.64C>T (p.Pro22Ser) c.79G>C (p.D27H) c.94C>T (p.P32S) c.109C>T (p.Gln37Ter) c.220C>T (p.Arg74Ter) c.271_283del (p.Ala91fs) c.294dup (p.Glu99Ter) c.365_366dup (p.Phe123fs) c.458_459del (p.Thr153fs) c.458C>T (p.Thr153Ile) c.553C>T (p.Arg185Cys) c.611_614del (p.Glu204fs) c.640+1G>A c.656T>C (p.Ile219Thr) c.721C>T (p.P241S); c.728_746delinsACAGA (p.Arg243fs) c.790C>T (p.Gln264Ter) c.859C>T (p.Arg287Trp) c.1034T>C (p.V345A)	[190] [191] [192]

## Therapeutic Considerations

Dystroglycanopathies are very heterogeneous diseases at a clinical and genetic level in which numerous genes are involved. Phenotypic identification and genetic characterization have made it possible to advance in the development of innovative therapies, currently in the preclinical phases, which could be implemented in the coming years [81]. Gene therapy is considered a simple treatment strategy. But the expression of glycosyltransferases may also be strictly controlled, and it must consider the glycosylation status in muscle progenitor cells and changes during differentiation.

### Gene Therapy

Several preclinical studies have investigated the use of recombinant adeno-associated virus (AAV) to deliver functional FKRP, as well as other genes involved in glycosylation, such as LARGE1 and Beta-1,4 N-acetylgalactosaminyltransferase 2 (B4GALNT2 previously GALGT2) [144–145].

The use of CRISPR-Cas9 technology in combination with patient-specific iPS cells for the future development of autologous cell transplantation for FKRP has a big potential, because this

approach uses functional  $\alpha$ -DG( $\alpha$ -DG) glycosylation in gene-edited WWS iPS cell-derived myotubes [146].

The expression of B4GALNT2 was shown to have a therapeutic effect on various types of muscular dystrophy models, such as dystrophin-deficient and laminin deficient mice [147].

Overexpression of the LARGE gene increases matriglycan modification and enhances laminin-binding activity [80,119,129]. LARGE1 gene therapy has called attention as a treatment method that does not depend on the type of causative gene [43,148–149].

### Pharmacological Therapy

Corticosteroids are anti-inflammatory drugs used as palliatives in Duchenne muscular dystrophy (DMD), as they improve muscle strength and function. Bisphosphonates prevent loss of bone density [150]. Its combined use in FKRP mouse models has been shown to achieve a decrease in muscle degeneration. The use of selective estrogen receptor modulators, tamoxifen and raloxifene, have shown to inhibit fibrosis and improve muscle strength and respiratory function [151]. Using zebrafish as a model, it has been shown that pentonic acid can rescue dystrophic pathology in DMD models [144].

The effect of coenzyme nicotinamide adenine dinucleotide (NAD<sup>+</sup>) was tested in FKRP zebrafish morphants. The study reported decreased muscle degeneration and improved muscle organization and function when treatment occurred at gastrulation [152].

Many FCMD patients have a transposon insertion in the fukutin gene [127] that results in abnormal splicing of fukutin [153]. Administration of antisense nucleotides capable of correcting this splicing abnormality restores the normal function of fukutin in both fukutin KI mice and human patient-derived cells [43].

### Ribitol Supplementation Therapy

Defects in the pathway for the incorporation of ribitol 5-phosphate into Core 3 of  $\alpha$ -DG, which is carried out by or in the FCMD, FKRP and ISPD genes, bring together different pathologies associated with DMC [145]. Previous studies demonstrated that CDP-Rbo supplementation rescued the compromised O-glycosylation enzymatic pathway in an ISPD deficient cell line [154–155]. Ribitol supplementation [156–157], gene therapy targeting the LARGE1 gene [148], and the use of clinical-grade induced pluripotent cells (iPSCs) [158] appear to be promising experimental models for studying the pathogenesis of  $\alpha$ -dystroglycanopathies and for testing potential drugs or break throughs in the development of autologous therapies [155,159–160]. The application of the generation of embryoid bodies from human induced pluripotent stem cells that model the basal lamina to evaluate an experimental ribitol supplement therapy has been reported [161,176–177].

### Cell Therapy

Since skeletal muscle is a highly regenerative tissue, cell-based therapeutic approaches focusing on the delivery of muscle stem cells/early progenitor cells to replace diseased muscle tissue with healthy myofibers and satellite cells are highly attractive. To date, two studies have been reported on the use of cell transplantation for FKRP-associated dystroglycanopathies [162–163].

### Conclusions

The knowledge acquired about the dystroglycanopathies in recent years was of great importance. The elucidation of the genes involved in the formation of sugar chain structure of  $\alpha$ -DG allowed opening steps to new research and new alternative therapies.

It will be the joint effort of different fields of biology that will enable us to assume research and strategies that will allow us to implement effective therapies and precise diagnoses for these pathologies.

### Acknowledgments

This work was supported by CONICET, PID Clinico 2018-0019 and Catholic University of Cordoba. The authors kindly acknowledge the Reviewers and Editors for their contributions.

### Declaration of Conflicting Interests

The author declared no potential conflicts of interest with respect to the research, authorship, and/or publication of this article.

### References

1. Quijano-Roy S, de la Banda MG-G. Distrofias musculares congénitas. *Rev Médica Clínica Las Condes*. 2018;29(5):530-543. doi:10.1016/j.rmcl.2018.08.002.
2. Butterfield RJ. Congenital muscular dystrophy and congenital myopathy. *Contin Lifelong Learn Neurol*. 2019;25(6):1640-1661. doi:10.1212/CON.0000000000000792.
3. Harmelink M. Differentiating congenital myopathy from congenital muscular dystrophy. *Clin Perinatol*. 2020;47(1):197-209. doi:10.1016/j.clp.2019.10.005.
4. Zambon AA, Muntoni F. Congenital muscular dystrophies: What is new? *Neuromuscul Disord*. 2021;31(10):931-942. doi:10.1016/j.nmd.2021.07.009.
5. Kim HJ, Choi YC, Park HJ, et al. Congenital muscular dystrophy type 1A with residual merosin expression. *Korean J Pediatr*. 2014;57(3):149-152. doi:10.3349/kjp.2014.57.3.149.
6. Hayashi YK, Ishihara T, Domen K, Hori H, Arahata K. A benign allelic form of laminin alpha 2 chain deficient muscular dystrophy. *Lancet*. 1997;349(9059):1147. doi:10.1016/S0140-6736(05)63023-1.
7. Sarkozy A, Foley AR, Zambon AA, Bönnemann CG, Muntoni F. LAMA2-related dystrophies: Clinical phenotypes, disease biomarkers, and clinical trial readiness. *Front Mol Neurosci*. 2020;13:00123. doi:10.3389/fnmol.2020.00123.
8. Yurchenco PD, McKee KK, Reinhard JR, Rüegg MA. Laminin-deficient muscular dystrophy: Molecular pathogenesis and structural repair strategies. *Matrix Biol*. 2018;71-72:174-187. doi:10.1016/j.matbio.2017.11.009.
9. Zambon AA, Ridout D, Main M, et al. LAMA2-related muscular dystrophy: Natural history of a large pediatric cohort. *Ann Clin Transl Neurol*. 2020;7(10):1870-1882. doi:10.1002/acn3.51172.
10. Lampe AK, Flanigan KM, Bushby KM, Frpc M, Hicks D. Collagen type VI-related disorders summary genetic counseling. *GeneReview Scope*. 2019:1-22.



11. Dai Y, Liang S, Huang Y, Chen L, Banerjee S. Targeted next generation sequencing identifies two novel mutations in SEPNI in rigid spine muscular dystrophy 1. *Oncotarget*. 2016;7(51):83843-83849. doi:10.18632/oncotarget.13337.
12. Yonekawa T, Nishino I. Ullrich congenital muscular dystrophy: Clinicopathological features, natural history and pathomechanism(s). *J Neurol Neurosurg Psychiatry*. 2015;86(3):280-287. doi:10.1136/jnnp-2013-307052.
13. Xia W, Ni Z, Zhang Z, et al. Case Report: A Boy From a Consanguineous Family Diagnosed With Congenital Muscular Dystrophy Caused by Integrin Alpha 7 (ITGA7) Mutation. *Front Genet*. 2021;12:706823. doi:10.3389/fgene.2021.706823.
14. Esposito T, Sampaolo S, Limongelli G, et al. Digenic mutational inheritance of the integrin alpha 7 and the myosin heavy chain 7B genes causes congenital myopathy with left ventricular non-compact cardiomyopathy. *Orphanet J Rare Dis*. 2013;8:91. doi:10.1186/1750-1172-8-91.
15. Yu M, Zheng Y, Jin S, et al. Mutational spectrum of Chinese LGMD patients by targeted next-generation sequencing. *PLoS One*. 2017;12(4):e0175343. doi:10.1371/journal.pone.0175343.
16. Karaca E, Posey JE, Coban Akdemir Z, et al. Phenotypic expansion illuminates multilocus pathogenic variation. *Genet Med*. 2018;20(12):1528-1537. doi:10.1038/gim.2018.33.
17. Xu S, Zhang T, Cao Z, et al. Integrin- $\alpha 9\beta 1$  as a novel therapeutic target for refractory diseases: Recent progress and insights. *Front Immunol*. 2021;12:638400. doi:10.3389/fimmu.2021.638400.
18. Høye AM, Couchman JR, Wewer UM, Fukami K, Yoneda A. The newcomer in the integrin family: Integrin  $\alpha 9$  in biology and cancer. *Adv Biol Regul*. 2012;52(2):326-339. doi:10.1016/j.jbior.2012.03.004.
19. Falsaperla R, Praticò AD, Ruggieri M, et al. Congenital muscular dystrophy: From muscle to brain. *Ital J Pediatr*. 2016;42(1):78. doi:10.1186/s13052-016-0289-9.
20. Brancaccio A. A molecular overview of the primary dystroglycanopathies. *J Cell Mol Med*. 2019;23(5):3058-3062. doi:10.1111/jcmm.14218.
21. Hara Y, Balci-Hayta B, Yoshida-Moriguchi T, et al. A dystroglycan mutation associated with limb-girdle muscular dystrophy. *N Engl J Med*. 2011;364(10):939-946. doi:10.1056/NEJMoa1006939.
22. Geis T, Rödl T, Topaloglu H, et al. Clinical long-time course, novel mutations and genotype-phenotype correlation in a cohort of 27 families with POMT1-related disorders. *Orphanet J Rare Dis*. 2019;14(1):179. doi:10.1186/s13023-019-1119-0.
23. Taniguchi-Ikeda M, Morioka I, Iijima K, Toda T. Mechanistic aspects of the formation of  $\alpha$ -dystroglycan and therapeutic research for the treatment of  $\alpha$ -dystroglycanopathy: A review. *Mol Aspects Med*. 2016;51:115-124. doi:10.1016/j.mam.2016.07.003.
24. Larson AA, Baker PR, Milev MP, et al. TRAPPC11 and GOSR2 mutations associate with hypoglycosylation of  $\alpha$ -dystroglycan and muscular dystrophy. *Skelet Muscle*. 2018;8(1):17. doi:10.1186/s13395-018-0163-0.
25. Arbogast S, Ferreiro A. Selenoproteins and protection against oxidative stress: Selenoprotein N as a novel player at the crossroads of redox signaling and calcium homeostasis. *Antioxidants Redox Signal*. 2010;12(7):893-904. doi:10.1089/ars.2009.2890.
26. Filipe A, Chernorudskiy A, Arbogast S, et al. Defective endoplasmic reticulum-mitochondria contacts and bioenergetics in SEPNI-related myopathy. *Cell Death Differ*. 2021;28(1):123-138. doi:10.1038/s41418-020-0587-z.
27. Villar-Quiles RN, von der Hagen M, Métay C, et al. The clinical, histologic, and genotypic spectrum of SEPNI-related myopathy: A case series. *Neurology*. 2020;95(11):e1512-e1527. doi:10.1212/WNL.00000000000010327.
28. Broers JLV, Ramaekers FCS, Bonne G, Ben Yaou R, Hutchison CJ. Nuclear lamins: Laminopathies and their role in premature ageing. *Physiol Rev*. 2006;86(3):967-1008. doi:10.1152/physrev.00047.2005.
29. Owens DJ, Messéant J, Moog S, et al. Lamin-Related Congenital Muscular Dystrophy Alters Mechanical Signaling and Skeletal Muscle Growth. *Int J Mol Sci*. 2020;22(1):306. doi:10.3390/ijms22010306.
30. Azibani F, Brull A, Arandel L, et al. Gene therapy via trans-splicing for LMNA-related congenital muscular dystrophy. *Mol Ther - Nucleic Acids*. 2018;10:376-386. doi:10.1016/j.omtn.2017.12.012.
31. Ben Yaou R, Yun P, Dabaj I, et al. International retrospective natural history study of LMNA-related congenital muscular dystrophy. *Brain Commun*. 2021;3(3):fcab075. doi:10.1093/braincomms/fcab075.
32. Pillers DAM, Von Bergen NH. Emery-dreifuss muscular dystrophy: A test case for precision medicine. *Appl Clin Genet*. 2016;9:27-32. doi:10.2147/TACG.S75028.
33. Chen Z, Ren Z, Mei W, et al. A novel SYNE1 gene mutation in a Chinese family of Emery-Dreifuss muscular dystrophy-like. *BMC Med Genet*. 2017;18(1):4-9. doi:10.1186/s12881-017-0424-5.
34. Mastroianno S, Leone MP, Castellano S, et al. Emery-Dreifuss muscular dystrophy type 4: A new SYNE1 mutation associated with hypertrophic cardiomyopathy masked by a perinatal distress-related spastic diplegia. *Clin Case Reports*. 2019;7(5):1078-1082. doi:10.1002/ccr3.2140.

35. Zhang Q, Bethmann C, Worth NF, et al. Nesprin-1 and -2 are involved in the pathogenesis of Emery - Dreifuss muscular dystrophy and are critical for nuclear envelope integrity. *Hum Mol Genet.* 2007;16(23):2816-2833. doi:10.1093/hmg/ddm238.
36. Attali R, Warwar N, Israel A, et al. Mutation of SYNE-1, encoding an essential component of the nuclear lamina, is responsible for autosomal recessive arthrogryposis. *Hum Mol Genet.* 2009;18(18):3462-3469. doi:10.1093/hmg/ddp290.
37. Gros-Louis F, Dupré N, Dion P, et al. Mutations in SYNE1 lead to a newly discovered form of autosomal recessive cerebellar ataxia. *Nat Genet.* 2007;39(1):80-85. doi:10.1038/ng1927.
38. Matalonga L, Bravo M, Serra-Peinado C, et al. Mutations in TRAPPC11 are associated with a congenital disorder of glycosylation. *Hum Mutat.* 2017;38(2):148-151. doi:10.1002/humu.23145.
39. Corbett MA, Schwake M, Bahlo M, et al. A mutation in the Golgi Qb-SNARE gene GOSR2 causes progressive myoclonus epilepsy with early ataxia. *Am J Hum Genet.* 2011;88(5):657-663. doi:10.1016/j.ajhg.2011.04.011.
40. Prashberger R, Balint B, Mencacci NE, et al. Expanding the phenotype and genetic defects associated with the GOSR2 Gene. *Mov Disord Clin Pract.* 2015;2(3):271-273. doi:10.1002/mdc3.12190.
41. Henige H, Kaur S, Pappas K. Compound heterozygous variants in GOSR2 associated with congenital muscular dystrophy: A case report. *Eur J Med Genet.* 2021;64(4):104184. doi:10.1016/j.ejmg.2021.104184.
42. Fu XN, Xiong H. Genetic and clinical advances of congenital muscular dystrophy. *Chin Med J (Engl).* 2017;130(21):2624-2631. doi:10.4103/0366-6999.217091.
43. Kanagawa M. Dystroglycanopathy: From elucidation of molecular and pathological mechanisms to development of treatment methods. *Int J Mol Sci.* 2021;22(23):13162. doi:10.3390/ijms222313162.
44. Matsumoto H, Hayashi YK, Kim DS, et al. Congenital muscular dystrophy with glycosylation defects of  $\alpha$ -dystroglycan in Japan. *Neuromuscul Disord.* 2005;15(5):342-348. doi:10.1016/j.nmd.2005.01.009.
45. van Reeuwijk J, Brunner HG, van Bokhoven H. Glyco-O-genetics of Walker-Warburg syndrome. *Clin Genet.* 2005;67(4):281-289. doi:10.1111/j.1399-0004.2004.00368.x.
46. Bouchet C, Gonzales M, Vuillaumier-Barrot S, et al. Molecular heterogeneity in fetal forms of type II lissencephaly. *Hum Mutat.* 2007;28(10):1020-1027. doi:10.1002/humu.20561.
47. Uribe ML, Haro C, Ventero MP, Campello L, Cruces J, Martín-Nieto J. Expression pattern in retinal photoreceptors of POMGnT1, a protein involved in muscle-eye-brain disease. *Mol Vis.* 2016;22:658-673.
48. Francisco R, Pascoal C, Marques-da-Silva D, et al. Keeping an eye on congenital disorders of O-glycosylation: A systematic literature review. *J Inher Metab Dis.* 2018;42(1):29-48. doi:10.1002/jimd.12025.
49. Yoshida-Moriguchi T, Campbell KP. Matriglycan: A novel polysaccharide that links dystroglycan to the basement membrane. *Glycobiology.* 2014;25(7):702-713. doi:10.1093/glycob/cwv021.
50. Ervasti JM, Campbell KP. A role for the dystrophin-glycoprotein complex as a transmembrane linker between laminin and actin. *J Cell Biol.* 1993;122(4):809-823. doi:10.1083/jcb.122.4.809.
51. Ibraghimov-Beskrovnaya O, Ervasti J, Leveille C, Slaughter C, Sernett, SCK. Primary structure of dystrophin associated glycoproteins linking dystrophin to the extracellular matrix. *Nature.* 1992;355:696-672. doi:10.1038/355696a0.
52. Winder SJ. The complexities of dystroglycan. *Trends Biochem Sci.* 2001;26(2):118-124. doi:10.1016/S0968-0004(00)01731-X.
53. Endo T. Glycobiology of  $\alpha$ -dystroglycan and muscular dystrophy. *J Biochem.* 2015;157(1):1-12. doi:10.1093/jb/mvu066.
54. Barresi R, Campbell KP. Dystroglycan: From biosynthesis to pathogenesis of human disease. *J Cell Sci.* 2006;119(2):199-207. doi:10.1242/jcs.02814.
55. Crosbie RH, Heighway J, Venzke DP, Lee JC, Campbell KP. Sarcospan, the 25-kDa transmembrane component of the dystrophin- glycoprotein complex. *J Biol Chem.* 1997;272(50):31221-31224. doi:10.1074/jbc.272.50.31221.
56. Yang B, Jung D, Rafael JA, Chamberlain JS, Campbell KP. Identification of  $\alpha$ -syntrophin binding to syntrophin triplet, dystrophin, and utrophin. *J Biol Chem.* 1995;270(10):4975-4978. doi:10.1074/jbc.270.10.4975.
57. Miyagoe-Suzuki Y, Takeda S. Association of neuronal nitric oxide synthase (nNOS) with  $\alpha$ 1-syntrophin at the sarcolemma. *Microsc Res Tech.* 2001;55(3):164-170. doi:10.1002/jemt.1167.
58. Peters MF, Adams ME, Froehner SC. Differential association of syntrophin pairs with the dystrophin complex. *J Cell Biol.* 1997;138(1):81-93. doi:10.1083/jcb.138.1.81.
59. Compton AG, Cooper ST, Hill PM, Yang N, Froehner SC, North KN. The syntrophin-dystrobrevin subcomplex in human neuromuscular disorders. *J Neuropathol Exp Neurol.* 2005;64(4):350-361. doi:10.1093/jnen/64.4.350.
60. Heywood WE, Bliss E, Mills P, et al. Global serum glycoform profiling for the investigation of dystroglycanopathies & Congenital Disorders of Glycosylation. *Mol Genet Metab Reports.* 2016;7:55-62. doi:10.1016/j.ymgmr.2016.03.002.
61. Muntoni F, Brockington M, Godfrey C, et al. Muscular dystrophies due to defective glycosylation of dystroglycan. *Acta Myol.* 2007;26(3):129-135.

62. Grewal PK, Hewitt JE. Glycosylation defects: A new mechanism for muscular dystrophy? *Hum Mol Genet.* 2003;12(2):259-264. doi:10.1093/hmg/ddg272.
63. De Bernabé DBV, Currier S, Steinbrecher A, et al. Mutations in the O-mannosyltransferase gene POMT1 give rise to the severe neuronal migration disorder Walker-Warburg syndrome. *Am J Hum Genet.* 2002;71(5):1033-1043. doi:10.1086/342975.
64. Yoshida A, Kobayashi K, Manya H, et al. Muscular dystrophy and neuronal migration disorder caused by mutations in a glycosyltransferase, POMGnT1. *Dev Cell.* 2001;1(5):717-724. doi:10.1016/S1534-5807(01)00070-3.
65. Inamori KI, Endo T, Gu J, et al. N-Acetylglucosaminyltransferase IX acts on the GlcNAc $\beta$ 1,2-Mana 1-Ser/Thr Moiety, forming a 2,6-Branched structure in brain O-mannosyl glycan. *J Biol Chem.* 2004;279(4):2337-2340. doi:10.1074/jbc.C300480200.
66. Liu Y, Yu M, Shang X, et al. Eyes shut homolog (EYS) interacts with matriglycan of O-mannosyl glycans whose deficiency results in EYS mislocalization and degeneration of photoreceptors. *Sci Rep.* 2020;10(1):7795. doi:10.1038/s41598-020-64752-4.
67. Nagae M, Mishra SK, Neyazaki M, et al. 3D structural analysis of protein O-mannosyl kinase, POMK, a causative gene product of dystroglycanopathy. *Genes to Cells.* 2017;22(4):348-359. doi:10.1111/gtc.12480.
68. Yoshida-Moriguchi T, Yu L, Stalnakar S, et al. O-mannosyl phosphorylation of alpha-dystroglycan is required for laminin binding. 2010;327:88-92. doi:10.1126/science.1180512.
69. Alhamidi M, Kjeldsen Buvang E, Fagerheim T, et al. Fukutin-related protein resides in the Golgi cisternae of skeletal muscle fibres and forms disulfide-linked homodimers via an N-terminal interaction. *PLoS One.* 2011;6(8):e22968. doi:10.1371/journal.pone.0022968.
70. Lu PJ, Tucker JD, Branch EK, Guo F, Blaeser AR, Lu QL. Ribitol enhances matriglycan of  $\alpha$ -dystroglycan in breast cancer cells without affecting cell growth. *Sci Rep.* 2020;10(1):4935. doi:10.1038/s41598-020-61747-z.
71. Hara Y, Kanagawa M, Kunz S, et al. Like-acetylglucosaminyltransferase (LARGE)-dependent modification of dystroglycan at Thr-317/319 is required for laminin binding and arenavirus infection. *Proc Natl Acad Sci U S A.* 2011;108(42):17426-17431. doi:10.1073/pnas.1114836108.
72. Beltrán D, Anderson ME, Bharathy N, et al. Exogenous expression of the glycosyltransferase LARGE1 restores  $\alpha$ -dystroglycan matriglycan and laminin binding in rhabdomyosarcoma. *Skelet Muscle.* 2019;9(1):11. doi:10.1186/s13395-019-0195-0.
73. Satz JS, Ostendorf AP, Hou S, et al. Distinct functions of glial and neuronal dystroglycan in the developing and adult mouse brain. *J Neurosci.* 2010;30(43):14560-14572. doi:10.1523/JNEUROSCI.3247-10.2010.
74. Praissman JL, Willer T, Sheikh MO, et al. The functional O-mannose glycan on  $\alpha$ -dystroglycan contains a phosphoribitol primed for matriglycan addition. *Elife.* 2016;5:e14473. doi:10.7554/eLife.14473.
75. Walimbe AS, Okuma H, Joseph S, et al. Pomk regulates dystroglycan function via large1-mediated elongation of matriglycan. *Elife.* 2020;9:e61388. doi:10.7554/ELIFE.61388.
76. Balci-Hayta B, Talim B, Kale G, Dincer P. LARGE expression in different types of muscular dystrophies other than dystroglycanopathy. *BMC Neurol.* 2018;18(1):207. doi:10.1186/s12883-018-1207-0.
77. Barresi R, Michele DE, Kanagawa M, et al. LARGE can functionally bypass  $\alpha$ -dystroglycan glycosylation defects in distinct congenital muscular dystrophies. *Nat Med.* 2004;10(7):696-703. doi:10.1038/nm1059.
78. Patnaik SK, Stanley P. Mouse large can modify complex N- and mucin O-glycans on  $\alpha$ -dystroglycan to induce laminin binding. *J Biol Chem.* 2005;280(21):20851-20859. doi:10.1074/jbc.M500069200.
79. Inamori KI, Hara Y, Willer T, et al. Xylosyl- and glucuronyltransferase functions of LARGE in  $\alpha$ -dystroglycan modification are conserved in LARGE2. *Glycobiology.* 2013;23(3):295-302. doi:10.1093/glycob/cws152.
80. Inamori K, Yoshida-Moriguchi T, Hara Y, Anderson ME, Yu L, Campbell KP. Dystroglycan function requires xylosyl- and glucuronyltransferase activities of LARGE. *Science.* 2012;335(6064):93-96. doi:10.1126/science.1214115.
81. Asteggiano CG, Papazoglu M, Bistué Millón MB, et al. Ten years of screening for congenital disorders of glycosylation in Argentina: case studies and pitfalls. *Pediatr Res.* 2018;84(6):837-841. doi:10.1038/s41390-018-0206-6.
82. Papazoglu GM, Ruiz SMS, Salinas R, et al. Platelet Membrane Glycoprofiling in a PMM2-CDG Patient. *J Inborn Errors Metab Screen.* 2021;9:e20200030. doi:10.1590/2326-4594-jiems-2020-0030.
83. Jaeken J. Congenital disorders of glycosylation: A multi-genetic disease family with multiple subcellular locations. *J Mother Child.* 2020;24(2):14-20. doi:10.34763/jmotherandchild.20202402si.2005.000004.
84. Bogdańska A, Lipiński P, Szymańska-Rożek P, et al. Clinical, biochemical and molecular phenotype of congenital disorders of glycosylation: long-term follow-up. *Orphanet J Rare Dis.* 2021;16(1):17. doi:10.1186/s13023-020-01657-5.

85. Abu Bakar N, Lefeber DJ, van Scherpenzeel M. Clinical glycomics for the diagnosis of congenital disorders of glycosylation. *J Inherit Metab Dis.* 2018;41(3):499-513. doi:10.1007/s10545-018-0144-9.
86. Papazoglu GM, Cubilla M, Pereyra M, et al. Mass spectrometry glyco-phenotype characterization of ALG2-CDG in Argentinean patients with a new genetic variant in homozygosity. *Glycoconj J.* 2021;38(2):191-200. doi:10.1007/s10719-021-09976-w.
87. Wells L. The o-mannosylation pathway: Glycosyltransferases and proteins implicated in congenital muscular dystrophy. *J Biol Chem.* 2013;288(10):6930-6935. doi:10.1074/jbc.R112.438978.
88. Carss KJ, Stevens E, Foley AR, et al. Mutations in GDP-mannose pyrophosphorylase b cause congenital and limb-girdle muscular dystrophies associated with hypoglycosylation of  $\alpha$ -dystroglycan. *Am J Hum Genet.* 2013;93(1):29-41. doi:10.1016/j.ajhg.2013.05.009.
89. Lefeber DJ, Schönberger J, Morava E, et al. Deficiency of Dol-P-Man synthase subunit DPM3 bridges the congenital disorders of glycosylation with the dystroglycanopathies. *Am J Hum Genet.* 2009;85(1):76-86. doi:10.1016/j.ajhg.2009.06.006.
90. Willer T, Lee H, Lommel M, et al. ISPD loss-of-function mutations disrupt dystroglycan O-mannosylation and cause Walker-Warburg syndrome. *Nat Genet.* 2012;44(5):575-580. doi:10.1038/ng.2252.ISPD.
91. Sheikh MO, Halmo SM, Wells L. Recent advancements in understanding mammalian O-mannosylation. *Glycobiology.* 2017;27(9):806-819. doi:10.1093/glycob/cwx062.
92. Barone R, Aiello C, Race V, et al. DPM2-CDG: A muscular dystrophy-dystroglycanopathy syndrome with severe epilepsy. *Ann Neurol.* 2012;72(4):550-558. doi:10.1002/ana.23632.
93. Haro C, Uribe ML, Quereda C, Cruces J, Martín-Nieto J. Expression in retinal neurons of fukutin and FKRP, the protein products of two dystroglycanopathy-causative genes. *Mol Vis.* 2018;24:43-58.
94. Sheikh MO, Wells L. Whoa man! Unexpected protein O-mannosylation pathways in mammals. *J Biol Chem.* 2017;292(27):11599-11600. doi:10.1074/jbc.H117.794487.
95. Halmo SM, Singh D, Patel S, et al. Protein O-linked mannose  $\beta$ -1,4-N-acetylglucosaminyltransferase 2 (POMGNT2) is a gatekeeper enzyme for functional glycosylation of  $\alpha$ -dystroglycan. *J Biol Chem.* 2017;292(6):2101-2109. doi:10.1074/jbc.M116.764712.
96. Stalnaker SH, Aoki K, Lim JM, et al. Glycomic analyses of mouse models of congenital muscular dystrophy. *J Biol Chem.* 2011;286(24):21180-21190. doi:10.1074/jbc.M110.203281.
97. Yagi H, Kuo CW, Obayashi T, Ninagawa S, Khoo KH, Kato K. Direct mapping of additional modifications on phosphorylated o-glycans of  $\alpha$ -dystroglycan by mass spectrometry analysis in conjunction with knocking out of causative genes for dystroglycanopathy. *Mol Cell Proteomics.* 2016;15(11):3424-3434. doi:10.1074/mcp.M116.062729.
98. Wallace SE, Conta JH, Winder TL, et al. A novel missense mutation in POMT1 modulates the severe congenital muscular dystrophy phenotype associated with POMT1 nonsense mutations. *Neuromuscul Disord.* 2014;24(4):312-320. doi:10.1016/j.nmd.2014.01.001.
99. Judaš M, Sedmak G, Radoš M, et al. POMT1-associated walker-warburg syndrome: A disorder of dendritic development of neocortical neurons. *Neuropediatrics.* 2009;40(1):6-14. doi:10.1055/s-0029-1224099.
100. Michele DE, Barresi R, Kanagawa M, et al. Post-translational disruption of dystroglycan-ligand interactions in congenital muscular dystrophies. *Nature.* 2002;418(6896):417-422. doi:10.1038/nature00837.
101. van Tol W, Michelakakis H, Georgiadou E, et al. Toward understanding tissue-specific symptoms in dolichol-phosphate-mannose synthesis disorders; insight from DPM3-CDG. *J Inherit Metab Dis.* 2019;42(5):984-992. doi:10.1002/jimd.12095.
102. Yiş U, Uyanik G, Rosendahl DM, et al. Clinical, radiological, and genetic survey of patients with muscle-eye-brain disease caused by mutations in POMGNT1. *Pediatr Neurol.* 2014;50(5):491-497. doi:10.1016/j.pediatrneurol.2014.01.008.
103. Hehr U, Uyanik G, Gross C, et al. Novel POMGNT1 mutations define broader phenotypic spectrum of muscle-eye-brain disease. *Neurogenetics.* 2007;8(4):279-288. doi:10.1007/s10048-007-0096-y.
104. Biancheri R, Bertini E, Falace A, et al. POMGNT1 mutations in congenital muscular dystrophy. *Arch Neurol.* 2006;63(10):1491. doi:10.1001/archneur.63.10.1491.
105. Vuillaumier-Barrot S, Bouchet-Seraphin C, Chelbi M, et al. Intragenic rearrangements in LARGE and POMGNT1 genes in severe dystroglycanopathies. *Neuromuscul Disord.* 2011;21(11):782-790. doi:10.1016/j.nmd.2011.06.001.
106. Diesen C, Saarinen A, Pihko H, et al. POMGNT1 mutation and phenotypic spectrum in muscle-eye-brain disease. *J Med Genet.* 2004;41(10):e115. doi:10.1136/jmg.2004.020701.
107. Yang H, Cai F, Liao H, Gan S, Xiao T, Wu L. Case report: ISPD gene mutation leads to dystroglycanopathies: Genotypic phenotype analysis and treatment exploration. *Front Pediatr.* 2021;9:1-7. doi:10.3389/fped.2021.710553.
108. Biswal S, Panigrahi D, Mohakud N, Kumar M, Swain N. A child of congenital muscular dystrophy-dystroglycanopathy with homozygous missense variation in exon 3 of the ISPD Gene: A rare case from Odisha. *Adv Biomed Res.* 2020;9(1):70. doi:10.4103/abr.abr\_141\_19.

109. Cirak S, Foley AR, Herrmann R, et al. ISPD gene mutations are a common cause of congenital and limb-girdle muscular dystrophies. *Brain*. 2013;136(1):269-281. doi:10.1093/brain/aws312.
110. Willer T, Lee H, Lommel M, et al. ISPD loss-of-function mutations disrupt dystroglycan O-mannosylation and cause Walker-Warburg syndrome. *Nat Genet*. 2012;44(5):575-580. doi:10.1038/ng.2252.
111. Magri F, Colombo I, Del Bo R, et al. ISPD mutations account for a small proportion of Italian Limb Girdle Muscular Dystrophy cases. *BMC Neurol*. 2015;15(1):172. doi:10.1186/s12883-015-0428-8.
112. Tokuoka H, Imae R, Nakashima H, et al. CDP-ribitol prodrug treatment ameliorates ISPD-deficient muscular dystrophy mouse model. *Nat Commun*. 2022;13(1):1847. doi:10.1038/s41467-022-29473-4.
113. Brasseur-Daudruy M, Vivier PH, Ickowicz V, Eurin D, Verspyck E. Walker-Warburg syndrome diagnosed by findings of typical ocular abnormalities on prenatal ultrasound. *Pediatr Radiol*. 2012;42(4):488-490. doi:10.1007/s00247-011-2242-9.
114. Vajsar J, Baskin B, Swoboda K, Biggar DW, Schachter H, Ray PN. Walker-Warburg Syndrome with POMT1 mutations can be associated with cleft lip and cleft palate. *Neuromuscul Disord*. 2008;18(8):675-677. doi:10.1016/j.nmd.2008.05.014.
115. Yis U, Uyanik G, Kurul S, et al. A case of Walker-Warburg syndrome resulting from a homozygous POMT1 mutation. *Eur J Paediatr Neurol*. 2007;11(1):46-49. doi:10.1016/j.ejpn.2006.10.007.
116. Beltran-Valero de Bernabé D, Voit T, Longman C, et al. Mutations in the FKRP gene can cause muscle-eye-brain disease and Walker-Warburg syndrome. *J Med Genet*. 2004;41(5):e61. doi:10.1136/jmg.2003.013870
117. Chen XY, Song DY, Fan Y Bin, et al. Novel mutations in B3GALNT2 gene causing  $\alpha$ -dystroglycanopathy in Chinese patients. *Chin Med J (Engl)*. 2021;134(12):1483-1485. doi:10.1097/CM9.0000000000001283.
118. Wang P, Jin P, Zhu L, et al. Prenatal diagnosis of Walker-Warburg syndrome due to compound mutations in the B3GALNT2 gene. *J Gene Med*. 2022;24(5):e3417. doi:10.1002/jgm.3417.
119. van Reeuwijk J, Grewal PK, Salih MAM, et al. Intragenic deletion in the LARGE gene causes Walker-Warburg syndrome. *Hum Genet*. 2007;121(6):685-690. doi:10.1007/s00439-007-0362-y.
120. Endo T, Manya H, Seta N, Guicheney P. POMGnT1, POMT1, and POMT2 mutations in congenital muscular Dystrophies. In: Fukuda M, ed. *Methods in enzymology*. 1st ed. v. 479. Elsevier Inc.; 2010:343-352. doi:10.1016/S0076-6879(10)79019-4.
121. Manzini MC, Gleason D, Chang BS, et al. Ethnically diverse causes of walker-warburg syndrome (WWS): FCMD mutations are a more common cause of WWS outside of the middle east. *Hum Mutat*. 2008;29(11):20844. doi:10.1002/humu.20844.
122. Roscioli T, Kamsteeg EJ, Buysse K, et al. Mutations in ISPD cause Walker-Warburg syndrome and defective glycosylation of  $\alpha$ -dystroglycan. *Nat Genet*. 2012;44(5):581-585. doi:10.1038/ng.2253.
123. Santavuori P, Somer H, Sainio K, et al. Muscle-eye-brain disease (MEB). *Brain Dev*. 1989;11(3):147-153. doi:10.1016/S0387-7604(89)80088-9.
124. Shenoy AM, Markowitz JA, Bonnemann CG, Krishnamoorthy K, Bossler AD, Tseng BS. Muscle-Eye-Brain disease. *J Clin Neuromuscul Dis*. 2010;11(3):124-126. doi:10.1097/CND.0b013e3181c5054d
125. Khan M, Hamid R, Recchia FM. Novel retinal findings in an infant with muscle-eye-brain disease. *Retin Cases Br Reports*. 2012;6(2):206-208. doi:10.1097/ICB.0b013e318234ccbe.
126. Signorino G, Covaceuszach S, Bozzi M, et al. A dystroglycan mutation (p.Cys667Phe) associated to muscle-eye-brain disease with multicystic leucodystrophy results in ER-retention of the mutant protein. *Hum Mutat*. 2018;39(2):266-280. doi:10.1002/humu.23370.
127. Kobayashi K, Nakahori Y, Miyake M, et al. An ancient retrotransposal insertion causes Fukuyama-type congenital muscular dystrophy. *Nature*. 1998;394(6691):388-392. doi:10.1038/28653.
128. Balci B, Morris-Rosendahl DJ, Çelebi A, Talim B, Topaloğlu H, Dinçer P. Prenatal diagnosis of muscle-eye-brain disease. *Prenat Diagn*. 2007;27(1):51-54. doi:10.1002/pd.1622.
129. Whitmore C, Fernandez-Fuente M, Booler H, et al. The transgenic expression of LARGE exacerbates the muscle phenotype of dystroglycanopathy mice. *Hum Mol Genet*. 2014;23(7):1842-1855. doi:10.1093/hmg/ddt577.
130. Meilleur KG, Zukosky K, Medne L, et al. Clinical, pathologic, and mutational spectrum of dystroglycanopathy caused by LARGE mutations. *J Neuropathol Exp Neurol*. 2014;73(5):425-441. doi:10.1097/NEN.000000000000065.
131. Tachikawa M, Kanagawa M, Yu CC, Kobayashi K, Toda T. Mislocalization of fukutin protein by disease-causing missense mutations can be rescued with treatments directed at folding amelioration. *J Biol Chem*. 2012;287(11):8398-8406. doi:10.1074/jbc.M111.300905.
132. Silan F, Yoshioka M, Kobayashi K, et al. A new mutation of the fukutin gene in a non-Japanese patient. *Ann Neurol*. 2003;53(3):392-396. doi:10.1002/ana.10491.
133. Vuillaumier-Barrot S, Quijano-Roy S, Bouchet-Seraphin C, et al. Four caucasian patients with mutations in the fukutin gene and variable clinical phenotype. *Neuromuscul Disord*. 2009;19(3):182-188. doi:10.1016/j.nmd.2008.12.005.

134. Saito Y, Yamamoto T, Ohtsuka-Tsurumi E, et al. Fukutin expression in mouse non-muscle somatic organs: Its relationship to the hypoglycosylation of  $\alpha$ -dystroglycan in Fukuyama-type congenital muscular dystrophy. *Brain Dev.* 2004;26(7):469-479. doi:10.1016/j.braindev.2004.01.004.
135. Fu X, Yang H, Wei C, et al. FKRP mutations, including a founder mutation, cause phenotype variability in Chinese patients with dystroglycanopathies. *J Hum Genet.* 2016;61(12):1013-1020. doi:10.1038/jhg.2016.94.
136. Yoshioka M, Kobayashi K, Toda T. Novel FKRP mutations in a Japanese MDC1C sibship clinically diagnosed with Fukuyama congenital muscular dystrophy. *Brain Dev.* 2017;39(10):869-872. doi:10.1016/j.braindev.2017.05.013.
137. Longman C, Brockington M, Torelli S, et al. Mutations in the human LARGE gene cause MDC1D, a novel form of congenital muscular dystrophy with severe mental retardation and abnormal glycosylation of  $\alpha$ -dystroglycan. *Hum Mol Genet.* 2003;12(21):2853-2861. doi:10.1093/hmg/ddg307.
138. Clarke NF, Maugendre S, Vandebrouck A, et al. Congenital muscular dystrophy type 1D (MDC1D) due to a large intragenic insertion/deletion, involving intron 10 of the LARGE gene. *Eur J Hum Genet.* 2011;19(4):452-457. doi:10.1038/ejhg.2010.212.
139. Brown SC, Torelli S, Brockington M, et al. Abnormalities in  $\alpha$ -Dystroglycan expression in MDC1C and LGMD2I muscular dystrophies. *Am J Pathol.* 2004;164(2):727-737. doi:10.1016/S0002-9440(10)63160-4.
140. Louhichi N, Triki C, Quijano-Roy S, et al. New FKRP mutations causing congenital muscular dystrophy associated with mental retardation and central nervous system abnormalities. Identification of a founder mutation in Tunisian families. *Neurogenetics.* 2004;5(1):27-34. doi:10.1007/s10048-003-0165-9.
141. Brockington M, Yuva Y, Prandini P, et al. Mutations in the fukutin-related protein gene (FKRP) identify limb girdle muscular dystrophy 2I as a milder allelic variant of congenital muscular dystrophy MDC1C. *Hum Mol Genet.* 2001;10(25):2851-2859. doi:10.1093/hmg/10.25.2851.
142. Poppe M, Cree L, Bourke J, et al. The phenotype of limb-girdle muscular dystrophy type 2I. *Neurology.* 2003;60(8):1246-1251. doi:10.1212/01.WNL.0000058902.88181.3D.
143. Wahbi K, Meune C, Hamouda EH, et al. Cardiac assessment of limb-girdle muscular dystrophy 2I patients: An echography, Holter ECG and magnetic resonance imaging study. *Neuromuscul Disord.* 2008;18(8):650-655. doi:10.1016/j.nmd.2008.06.365.
144. Ortiz-Cordero C, Azzag K, Perlingeiro RCR. Fukutin-related protein: From pathology to treatments. *Trends Cell Biol.* 2021;31(3):197-210. doi:10.1016/j.tcb.2020.11.003.
145. Vannoy CH, Leroy V, Broniowska K, Lu QL. Metabolomics analysis of skeletal muscles from FKRP-deficient mice indicates improvement after gene replacement therapy. *Sci Rep.* 2019;9(1):10070. doi:10.1038/s41598-019-46431-1.
146. Dhoke NR, Kim H, Selvaraj S, et al. A universal gene correction approach for FKRP-associated dystroglycanopathies to enable autologous cell therapy. *Cell Rep.* 2021;36(2):109360. doi:10.1016/j.celrep.2021.109360.
147. Thomas PJ, Xu R, Martin PT. B4GALNT2 (GALGT2) Gene Therapy Reduces Skeletal Muscle Pathology in the FKRP P448L Mouse Model of Limb Girdle Muscular Dystrophy 2I. *Am J Pathol.* 2016;186(9):2429-2448. doi:10.1016/j.ajpath.2016.05.021.
148. Saito F, Kanagawa M, Ikeda M, et al. Overexpression of LARGE suppresses muscle regeneration via down-regulation of insulin-like growth factor 1 and aggravates muscular dystrophy in mice. *Hum Mol Genet.* 2014;23(17):4543-4558. doi:10.1093/hmg/ddu168.
149. Peyrard M, Seroussi E, Sandberg-Nordqvist AC, et al. The human LARGE gene from 22q12.3-q13.1 is a new, distinct member of the glycosyltransferase gene family. *Proc Natl Acad Sci U S A.* 1999;96(2):598-603. doi:10.1073/pnas.96.2.598.
150. Wu B, Shah SN, Lu P, et al. Glucocorticoid steroid and alendronate treatment alleviates dystrophic phenotype with enhanced functional glycosylation of  $\alpha$ -dystroglycan in mouse model of Limb-Girdle muscular dystrophy with FKRP448L mutation. *Am J Pathol.* 2016;186(6):1635-1648. doi:10.1016/j.ajpath.2016.02.015.
151. Wu B, Shah SN, Lu P, et al. Long-term treatment of tamoxifen and raloxifene alleviates dystrophic phenotype and enhances muscle functions of FKRP dystroglycanopathy. *Am J Pathol.* 2018;188(4):1069-1080. doi:10.1016/j.ajpath.2017.12.011.
152. Bailey EC, Alrowaished SS, Kilroy EA, et al. NAD<sup>+</sup> improves neuromuscular development in a zebrafish model of FKRP-associated dystroglycanopathy. *Skelet Muscle.* 2019;9(1):21. doi:10.1186/s13395-019-0206-1.
153. Taniguchi-Ikeda M, Kobayashi K, Kanagawa M, et al. Pathogenic exon-trapping by SVA retrotransposon and rescue in Fukuyama muscular dystrophy. *Nature.* 2011;478(7367):127-131. doi:10.1038/nature10456.
154. Kanagawa M, Kobayashi K, Tajiri M, et al. Identification of a post-translational modification with ribitol-phosphate and its defect in muscular dystrophy. *Cell Rep.* 2016;14(9):2209-2223. doi:10.1016/j.celrep.2016.02.017.
155. Cataldi MP, Blaeser A, Lu P, Leroy V, Lu QL. ISPD Overexpression Enhances Ribitol-Induced Glycosylation of  $\alpha$ -Dystroglycan in Dystrophic FKRP Mutant Mice. *Mol Ther - Methods Clin Dev.* 2020;17:271-280. doi:10.1016/j.omtm.2019.12.005.

156. Manya H, Endo T. Glycosylation with ribitol-phosphate in mammals: New insights into the O-mannosyl glycan. *Biochim Biophys Acta - Gen Subj*. 2017;1861(10):2462-2472. doi:10.1016/j.bbagen.2017.06.024.
157. Kanagawa M, Toda T. Ribitol-phosphate - A newly identified posttranslational glycosylation unit in mammals: Structure, modification enzymes and relationship to human diseases. *J Biochem*. 2018;163(5):359-369. doi:10.1093/jb/mvy020.
158. Kim J, Lana B, Torelli S, et al. A new patient-derived iPSC model for dystroglycanopathies validates a compound that increases glycosylation of  $\alpha$ -dystroglycan. *EMBO Rep*. 2019;20(11):e47967. doi:10.15252/embr.201947967.
159. Gerin I, Ury B, Breloy I, et al. ISPD produces CDP-ribitol used by FKTN and FKRP to transfer ribitol phosphate onto  $\alpha$ -dystroglycan. *Nat Commun*. 2016;7:11534. doi:10.1038/ncomms11534.
160. Kuwabara N, Imae R, Manya H, et al. Crystal structures of fukutin-related protein (FKRP), a ribitol-phosphate transferase related to muscular dystrophy. *Nat Commun*. 2020;11(1):303. doi:10.1038/s41467-019-14220-z.
161. Nickolls AR, Lee MM, Zukosky K, Mallon BS, Bönemann CG. Human embryoid bodies as a 3D tissue model of the extracellular matrix and  $\alpha$ -dystroglycanopathies. *DMM Dis Model Mech*. 2020;13(6):dmm042986. doi:10.1242/dmm.042986.
162. Darabi R, Gehlbach K, Bachoo RM, et al. Functional skeletal muscle regeneration from differentiating embryonic stem cells. *Nat Med*. 2008;14(2):134-143. doi:10.1038/nm1705.
163. Frattini P, Villa C, Santis F De, et al. Autologous intramuscular transplantation of engineered satellite cells induces exosome-mediated systemic expression of Fukutin-related protein and rescues disease phenotype in a murine model of limb-girdle muscular dystrophy type 2I. *Hum Mol Genet*. 2017;26(19):3682-3698. doi:10.1093/hmg/ddx252.
164. Dong M, Noguchi S, Endo Y, et al. DAG1 mutations associated with asymptomatic hyperCKemia and hypoglycosylation of  $\alpha$ -dystroglycan. *Neurology*. 2015;84(3):273-279. doi:10.1212/WNL.0000000000001162.
165. Gupta V, Kawahara G, Gundry SR, et al. The zebrafish dag1 mutant: A novel genetic model for dystroglycanopathies. *Hum Mol Genet*. 2011;20(9):1712-1725. doi:10.1093/hmg/ddr047.
166. Dai Y, Liang S, Dong X, et al. Whole exome sequencing identified a novel DAG1 mutation in a patient with rare, mild and late age of onset muscular dystrophy-dystroglycanopathy. *J Cell Mol Med*. 2019;23(2):811-818. doi:10.1111/jcmm.13979.
167. Leibovitz Z, Mandel H, Falik-Zaccai TC, et al. Walker-Warburg syndrome and tectocerebellar dysraphia: A novel association caused by a homozygous DAG1 mutation. *Eur J Paediatr Neurol*. 2018;22(3):525-531. doi:10.1016/j.ejpn.2017.12.012.
168. Østergaard ST, Johnson K, Stojkovic T, et al. Limb girdle muscular dystrophy due to mutations in POMT2. *J Neurol Neurosurg Psychiatry*. 2018;89(5):506-512. doi:10.1136/jnnp-2017-317018.
169. Yanagisawa A, Bouchet C, Van Den Bergh PYK, et al. New POMT2 mutations causing congenital muscular dystrophy: Identification of a founder mutation. *Neurology*. 2007;69(12):1254-1260. doi:10.1212/01.wnl.0000268489.60809.c4.
170. Brun BN, Willer T, Darbro BW, et al. Uniparental disomy unveils a novel recessive mutation in POMT2. *Neuromuscul Disord*. 2018;28(7):592-596. doi:10.1016/j.nmd.2018.04.003.
171. Chen XY, Song DY, Jiang L, et al. Phenotype and genotype study of chinese POMT2-Related  $\alpha$ -dystroglycanopathy. *Front Genet*. 2021;12:692479. doi:10.3389/fgene.2021.692479.
172. Messina S, Mora M, Pegoraro E, et al. POMT1 and POMT2 mutations in CMD patients: A multicentric Italian study. *Neuromuscul Disord*. 2008;18(7):565-571. doi:10.1016/j.nmd.2008.04.004.
173. Mercuri E, Messina S, Bruno C, et al. Congenital muscular dystrophies with defective glycosylation of dystroglycan: A population study. *Neurology*. 2009;72(21):1802-1809. doi:10.1212/01.wnl.0000346518.68110.60.
174. Van Reeuwijk J, Janssen M, Van Den Elzen C, et al. POMT2 mutations cause  $\alpha$ -dystroglycan hypoglycosylation and Walker-Warburg syndrome. *J Med Genet*. 2005;42(12):907-912. doi:10.1136/jmg.2005.031963.
175. Godfrey C, Clement E, Mein R, et al. Refining genotype-phenotype correlations in muscular dystrophies with defective glycosylation of dystroglycan. *Brain*. 2007;130(10):2725-2735. doi:10.1093/brain/awm212.
176. Imae R, Kuwabara N, Manya H, et al. The structure of POMGNT2 provides new insights into the mechanism to determine the functional O-mannosylation site on  $\alpha$ -dystroglycan. *Genes to Cells*. 2021;26(7):485-494. doi:10.1111/gtc.12853.
177. Endo Y, Dong M, Noguchi S, et al. Milder forms of muscular dystrophy associated with POMGNT2 mutations. *Neurol Genet*. 2015;1(4):33. doi:10.1212/NXG.0000000000000033.
178. Maroofian R, Riemersma M, Jae LT, et al. B3GALNT2 mutations associated with non-syndromic autosomal recessive intellectual disability reveal a lack of genotype-phenotype associations in the muscular dystrophy-dystroglycanopathies. *Genome Med*. 2017;9(1):118. doi:10.1186/s13073-017-0505-2.
179. Hedberg C, Oldfors A, Darin N. B3GALNT2 is a gene associated with congenital muscular dystrophy with brain malformations. *Eur J Hum Genet*. 2014;22(5):707-710. doi:10.1038/ejhg.2013.223.

180. Wu WJ, Sun SZ, Li BG. Congenital muscular dystrophy caused by beta1,3-N- acetylgalactosaminyltransferase 2 gene mutation: Two case reports. *World J Clin Cases.* 2022;10(3):1056-1066. doi:10.12998/wjcc.v10.i3.1056.
181. Stevens E, Carss KJ, Cirak S, et al. Mutations in B3GALNT2 cause congenital muscular dystrophy and hypoglycosylation of  $\alpha$ -dystroglycan. *Am J Hum Genet.* 2013;92(3):354-365. doi:10.1016/j.ajhg.2013.01.016.
182. Strang-Karlsson S, Johnson K, Töpf A, et al. A novel compound heterozygous mutation in the POMK gene causing limb-girdle muscular dystrophy-dystroglycanopathy in a sib pair. *Neuromuscul Disord.* 2018;28(7):614-618. doi:10.1016/j.nmd.2018.04.012.
183. Di Costanzo S, Balasubramanian A, Pond HL, et al. POMK mutations disrupt muscle development leading to a spectrum of neuromuscular presentations. *Hum Mol Genet.* 2014;23(21):5781-5792. doi:10.1093/hmg/ddu296.
184. Paul L, Rupprich K, Della Marina A, et al. Further evidence for POMK as candidate gene for WWS with meningoencephalocele. *Orphanet J Rare Dis.* 2020;15(1):242. doi:10.1186/s13023-020-01454-0.
185. Esapa CT, McIlhinney RAJ, Blake DJ. Fukutin-related protein mutations that cause congenital muscular dystrophy result in ER-retention of the mutant protein in cultured cells. *Hum Mol Genet.* 2005;14(2):295-305. doi:10.1093/hmg/ddi026.
186. Vuillaumier-Barrot S, Bouchet-Séraphin C, Chelbi M, et al. Identification of mutations in TMEM5 and ISPD as a cause of severe cobblestone lissencephaly. *Am J Hum Genet.* 2012;91(6):1135-1143. doi:10.1016/j.ajhg.2012.10.009.
187. Astrea G, Pezzini I, Picillo E, et al. TMEM5-associated dystroglycanopathy presenting with CMD and mild limb-girdle muscle involvement. *Neuromuscul Disord.* 2016;26(7):459-461. doi:10.1016/j.nmd.2016.05.003.
188. Alazami AM, Patel N, Shamseldin HE, et al. Accelerating novel candidate gene discovery in neurogenetic disorders via whole-exome sequencing of prescreened multiplex consanguineous families. *Cell Rep.* 2015;10(2):148-161. doi:10.1016/j.celrep.2014.12.015.
189. Buysse K, Riemersma M, Powell G, et al. Missense mutations in  $\beta$ -1,3-N-acetylglucosaminyltransferase 1 (B3GNT1) cause Walker-Warburg syndrome. *Hum Mol Genet.* 2013;22(9):1746-1754. doi:10.1093/hmg/ddt021.
190. Jensen BS, Willer T, Saade DN, et al. GMPPB -Associated dystroglycanopathy: Emerging common variants with phenotype correlation. *Hum Mutat.* 2015;36(12):1159-1163. doi:10.1002/humu.22898.
191. Raphael AR, Couthouis J, Sakamuri S, et al. Congenital muscular dystrophy and generalized epilepsy caused by GMPPB mutations. *Brain Res.* 2014;1575(1):66-71. doi:10.1016/j.brainres.2014.04.028.
192. Belaya K, Rodríguez Cruz PM, Liu WW, et al. Mutations in GMPPB cause congenital myasthenic syndrome and bridge myasthenic disorders with dystroglycanopathies. *Brain.* 2015;138(9):2493-2504. doi:10.1093/brain/awv185.