



## Evaluation of wound healing and antimicrobial properties of aqueous extract from *Bowdichia virgilioides* stem barks in mice

ISABELA K.R. AGRA<sup>1</sup>, LUANA L.S. PIRES<sup>2</sup>, PAULO S.M. CARVALHO<sup>1</sup>,  
EURÍPEDES A. SILVA-FILHO<sup>2</sup>, SALETE SMANIOTTO<sup>1</sup> and EMILIANO BARRETO<sup>1</sup>

<sup>1</sup>Laboratório de Biologia Celular, Instituto de Ciências Biológicas e da Saúde, Universidade Federal de Alagoas, Campus A.C. Simões, Avenida Lourival Melo Mota, s/n, Tabuleiro dos Martins, 57072-970 Maceió, Al, Brasil

<sup>2</sup>Laboratório de Genética de Microorganismos, Instituto de Ciências Biológicas e da Saúde, Universidade Federal de Alagoas, Campus A.C. Simões, Avenida Lourival Melo Mota, s/n, Tabuleiro dos Martins, 57072-970 Maceió, Al, Brasil

Manuscript received on September 2, 2011, accepted for publication on October 19, 2011

### ABSTRACT

The decoction of the stem barks from *Bowdichia virgilioides* KUNTH is a folk remedy used to treat inflammatory disorders in Latin American and Brazil. In the present study, the wound healing activity of aqueous extract of the stem bark from *B. virgilioides*, called AEBv, was evaluated by the rate of healing by wound contraction and period of epithelization at different days post-wound using the wound excisional model. On day 9, the AEBv-treated animals exhibited significative reduction in the wound area when compared with controls. In wound infected with *S. aureus*, the AEBv significantly improved the wound contraction when compared to the saline-treated mice. The histological analysis showed that AEBv induced a collagen deposition, increase in the fibroblast count and few inflammatory cells than compared to saline-treated group. The expression of collagen type I was increased in the group treated with AEBv as indicated by immunohistochemical staining. *In vitro*, the AEBv was effective only against *S. aureus* but not against *P. aeruginosa*. Together, the results of this study demonstrate, for the first time, the healing and antimicrobiological effects of aqueous extract of the stem bark from *B. virgilioides* in the therapy of skin wounds.

**Key words:** wound healing, antimicrobial effect, *Bowdichia virgilioides*, medicinal plant.

### INTRODUCTION

*Bowdichia virgilioides* Kunth (Fabaceae) is a plant that grows commonly in several South American countries such as Venezuela, Guiana and Brazil (Flores and Rodrigues 2010). Various parts of *B. virgilioides* are used in the Brazilian traditional medicine for treatment of diseases. The bark is used for wound healing, as anti-ulcer and anti-diabetic (Bacchi 1986, Oliveira and Saito 1989, Braga

1953). Other plant parts such as seeds are used in folk medicine to treat rheumatism, arthritis, and skin diseases (Cruz 1965).

The stem bark preparations of the *B. virgilioides* are reported to have antimalarial (Deharo et al. 2001), analgesic and anti-inflammatory activities (Silva et al. 2010, Thomazzi et al. 2010, Barros et al. 2010). The stem bark contains several chemical substances such as lupeol, lupeol acetate, sitosterol and stigmasterol (Melo et al. 2001). Others include alkaloid named acosmine, ormosanine

Correspondence to Emiliano Barreto  
E-mail: emilianobarreto@optma.org

and podopetaline (Barbosa-Filho et al. 2004). The antimicrobial property from *B. virgilioides* has been attributed to its essential oil of seeds (Almeida et al. 2006) and leaves (J.G.R. Feitosa et al., unpublished data). However, there are no published reports on the antimicrobial activity of the stem barks from *B. virgilioides*.

Open wounds are particularly prone to infection, especially by bacteria, and also provide an entry point for systemic infections. Infected wounds heal less rapidly and also often result in the formation of unpleasant exudates and toxins that will be produced with concomitant killing of regenerating cells. Consequently, there is a need to stimulate healing and restore the normal functions of the affected part of the body to ease the discomfort and pain associated with wounds, preventing infection, and activating tissue repair processes. Antibacterial and healing compounds in a traditional remedy can induce this occurrence and may be beneficial in treating wounds (Reddy et al. 2008). In spite of recorded uses of the *B. virgilioides*, there is no scientific evidence that confirms the healing effect and antibacterial activity of stem bark of *B. virgilioides*. Thus, this work was undertaken to explore the antimicrobial and wound healing effects of *B. virgilioides* stem bark extract.

## MATERIALS AND METHODS

### PLANT MATERIAL AND PREPARATIONS OF AQUEOUS EXTRACT

Stem bark from *B. virgilioides* Kunth (Family Fabaceae) was collected in Maceió, Alagoas State, Brazil (9°33'12"S and 35°46'9"W). The plant was identified by Prof. Rosângela Lemos, Instituto do Meio Ambiente, Maceió, Brazil, and the voucher specimen (number MAC29914) has been deposited at the Herbarium MAC of the Instituto do Meio Ambiente.

After collection, the stem barks were dried at ambient temperature and triturated. The aqueous extract of *B. virgilioides*, called AEBv, was prepared

by infusing 50 g of powdered plant material for 20 minutes using 300 mL of boiling water. The extract was filtered and lyophilized. The yield of the infusion was 17.2% (wt=wt). At the time of use, extract was reconstituted in water (sterile endotoxin-free) at the required concentration (10 mg.kg<sup>-1</sup>) according as previous results (J.P. Silva, unpublished data).

### ANIMALS

Swiss mice of either sex weighing 18–22 g were obtained from the Universidade Federal de Alagoas (UFAL) breeding unit. The animals were maintained with free access to food and water and kept at 22–28°C with a controlled 12-hour light/dark cycle at the Instituto de Ciências Biológicas e da Saúde, UFAL. Experiments were performed during the light phase of the cycle. The animals were allowed to adapt to the laboratory for at least 2 hours before testing and were used only once. All experiments were carried out in accordance with institutional guidelines and ethics (License Number 23065.12614/2006-89).

### EXCISION WOUND MODEL

The animals were anesthetized with anesthetic ether and shaved at the predetermined site before wounding. A circular wound was inflicted by cutting away approximately 1.6 cm of diameter of the predetermined area on the anterior-dorsal side of each mice using sterile surgical blade (Morton and Malone 1972). The animals were then placed in separate cages to avoid any disturbance. The bedding was changed daily. After skin excision, the wound was left open to the environment.

In other set of experiments, the wound was inoculated (10 µL) with *Staphylococcus aureus* (ATCC 25923) at 10<sup>8</sup> Colony Forming Unit (CFU). All animals received topical application (200 µL) of solutions containing saline (NaCl, 0.9%) or AEBv (10 mg.kg<sup>-1</sup>) for once a day for 9 consecutive days starting from the day of wounding. As

standard treatment was used fibrinolysin (Fibrase SA<sup>®</sup>) on non-infected wounds or 1% silver sulfadiazine (Dermazine<sup>®</sup>) on infected wounds. The animals of the Fibrase SA<sup>®</sup> or Dermazine<sup>®</sup> groups were topically treated once a day with 0.5 g of each ointment. Wound contraction was calculated as percentage reduction in wound area. The progressive changes in wound area were monitored by a camera (Sony Cyber Shot, Dsc w80) on wounding day, followed by measurements on 3<sup>th</sup>, 6<sup>th</sup> and 9<sup>th</sup> day. Later on, wound area was evaluated by using ImageJ program (Nicoli et al. 2008). A specimen sample of tissue was isolated from the healed skin of each group of mice for the histopathological examination.

#### WOUND HEALING RATE

The wound area of each animal was measured on days 3, 6, and 9 post-surgery. The wound size measurements taken at the time of surgery and at the time of biopsy were used to calculate the percent wound contraction, using equation:

$$[(A_0 - A_t)/A_0] \times 100 = \% \text{ of wound closure}$$

where  $A_0$  is the original wound area, and  $A_t$  is the area of wound at the time of biopsy.

#### ANTIMICROBIAL SENSITIVITY TEST

Antimicrobial activities of extract was evaluated against *Staphylococcus aureus* (ATCC 25923), *Pseudomonas aeruginosa* (ATCC 27853) and *Staphylococcus aureus* (MRSA) which was supplied by Dr. Euripedes A. Silva-Fillho, UFAL, Maceió-AL, Brazil. The MRSA-strain was based on their resistance to methicillin (DMPPC) and oxacillin (MIPIC) according to the guidelines of the National Committee for Clinical Laboratory Standards (2003). A modified diffusion test was used to determine the antimicrobial activity (Joung et al. 2010). The colonies were taken directly from the plate and were suspended in 5 mL of sterile 0.85% saline. The turbidity of the initial suspension

was adjusted by comparing with 0.5 McFarland's standard. When adjusted to the turbidity of the 0.5 McFarland's standard, the bacteria suspension contains about 108 colony forming unites (CFU). mL<sup>-1</sup>. In different petridish the bacterial strains were grown to exponential phase in Mueller-Hinton broth at 37 °C for 18 h and adjusted to a final density of 10<sup>8</sup> CFU/ml by diluting fresh cultures and comparing with McFarland density (Murray et al. 1995). The blank control was performed with distilled water. Chloramphenicol was used as the positive control. In each petridish were made bores (4 mm) where each bore was loaded with 40 µL of water, AEBv (1, 2 and 4 mg.mL<sup>-1</sup>) or chloramphenicol (1 mg.mL<sup>-1</sup>). After incubation at 37°C for 24 h the inhibition zones around the bores were measured. The tests were performed in triplicate and the results were expressed in mm as the arithmetic media of diameters of the inhibition zones. After incubation, the result of antimicrobial activity test was reported as the average diameter of the inhibition zone surrounding the wells containing the test solution.

#### HISTOPATHOLOGICAL ANALYSIS

The skin specimens from each group were collected at 9 days after beginning of the experiment to evaluate the histopathological alterations in accordance with Tumen et al. (2012), being the analysis performed blindly by a pathologist. Samples were fixed in 10% buffered formalin, processed and blocked with paraffin. Then, sample were sectioned into 5 µm-thick sections and stained with hematoxylin and eosin (HE) and Masson's trichrome (MT). The tissues were examined by light microscope (Olympus BX51 attached DP70 Digital Camera System) and graded subjectively as mild (+), moderate (++) and severe (+++) for epidermal or dermal remodeling, reepithelization; fibroblast proliferation, mononuclear and/or polymorphonuclear cells and collagen depositions in dermis were analyzed to score the epidermal or dermal remodeling.

## IMMUNOHISTOCHEMICAL STAINING

Six  $\mu\text{m}$  thick skin cryostat sections were used for detecting type I collagen expression by immunoperoxidase staining. The sections were then treated with 0.3% hydrogen peroxide ( $\text{H}_2\text{O}_2$ ) in phosphate buffered saline (PBS) for 10 min to quench any endogenous peroxidase activity within the tissue. The nonspecific binding sites were blocked with 0.5% bovine serum albumin (BSA) for 10 min at room temperature. After washing with PBS, specimens were incubated with purified rabbit anti-mouse type I collagen antibody (Novotec - lot 338i) diluted 1:80 in PBS for 1 h at room temperature. After washing, the specimens were incubated with peroxidase-conjugated goat anti-rabbit IgG second antibody (Sigma) diluted 1:200 in PBS for 45 min at room temperature. Immunoreactivity was visualized with a diaminobenzidine (DAB) (Sigma) containing 0.02%  $\text{H}_2\text{O}_2$  for 10 min. The control sections were incubated directly with the secondary antibody in the absence of the primary antibody and processed as above. The specimens were observed using light microscope (Nikon *Eclipse* 50i).

## STATISTICAL ANALYSIS

Data are mean  $\pm$  SEM values. The statistical analysis involving two groups was done using Student's t test. Analysis of variance followed by the Student-

Neuman-Keuls test was used to compare three or more groups. Values of  $P < 0.05$  were considered as indicative of significance.

## RESULTS

## WOUND HEALING ACTIVITY

The wound healing activity of the aqueous extract prepared from the stem barks of *Bowdichia virgilioides* was evaluated on mice in the excision wound models to confirm the folkloric usage of the plant. The histopathological changes induced by this extract and its antimicrobial activity *in vitro* were also assessed. The area of the wound was measurement on the days 3, 6 and 9 days post surgery in all groups. The measurements of the progress of wound healing induced by the extract, reference drug and saline treated-groups in the excision of non-infected wounds are shown in Table I.

Table I shows the measured values of the closure progression of non-infected wound in different groups. After application of AEBv topically onto non-infected wounds the area of wound reduced 25% of their original size ( $2\text{ cm}^2$ ) on day 3, 62.5% on day 6 and 91% on day 9, and complete closure around day 10. In saline-treated animals, the area was reduced to 16.5% (day 3), 26%  $\text{cm}^2$  (day 6) and 44.5% (day 9). The wound closure in animals treated with reference drug, Fibrase, were 20% (day 3), 30% and 74% (day 9) (Table I). Treatment with

**TABLE I**  
Effect of aqueous extract of stem barks from *Bowdichia virgilioides* on non-infected wounds.

Treatment	Parameter			Period of epithelization (days)
	Wound area ( $\text{cm}^2$ ) on day			
	3	6	9	
Saline	1.67 $\pm$ 0.15	1.48 $\pm$ 0.11	1.11 $\pm$ 0.08	13.00 $\pm$ 0.00
Fibrase <sup>®</sup>	1.60 $\pm$ 0.06	1.40 $\pm$ 0.09	0.52 $\pm$ 0.08 ***	10.75 $\pm$ 0.5 **
AEBv	1.50 $\pm$ 0.12 <sup>c</sup>	0.75 $\pm$ 0.06 *** <sup>a</sup>	0.18 $\pm$ 0.03 *** <sup>b</sup>	9.60 $\pm$ 0.33 *** <sup>c</sup>

Values represent the mean  $\pm$  S.E.M., (n=4). Statistical differences were determined by ANOVA followed Student-Newman-Keuls test. \*\*\* $P < 0.001$ , \*\* $P < 0.01$ , \* $P < 0.05$  as compared to respective saline treatment. <sup>a</sup> $P < 0.001$ , <sup>b</sup> $P < 0.01$ , <sup>c</sup> $P < 0.05$  as compared to Fibrase-treated animals.

AEBv in non-infected wounds was able to reduce to 9 days the period of epithelialization when compared with saline-treated group and Fibrase group, which were, respectively, 13 and 10 days.

Table II shows the measured values of the closure progression of infected wound in different groups. After application of AEBv topically onto infected wounds the area of wound reduced 43% of their original size (2 cm<sup>2</sup>) on day 3, 84% on day 6 and 95.5% on day 9, and complete closure on day 10 (Table II). On the other hand, in saline-treated animals, the area was reduced to 16.8% (day 3), 26.3% (day 6) and 44.7% (day 9). The wound closure in animals treated with reference drug, Dermazine<sup>®</sup>, were 23.8% (day 3), 41.2% and 64.1% (day 9) (Table II). Treatment with AEBv in infected wounds was able to reduce to 10 days the period of epithelialization when compared with saline-treated group and Dermazine<sup>®</sup> group, which were, respectively, 17.5 and 15 days.

#### HISTOPATHOLOGICAL ANALYSIS

In order to confirm the experimental results, histopathological analysis was also performed. Figure 1 shows the histology of saline, AEBv and Fibrase-treated groups at 9 days of analysis in non-infected wound. The AEBv and Fibrase-treated groups shows faster wound healing processes if compared with saline-treated animals. There was attenuation in the infiltration of inflammatory cells

and enhanced proliferation of fibroblasts as a result of treatment with our extract and the reference drug. There was full thickness reepithelialization, in which epidermis was thin and well organized, comparable to the normal adjacent skin which was not involved in the wound generation and healing process. AEBv-treated wounds were associated with enhanced formation of epidermis and deposition of connective tissue when compared to that of control group animals. Less epithelialization and less collagen formation in saline-treated animals indicated incomplete healing.

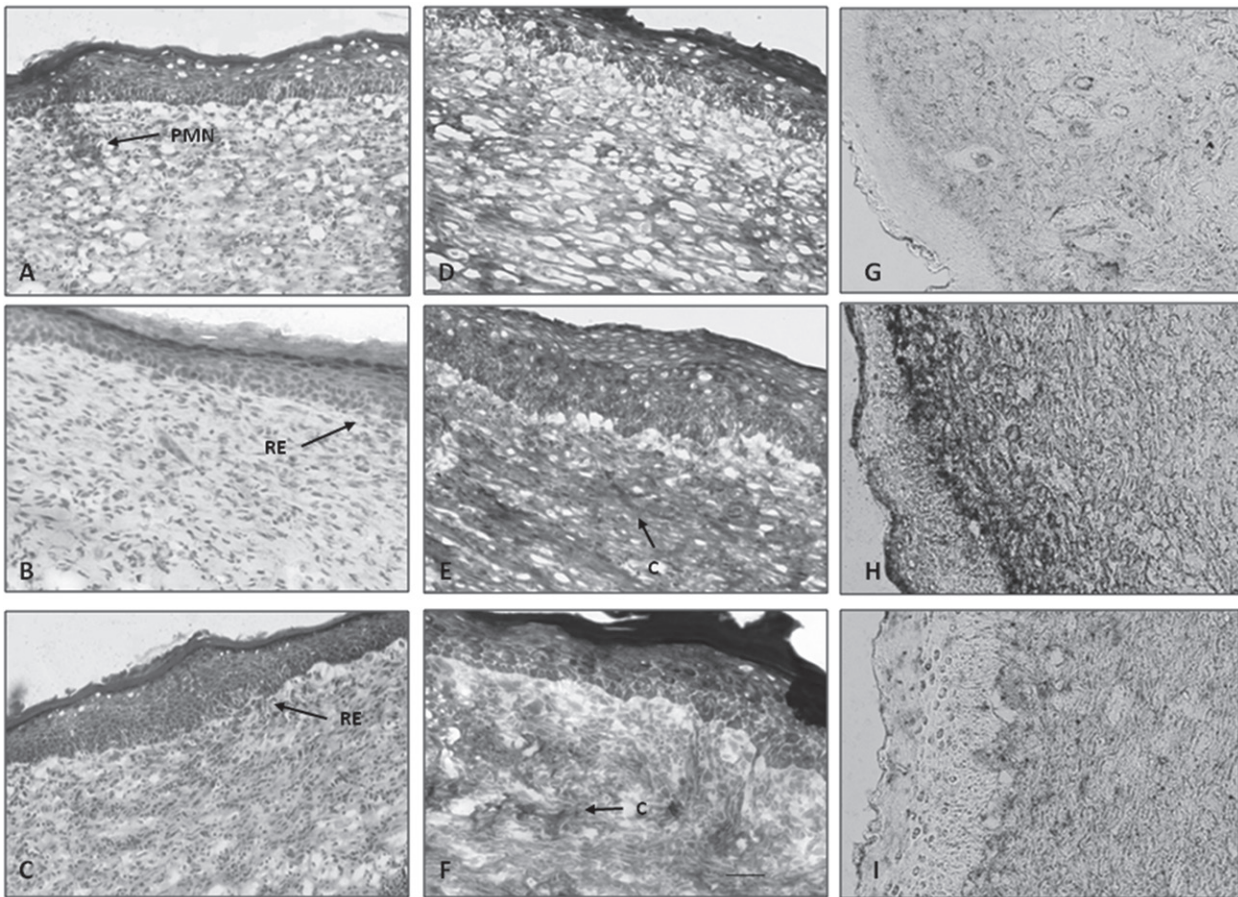
The expression of type I collagen was detected by the immunohistochemistry method (Figure 1). In contrast to the group treated with saline, a considerable expression of collagen type I was detected in the tissue after 9 days of treatment with AEBv (Figure 1G - 1H). This increase in collagen type I expression was the most effective in AEBv-treated group than compared to Fibrase-treated group (Figure 1H - 1I).

Figure 2 shows the histology of saline, AEBv and Dermazine-treated groups at 9 days of analysis in infected wound. The saline-treated group demonstrated delayed wound healing processes compared to the other groups. The epidermis in infected wounds was thick and disorganized, especially when compared with the adjacent normal skin. Clumps of degenerating tissue, necrotic changes, and the persistence of

**TABLE II**  
Effect of aqueous extract of stem barks from *Bowdichia virgilioides* on infected wounds.

Treatment	Parameter			Period of epithelialization (days)
	Wound area (cm <sup>2</sup> ) on day			
	3	6	9	
Saline	1.53 ± 0.03	1.25 ± 0.03	1.04 ± 0.03	17.50 ± 0.50
Dermazine <sup>®</sup>	1.53 ± 0.05	1.18 ± 0.04	0.72 ± 0.04 ***	15.00 ± 0.00 **
AEBv	1.14 ± 0.12 **	0.32 ± 0.08 *** <sup>a</sup>	0.09 ± 0.04 *** <sup>a</sup>	10.00 ± 0.00 *** <sup>a</sup>

Values represent the mean ± S.E.M., (n=4). Statistical differences were determined by ANOVA followed Student-Newman-Keuls test. \*\*\*P<0.001, \*\*P<0.01 as compared to respective saline treatment. <sup>a</sup>P<0.001 as compared to Dermazine-treated animals.



**Figure 1** - Histopathological view of epidermal/dermal remodeling in non-infected wounds. In **A**, **B** and **C** show skin sections stained with hematoxylin and eosin. In **D**, **E** and **F** show skin sections stained with Masson's trichrome. In **G**, **H** and **I** show immunohistological staining to expression of collagen type I. The original magnification was 100x. Data are representative of 4 animals per group. **A**, **D** and **G** Saline-treated group (9-day-old wound tissue treated with only saline); **B**, **E** and **H** AEBv group (9-day-old wound tissue treated with *B. virgilioides* extract); **C**, **F** and **I** Fibrase-treated group (9-day-old wound tissue treated with Fibrase). Arrows pointing events during wound healing: RE: reepithelization; C: collagen; PMN: polymorphonuclear cells.

inflammatory exudates in the upper dermis with loss of epidermis were observed in infected wounds on day 9. AEBv and Dermazine-treated mice showed marked epithelialization and moderate amount of connective tissue synthesis. Following histopathological examination to both infected and non-infected wound, the scored results were combined, summarized and presented in Table III.

The expression of collagen type I was detected in 9 days after injury in infected wounds (Figure 2). The AEBv-treated group demonstrated clusters of slight increase in expression of collagen type I compared with the saline-treated group (Figure 2G

- 2H). Dermazine treatment had less effect on the collagen type I expression in comparison with the AEBv-treated group (Figure 2H- 2I).

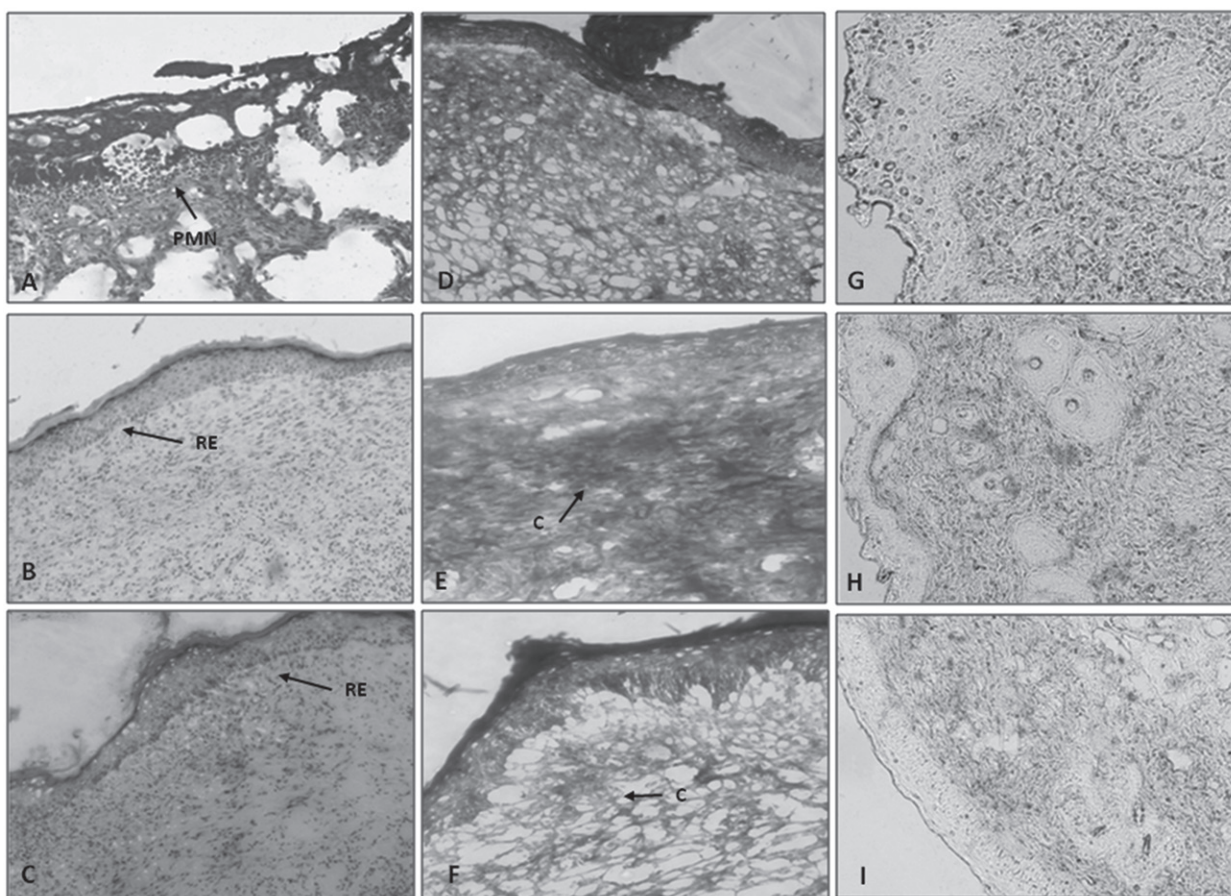
#### ANTIMICROBIAL SENSITIVITY TEST

Table IV shows the antibacterial activity of aqueous extracts of the stem bark of *Bowdichia virgilioides* against two bacterial strains, *S. aureus* and *P. aeruginosa*. The AEBv showed the highest antibacterial activity against *S. aureus* while had no effect against *P. aeruginosa*. Chloramphenicol, a standard antibiotic, showed a significantly antibacterial activity against the test organisms.

**TABLE III**  
Wound healing processes of aqueous extract of stem barks from *Bowdichia virgilioides*.

Wound healing processes	Groups					
	Non-infected wounds			Infected wounds		
	Saline	Fibrase	AEBv	Saline	Dermazine	AEBv
RE	+/++	++	+++	-/+	++	+++
FP	+	+++	+++	+	+/++	++
CD	+	+/++	+++	-/+	-/+	++/+++
PMN	++	-/+	-/+	++	+	-/+

Values represent the mean  $\pm$  S.E.M., (n=4). Statistical differences were determined by ANOVA followed Student-Newman-Keuls test. \*\*\*P<0.001, \*\*P<0.01 as compared to respective saline treatment. aP<0.001 as compared to Dermazine-treated animals.



**Figure 2** - Histopathological view of epidermal/dermal remodeling in infected wounds. In **A**, **B** and **C** show skin sections stained with hematoxylin and eosin. In **D**, **E** and **F** show skin sections stained with Masson's trichrome. In **G**, **H** and **I** show immunohistological staining to expression of collagen type I. The original magnification was 100x. Data are representative of 4 animals per group. **A**, **D** and **G** Saline-treated group (9-day-old wound tissue treated with only saline); **B**, **E** and **H** AEBv group (9-day-old wound tissue treated with *B. virgilioides* extract); **C**, **F** and **I** Dermazine-treated group (9-day-old wound tissue treated with Dermazine). Arrows pointing events during wound healing: RE: reepithelization; C: collagen; PMN: polymorphonuclear cells.

**TABLE IV**  
**Antibacterial activity of the aqueous stem bark extracts of *B. virgilioides*.**

Treatment	Dose (mg.mL <sup>-1</sup> )	Zone of inhibition (mm)	
		<i>S. aureus</i> (ATCC 25923)	<i>P. aeruginosa</i> (ATCC 27853)
EABv	1	15.0 ± 0.0	NA
	2	16.0 ± 0.0	NA
	4	18.0 ± 0.0	NA
Chloramphenicol	1	20.0 ± 0.0	10.0 ± 0.0

NA, not active. Values represent the mean ± S.E.M.

Due to the high antimicrobial activity of the AEBv against *S. aureus* ATCC 25923, the antimicrobial activity against *S. aureus* MRSA was assessed. Results demonstrated that the AEBv (4 mg.mL<sup>-1</sup>) induced an inhibition zone of 18 mm for strain MRSA, value similar to that presented by the standard strain.

#### DISCUSSION

In the present paper we report the wound healing potential of the aqueous extract of the stem bark of *Bowdichia virgilioides*, AEBv, applied on infected and non-infected wounds in mice. The extract of *Bowdichia virgilioides* showed antimicrobial activity (J.G.R. Feitosa et al., unpublished data, Almeida et al. 2006), analgesic and anti-inflammatory effects (Silva et al. 2010, Thomazzi et al. 2010, Barros et al. 2010). So, if any plant material presents antimicrobial, analgesic and anti-inflammatory activities together, it can be supposed that this material also may help to promote wound healing and contribute skin regeneration.

We observed that the topical application of AEBv enhances cutaneous healing, which appeared completed in 9 days. The histological findings showed that the original tissue regeneration is much greater in skin wounds treated with the extract than in wounds saline-treated. The wound contraction is mediated by specialized myofibroblasts found in the granulated tissue (Moulin et al. 2000). So, the increase in wound contraction in AEBv-treated mice might be a result of the enhanced activity of fibroblasts.

Indeed, the response to injury involves the migration and proliferation of cells such as fibroblasts, endothelial and epithelial cells, and deposition of connective tissue and contraction of the wound. Collagen not only confers strength and integrity to the tissue matrix but also plays an important role in homeostasis and in epithelialization at the later phase of healing (Clark 1996). Here, our finding revealed that treatment with AEBv caused an increased in the deposition of the bands of collagen, a phenomenon that appears to contribute with the increase in wound contraction.

Collagen type I is the most common protein in animals and provides the tensile strength of healing in wounds. Besides contributing to the skin strength, collagen type I is also important to guide keratinocytes and dermal fibroblasts migration in the wounded area (Bennett and Schultz 1993). Considering this, our results suggest that topical treatment with AEBv could be beneficial to wounds skin repair in both conditions infected and non-infected.

Skin wound healing starts immediately after injury and consists of three phases: inflammation, proliferation, and maturation. The first response is inflammation, acting as a defense mechanism of the tissue, able to provide a resistance to the microbial contaminations (Kondo 2007). But, a long duration in the inflammatory phase causes a delay in healing process. Anti-inflammatory activity is necessary for shorten the healing period (Shimizu et al. 2000). Therefore, the significant wound healing



activity of AEBv may be related to its remarkable anti-inflammatory effect as presented in previous reports (Silva et al. 2010, Thomazzi et al. 2010).

Antimicrobial activity is important for the wound healing period, because the wound exposed to external environment is more prone to microbial attacks, which usually results in a delay in the healing process. So, risk factors such as infections may compromise the repair process. *S. aureus* and *P. aeruginosa* are the most common pathogens responsible for infection in skin wounds (Arora and Kaur 2007). Topical applications of drugs are effective both as microbicide and increasing wound healing rate because of its greater availability at the infected wound site. In this study, the slow rate of wound closure in control mice may be attributable to the presence of microorganisms and their metabolites, which inhibits wound contraction and impair healing. In this study, even in infected wounds where the period of epithelialization is greater, when the animals were treated with AEBv there was a better wound healing if compared to animals treated with saline.

*In vitro* analysis of the antimicrobial effect of AEBv showed a potential inhibitory effect against Gram-positive bacteria *S. aureus*, but not against Gram-negative bacteria such as *P. aeruginosa*. In line with this observation, previous results from J.G.R. Feitosa et al. (unpublished data) showed that essential oil of seeds from *B. virgilioides* possess an antimicrobial activity against Gram-positive *B. subtilis*, *B. vulgaris*, *E. faecalis* and *S. aureus* and had low activity *in vitro* against Gram-negative *P. aeruginosa*, *S. enteritidis* and *E. coli*. This antibacterial effectiveness may be attributed to the fact that cell wall in Gram-positive bacteria consists of a single layer, whereas Gram-negative cell wall is a multilayered structure bounded by an outer cell membrane (Mahomoodally et al. 2010). Moreover, findings from the present study showed that AEBv was effective against a methicillin-resistant strain of *S. aureus* (MRSA). These MRSA are difficult to treat because they are also multiresistant and up to

now there are no satisfactory antimicrobial drugs (Joung et al. 2010). Therefore, regarding to the present result, extract from *B. virgilioides* seem to be a potential tool to combat the problem of MRSA.

The results of our study indicate, for the first time, that *B. virgilioides* may be a potential candidate for dermal wound healing because of its positive influence on phases of the healing process and particularly effective in view of its antimicrobial properties. Therefore, there is, the need for further studies into the stability of the extract to ensure an efficacious formulation of products for wound healing.

#### ACKNOWLEDGMENTS

This work was supported by grants from the Conselho Nacional de Desenvolvimento Científico e Tecnológico (CNPq), the Programa de Cooperação Acadêmica/Coordenação de Aperfeiçoamento de Pessoal de Nível Superior (PROCAD/CAPES) and the Fundação de Amparo à Pesquisa do Estado de Alagoas (FAPEAL) (Brazil).

#### RESUMO

A decoção das cascas do caule de *Bowdichia virgilioides* Kunth é um medicamento popular usado para tratar doenças inflamatórias na América Latina e no Brasil. Neste estudo, a atividade de cicatrização de feridas do extrato aquoso da casca do caule de *B. virgilioides*, chamado AEBv, foi avaliada pela contração da ferida e pelo período de epitelização em diferentes dias pós-ferida usando o modelo ferida excisional. No nono dia, os animais tratados com AEBv apresentaram uma redução significativa na área da ferida, quando comparados com os controles. Nas feridas infectadas com *S. aureus*, o AEBv melhorou significativamente a contração da ferida quando comparado com os camundongos tratados com solução salina. A análise histológica mostrou que AEBv induziu uma deposição de colágeno, aumento na contagem de fibroblastos e poucas células inflamatórias do que em relação ao grupo tratado com solução salina. A expressão de colágeno tipo I mostrou-se aumentada no grupo tratado com AEBv como indicado pela coloração imuno-

histoquímica. *In vitro*, o AEBV foi eficaz apenas contra *S. aureus*, mas não contra *P. aeruginosa*. Juntos, os resultados deste estudo demonstram, pela primeira vez, a cura e os efeitos antimicrobianos do extrato aquoso da casca do caule de *B. virgilioides* na terapia de feridas cutâneas.

**Palavras-chave:** Cicatrização de feridas, efeito antimicrobiano, *Bowdichia virgilioides*, planta medicinal.

## REFERENCES

- ALMEIDA JRGS, SILVA-FILHO M, NUNES XP, DIAS CS, PEREIRA FO AND LIMA EO. 2006. Antimicrobial activity of the essential oil of *Bowdichia virgilioides* Kunt. *Rev Bras Farmacogn* 16: 638-641.
- ARORA DS AND KAUR GJ. 2007. Antibacterial activity of some Indian medicinal plants. *J Nat Med* 61: 313-317.
- BACCHI EM. 1986. Ação antiúlcera e cicatrizante de algumas plantas brasileiras, *Rev Bras Farmacog* 1: 93-100.
- BARBOSA-FILHO JM, DA-SILVA ALMEIDA JR, DE-OLIVEIRA COSTA VC, DA-CUNHA EV, DA-SILVA MS AND BRAZ-FILHO R. 2004. Bowdichine, a new diaza-adamantane alkaloid from *Bowdichia virgilioides*. *J Asian Nat Prod Res* 6: 11-17.
- BARROS CWM, RAO VS, SILVA RM, LIMA JC AND MARTINS DT. 2010. Anti-inflammatory effect of the ethanolic extract from *Bowdichia virgilioides* H.B.K stem bark. *An Acad Bras Cienc* 82: 609-616.
- BENNETT NT AND SCHULTZ GS. 1993. Growth factors and wound healing: biochemical properties of growth factors and their receptors. *Am J Surg* 165: 728-737.
- BRAGA R. 1953. Plantas do nordeste, especialmente do Ceará. Coleção Mossoroense. Ed. Universitária UFRN. 4ª edição, Fortaleza, CE, Brasil, p. 449-453.
- CLARK RAF. 1996. Wound repair: overview and general considerations. In: CLARK RA AND HENSON PM. *The molecular and cellular biology of wound repair*, 2<sup>nd</sup> ed., New York: Plenum, p. 3-50.
- CRUZ GL. 1965. Livro Verde das Plantas Mediciniais e Industriais do Brasil. Ed. Helmus, Belo Horizonte, MG, Brasil, 779 p.
- DEHARO E, BOURDY G, QUENEVO C, MUNOZ V, RUIZ G AND SAUVAIN M. 2001. A search for natural bioactive compounds in Bolivia through a multidisciplinary approach. Part V. Evaluation of the antimalarial activity of plants used by the Tacana Indians. *J Ethnopharmacol* 77: 91-98.
- FLORES S AND RODRIGUES RS. 2010. Diversidade de Leguminosae em uma área de savana do estado de Roraima, Brasil. *Acta Bot Bras* 24: 175-183.
- JOUNG H, KWON DY, CHOI JP, SHIN DY, CHUN SS, YU YB AND SHIN DW. 2010. Antibacterial and synergistic effects of *Smalanthus sonchifolius* leaf extracts against methicillin-resistant *Staphylococcus aureus* under light intensity. *J Nat Med* 64: 212-215.
- KONDO T. 2007. Timing of skin wounds. *Leg Med* 9: 109-114.
- MAHOMOODALLY MF, GURIB-FAKIM A AND SUBRATTY AH. 2010. Screening for Alternative Antibiotics: An investigation into the antimicrobial activities of medicinal food plants of Mauritius. *J Food Sci* 75: 173-177.
- MELO FN, NAVARRO VR, SILVA MS, DA-CUNHA EV, BARBOSA-FILHO JM AND BRAZ-FILHO R. 2001. Bowdenol, a new 2,3-dihydrobenzofuran constituent from *Bowdichia virgilioides*. *Nat Prod Lett* 15: 261-266.
- MORTON JJ AND MALONE MH. 1972. Evaluation of vulnerary activity by an open wound procedure in rats. *Arch Int Pharmacody Thér* 196: 117-126.
- MOULIN V, AUGER FA, GAREL D AND GERMAIN L. 2000. Role of wound healing myofibroblasts on re-epithelization of human skin. *Burns* 26: 3.
- MURRAY PR, BARON EJ, PFALLER MA, TENOVER FC AND YOLKEN RH. 1995. *Manual of clinical microbiology*. 6<sup>th</sup> ed., Washington, U.S.A. American Society for Microbiology, 165 p.
- NATIONAL COMMITTEE FOR CLINICAL LABORATORY STANDARDS. 2003. *Methods for Dilution Antimicrobial Susceptibility Tests for Bacteria That Grow Aerobically*, 2<sup>nd</sup> ed., Approved Standard. NCCLS document M2-A8. 940 West Valley Road, Suite 1400, Wayne, Pennsylvania: NCCLS.
- NICOLI S, PADULA C, AVERSA V, VIETTI B, WERTZ PW, MILLET A, FALSON F, GOVONI P AND SANTI P. 2008. Characterization of rabbit ear skin as a skin model for *in vitro* transdermal permeation experiments: histology, lipid composition and permeability. *Skin Pharmacol Physiol* 21: 218-226.
- OLIVEIRA O AND SAITO ML. 1989. Alguns vegetais brasileiros empregados no tratamento do diabetes. *Rev Bras Farmacogn* 2: 170-196.
- REDDY S, REDDY RKK, NAIDU VG, MADHUSUDHANA K, AGWANE SB, RAMAKRISHNA S AND DIWAN PV. 2008. Evaluation of antimicrobial, antioxidant and wound-healing potentials of *Holoptelea integrifolia*. *J Ethnopharmacol* 115: 249-256.
- SHIMIZU N, WATANABE T, ARAKAWA T, FUJIWARA Y, HIGUCHI K AND KUROKI T. 2000. Pentoxifylline accelerates gastric ulcer healing in rats: roles of tumor necrosis factor alpha and neutrophils during the early phase of ulcer healing. *Digestion* 61: 157-164.
- SILVA JP, RODARTE RS, CALHEIROS AS, SOUZA CZ, AMENDOEIRA FC, MARTINS MA, SILVA PM, FRUTUOSO VS AND BARRETO E. 2010. Antinociceptive activity of aqueous extract of *Bowdichia virgilioides* in mice. *J Med Food* 13: 348-351.
- THOMAZZI SM, SILVA CB, SILVEIRA DC, VASCONCELLOS CL, LIRA AF, CAMBUI EV, ESTEVAM CS AND ANTONIOLLI AR. 2010. Antinociceptive and anti-inflammatory activities of *Bowdichia virgilioides* (sucupira). *J Ethnopharmacol* 127: 451-456.
- TUMEN I, SUNTAR I, KELES H AND AKKOL EK. 2012. A therapeutic approach for wound healing by using essential oils of *cupressus* and *juniperus* species growing in Turkey. *Evid Based Complement Alternat Med* 2012: 7.