

Right Ventricular Tumor in a Patient with Melanoma

Vinícius Daudt Morais, Flávio Dalbem, Krás Borges, Vicente Restelli

Instituto de Cardiologia – Fundação Universitária de Cardiologia, Porto Alegre, RS - Brazil.

Primary tumors of the heart are not common. However, metastatic neoplasms affecting the heart are more commonly found. Postmortem studies have shown that some tumors have reported secondary cardiac implants to be over 50%. Such involvement is to be taken into account for patients with a history of neoplasm and who present conduction disorders, murmur, cardiomegaly or arrhythmia. This is to report the case of a 39-year-old man who had been referred due to fatigue and dyspnea on effort. Echocardiogram evidence showed large tumoral mass in right ventricle. Medical history showed previous melanoma; further evaluation showed metastasis to lungs, heart and brain. Outcome was death. The uniqueness in this case relies on the large metastatic mass in right ventricle, thus illustrating a rare clinical condition of guarded prognosis.

Introduction

Primary tumors of the heart are rare. Incidence is 0.02% in autopsies, and 75% of them is benign. Myxomas account for 50% of cases reported. In comparison, for secondary or metastatic neoplasm incidence is reported to be 20-100 times higher^{1,2}. A particularly high incidence of metastatic involvement of the heart has been observed in pulmonary epidermoid carcinomas (62%), urinary tract tumors (60%), and melanomas (45%)³.

One of the most extensive series of terminal cancer patients showed that 8% presented metastasis involving the heart³.

Heart tumors may be symptomatic or, more commonly, incidental findings while non-related problems are being investigated. Clinical presentation is essentially related to that of disseminated neoplasm. Metastasis to the heart is typically asymptomatic⁴.

The present case is a report on a 39-year-old male patient referred to the hospital due to fatigue and dyspnea

Key words

Neoplasms; heart ventricles; melanoma; neoplasm, metastasis.

Mailing Address: Vinícius Daudt Morais •

Rua Protásio Alves, 1723/11 – Rio Branco 90410-001 – Porto Alegre, RS, Brazil

E-mail: vdaudt@brturbo.com.br

Manuscript received May 09, 2007; reviewed manuscript received September 03, 2007; accepted October 01, 2007

on effort, both associated to intracardiac mass observed on transthoracic echocardiogram. Although metastasis to the heart is common in high incidence neoplasm, the condition is hardly remembered in clinical practice. The relevance here is that it points out the key role played by secondary causes in cardiac mass investigation, as well as their repercussion in patients' therapeutic approach.

Case Report

In December, 2006, a 39-year-old male patient reported the onset of dyspnea and fatigue on effort. As the symptoms showed discreet progression in subsequent months, the patient went to see a cardiologist in March, 2007. On physical examination, the patient reported second hyperphonic beat and Grade 4 systolic murmur, with epicenter in fourth left intercostal space on left parasternal border. The echocardiogram performed in April, 2007, showed tumoral mass at the entry pathway of right ventricle and extending to ventricle exit, thus causing significant flow obstruction associated to moderate to significant pulmonary arterial hypertension (systolic pressure at pulmonary artery: 60 mmHg) (Figure 1).

On April, 2007, the patient was admitted at our hospital for surgical procedure due to right ventricle mass.

Patient's previous medical history showed resection of skin lesion in left cervical area. Histopathological data showed Clark's Level III nodular melanoma. Patient's surgical removal of skin lesion in right forearm in 2006 revealed skin lesion of superficial dissemination with surgical margins compromised.

Electrocardiogram showed right bundle branch block, enlarged right atrium, and secondary changes in ventricular repolarization.

The multiple bilateral nodular lesions observed on thorax X-Ray were compatible with secondary implants.

Thoracic CT Scan showed large expansive lesion occupying right ventricular cavity, with a reduction in right ventricle entry and exit pathways amplitude extending to main pulmonary artery and proximal area of major right and left branches. It also showed interventricular septal dislocation to the left, pericardial effusion, multiple pulmonary nodules – of different dimensions and bilateral randomic distribution – in addition to small bilateral axillary ganglions (figure 2).

A brain CT scan showed multiple brain lesions compatible with metastatic implants.

The surgical removal of the mass was considered inappropriate, whether for diagnostic or therapeutic purposes.

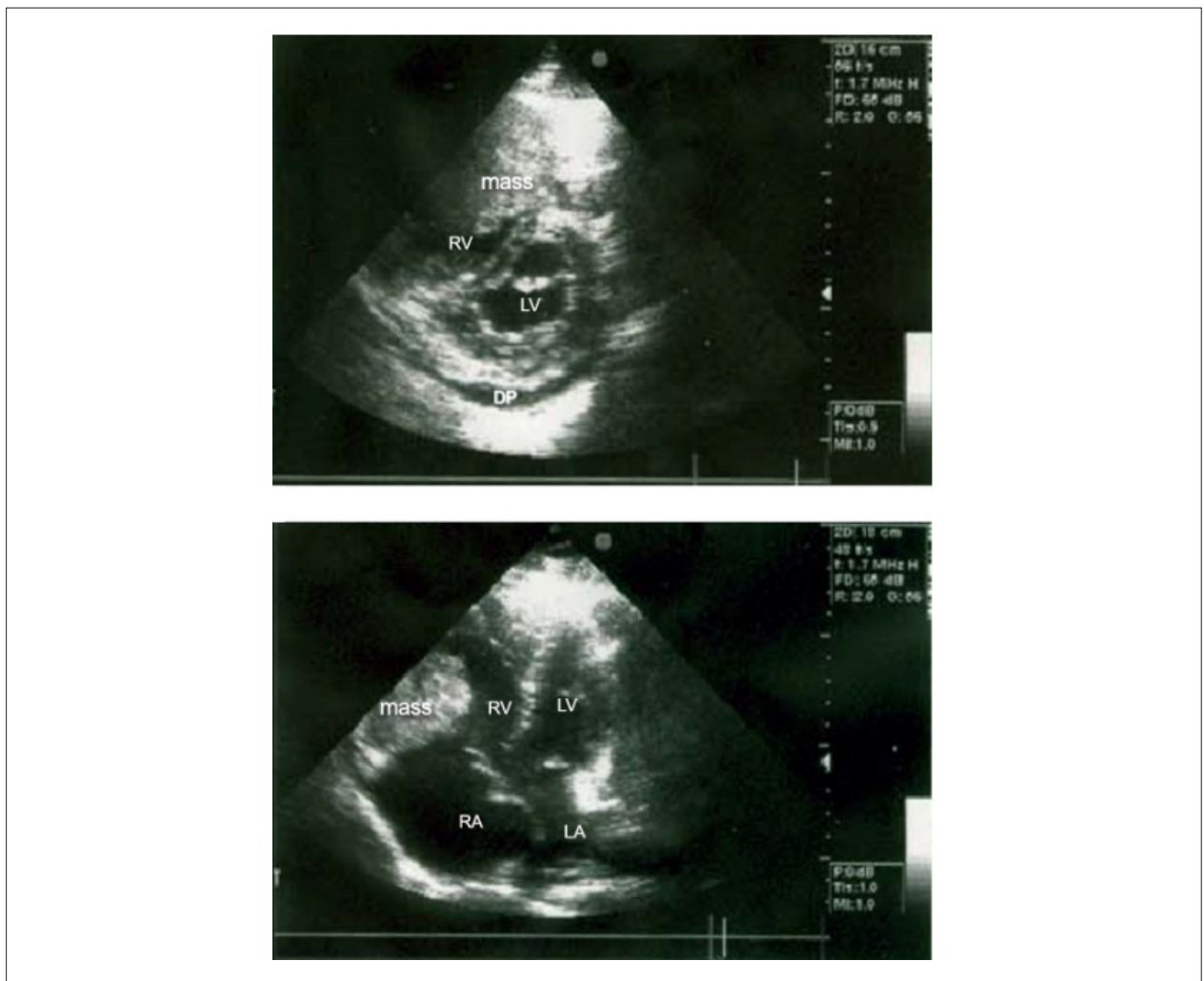

Figure 1 - Transthoracic echocardiography with evidence of right ventricle mass.

Diagnosis was assumed to be disseminated melanoma, with metastasis to lung, heart and brain, with no histopathologic evidence.

The patient was referred to the Oncology Service for systemic therapy. Chemotherapy was scheduled. However, significant clinical deterioration - Karnofski's index under 80% - led to the discontinuation of therapy plan.

The outcome was death in July, 2007.

Discussion

Primary tumors of the heart are rare, and most are benign. Secondary neoplasms are more common.

Although no neoplasm disseminates primarily to the heart, some do it more often. Under such scenario, mesothelioma, melanoma, lung adenocarcinoma, undifferentiated adenocarcinomas, pulmonary epidermoid carcinomas and breast carcinoma have shown evidence of metastasis to the heart - prevalence was 48%, 27%, 21%, 18%, 19% and 15% respectively in quite a number of cases⁵. A Japanese study

showed that primary sites most commonly involved in the metastasis to the heart were lung, followed by mediastine, liver, uterus and testicles⁶.

Approximately 2/3 of all cases reported for metastasis to the heart in a given series involved the pericardium (69.4%), 1/3 involved the epicardium (34.2%) or myocardium (31.8%) and only 5% involved the endocardium⁷.

Clinical manifestations - if any - were extremely variable. The most typical scenario is a patient with lung or breast neoplasm who starts reporting progressive dyspnea, hypotension and tachycardia. Some other common presentations include arrhythmia, such as atrial flutter, atrial fibrillation, premature beats, ventricular arrhythmias, conduction disorders and atrioventricular block, especially in the presence of myocardial impairment.

Whenever diagnosis is probable and surgical intervention is indicated, thoracotomy is a reasonable approach. Alternatively, histological evidence may be obtained for the purpose of diagnosis through echocardiography-guided transvenous biopsy. This procedure is safer, but not free of risks.

Case Report

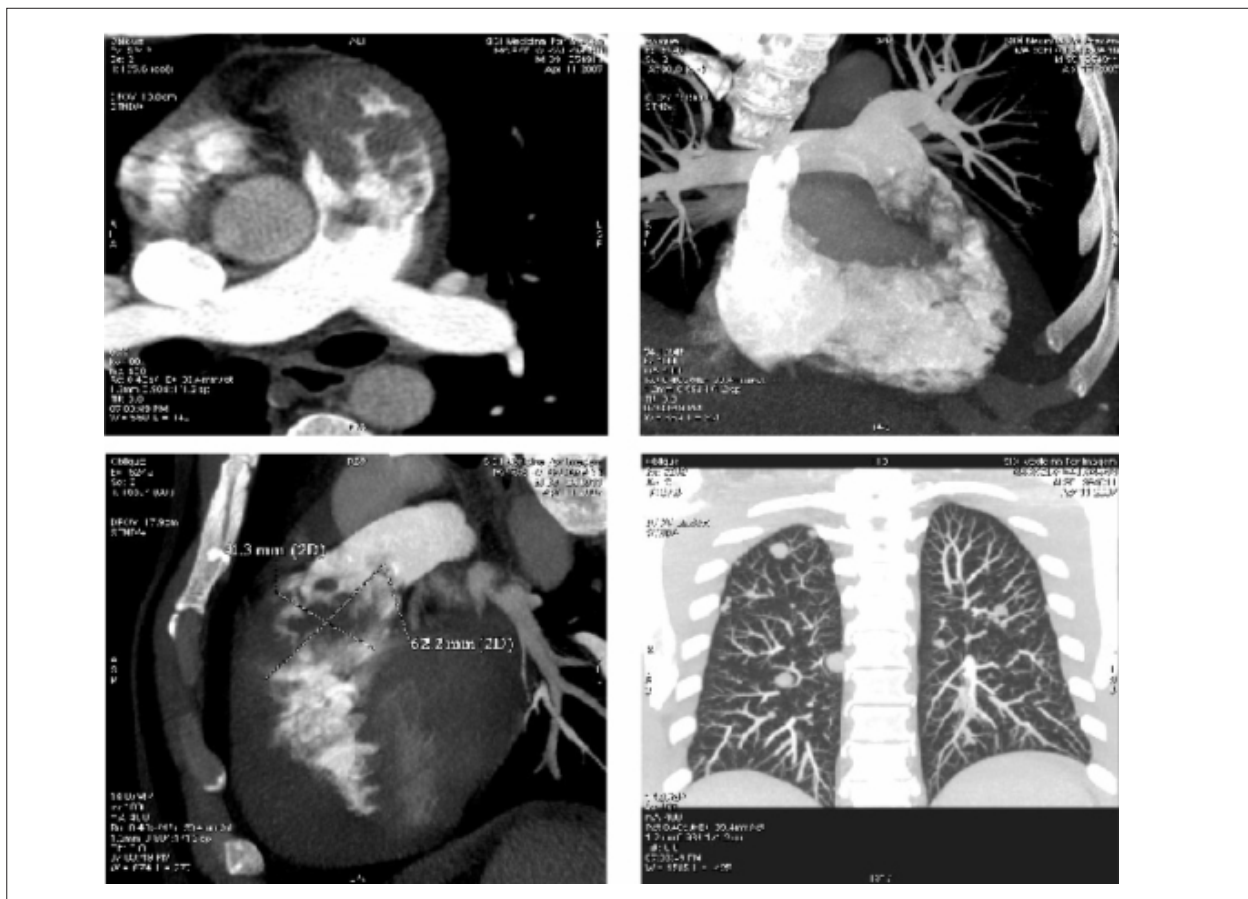


Figure 2 - Thoracic angiotomography reveals mass in right ventricle exit pathway and multiple nodular lesions in pulmonary parenchyma.

Literature has reported fatal outcomes from that approach⁷. In the present case, considering the disseminated condition, patient's previous history of neoplasm, and the lack of benefit from surgical intervention, such methods were ruled out. However, in the absence of a history of melanoma, histopathological evidence should be pursued for diagnosis confirmation.

Melanoma is a guarded prognosis neoplasm, mostly from being prone to early, oligosymptomatic metastases. Primary melanoma is predominantly cutaneous; primary tumors are rarely the cause of morbidity and mortality. Approximately 30% of patients with this neoplasm will develop metastatic conditions and will require systemic therapy. The most common secondary visceral sites involved are lungs, liver, brain and bones. Although 50% of patients with melanoma show cardiac involvement in postmortem studies, only 2% is reported by ante mortem studies. This neoplasm is considered to be the most prone to secondary cardiac involvement⁴.

In a series of 70 patients with metastatic melanoma, tumoral implants could be observed in the heart in 45 of them. Only in 11 cases the implants were associated to relevant cardiac dysfunction. Therefore, no well-defined correlation could be established between involvement degree and clinical repercussion⁸.

The involvement of the heart may occur due to hematogenic

dissemination, direct invasion of mediastine, and growth inside vena cava extending to right atrium. Hematogenic dissemination has been observed to be the most common.

Metastasis to the heart or to the pericardium must be considered whenever a patient with a malignant condition develops cardiovascular symptoms – particularly if those symptoms occur in association with cardiomegaly, murmur, conduction disorders or arrhythmia.

Some centers consider surgical resection for those patients if preoperative Karnofski's index is over 80%, if there is any very mild extracardiac condition, or if there is significant clinical deterioration due to cardiac symptoms^{9,10}.

Cardiac involvement is hardly found to be isolated; it is usually part of dissemination. The dissemination is typically multifocal and inappropriate for surgical approach. This mode of treatment is usually a palliative, and has the purpose to control of symptoms.

Patients with malign heart tumors – whether primary or secondary – have a guarded prognosis. The study showed that as low as 23% had a survival time over 6 months after diagnosis⁶.

Therapeutic options for those metastases are limited since involvement is diffuse, and chemotherapy is questionable. However, surgery may be an option for a small number of

patients – those with isolated cardiac involvement or cardiac function compromised by tumor – after surgical risk and expected survival time are considered¹¹.

To conclude: physicians must be very alert to the

possibility of metastasis to the heart in patients with a history of melanoma presenting possible cardiac symptoms. This diagnosis will have key repercussions for the treatment and prognosis of those cases.

References

1. Messner G, Harting MT, Russo P, Gregoric LD, Mukhopadhyay M, Flamm SD, et al. Surgical management of metastatic melanoma to the ventricle; *Tex Heart Inst J* 2003; 30:218.
2. Reynen K. Frequency of primary tumors of the heart. *Am J Cardiol.* 1996; 77 (1): 107.
3. Silvestri F, Bussani R, Pavletic N, Mannone T. Metastases of the heart and pericardium. *G Ital Cardiol.* 1997; 27 (12): 1252-5.
4. Reynen K, Kockeritz U, Strasser RH. Metastases to the heart. *Ann Oncol.* 2004; 15: 375-81.
5. Bussani R, De-Giorgio F, Abbate A, Silvestri F. Cardiac metastases. *J Clin Pathol.* 2007; 60; 27-34.
6. Endo A, Ohtahara A, Kinugawa T, Mori M. Characteristics of 161 patients with cardiac tumors diagnosed during 1993 and 1994 in Japan. *Am J Cardiol.* 1997; 79: 1708-11.
7. Gibbs P, Cebon JS, Calafiore P, Robinson WA. Cardiac metastases of malignant melanoma. *Cancer.* 1999; 85: 78-84.
8. Glancy DL, Roberts WC. The heart in malignant melanoma: a study of 70 autopsy cases. *Am J Cardiol.* 1968; 21: 555-71.
9. Chen RH, Gaos CM, Frazier OH. Complete resection of a right atrial intracavitary metastatic melanoma. *Ann Thorac Surg.* 1996; 61: 1255-7.
10. Thomas-de-Montpréville V, Nottin R, Dulmet E, Serraf A. Heart tumors in children and adults: clinicopathological study of 59 patients from a surgical center. *Cardiovasc Pathol.* 2007; 16: 22-8.
11. Tesolin M, Lapierre C, Oligny L, Bigras JL, Champagne M. Cardiac metastases from melanoma. *Radiographic.s* 2005; 25: 249-53.