

# Thrombolytic Therapy in Prosthetic Valve Thrombosis



Marcelo Katz, Flavio Tarasoutchi, Max Grinberg

Instituto do Coração do Hospital das Clínicas - FMUSP - São Paulo, SP - Brazil

The technological advances of current medicine have allowed the population greater longevity. Specifically in regard to heart valve diseases, the increased life expectancy has allowed the patients to undergo repeated surgical interventions, with an increasing indication for implantation of metallic valvular prostheses. Prosthetic valve thrombosis is a rare, highly lethal complication<sup>1-3</sup>, and cardiac emergency teams have little experience in managing prosthetic valve thrombolysis. Therefore, this updating report aimed at reviewing the major alternatives for treating an episode of thrombosis, presenting, in a practical way, the thrombolytic treatment as a feasible and effective alternative, when properly indicated.

**Prosthetic valve thrombosis: a diagnostic and therapeutic challenge** – The incidence of prosthetic valve thrombosis varies according to the following variables: efficacy of anticoagulation; type and location of the implanted prosthesis; and presence of atrial fibrillation<sup>1-4</sup>. In a meta-analysis published in 1994<sup>2,5</sup> with 13,000 patients with metallic prosthesis, the annual incidence of thrombosis was 0.2%, with thromboembolic events occurring at a rate of 1.8% per year. These incidences were much greater in patients receiving only antiplatelet agents (thrombosis in 1.6%, and thromboembolism in 8.2%). According to that study, in regard to location, patients with mitral prosthesis had a 2-fold greater risk for thrombosis than those with aortic prosthesis, and the metallic prosthesis in the tricuspid position had the greatest thrombogenicity. In addition, the caged metallic prosthesis was the most thrombogenic.

Obstruction of the prosthesis is more frequent during the first postoperative year. The clinical findings vary from lack of symptoms to extreme cases of cardiogenic shock. The most common symptoms are progressive dyspnea on exertion, lipothymia, and syncope. Systemic embolism and acute pulmonary edema may be the first manifestations of the disease.

The physical examination reveals new murmurs or a change in the pattern of the old murmur<sup>2,5</sup>. The best complementary examination to refine the diagnosis of thrombosis is transesophageal echocardiography, which allows elucidation of the obstructive mass, leading to a more accurate diagnosis<sup>6-8</sup>.

Reoperation, in such cases, increases the risk, with mortality rates ranging from 10% to 15% in some case series<sup>3,4,9,10</sup>. This surgical risk may be increased when the patient's clinical conditions

are unfavorable, such as in hemodynamic instability. Then, thrombolysis appears as an alternative treatment.

**Prosthetic valve thrombolysis: history** – In 1971, Luluaga et al<sup>11</sup> were the first to use the thrombolytic therapy in prosthetic valve thrombosis. Streptokinase was used for treating thrombosis of the tricuspid valve prosthesis. Three years later, Baille et al<sup>12</sup> reported the use of that thrombolytic agent in the aortic valve prosthesis. Since then, several cases of prosthetic valve thrombolysis have been reported, with varied rates of success and complication.

A review of approximately 200 reports on left-sided prosthetic valve thrombolysis<sup>4</sup> has shown the following: an initial success rate of 82%; thromboembolic events in 12% of the cases; stroke in 5 to 10% of the cases; mortality rate of 6%; greater bleedings in 5% of the cases; and recurrence of thrombosis in 11%. Table I shows a summary of such reports.

In 2000, Gupta et al<sup>1</sup> reported a series of 110 patients with thrombosis of the mitral (96 patients) and aortic (14 patients) prostheses undergoing thrombolysis, 108 of whom received streptokinase, and 2 received urokinase. The infusion dosage of streptokinase was a bolus of 250,000 U in 30 minutes, followed by 100,000 U/h. Doppler echocardiography was used to monitor the time of infusion of the thrombolytic agent and to assess its efficacy. The criteria for interrupting infusion were as follows: hemodynamic improvement, assessed on echocardiography; occurrence of major bleedings or hemorrhagic stroke; and infusion time of 72 hours. The clinical characteristics of these patients before thrombolysis varied greatly. Of the 110 patients, 3.6% were in functional class I (New York Heart Association), 19.1% in functional class II, 46.4% in functional class III; 24.5% in functional class IV; and 6.4% had cardiogenic shock or acute pulmonary edema. Atrial fibrillation was observed in 31.8%. The mean time of prosthesis implantation was 24 months, and the mean time of symptom onset was 14 days. Complete hemodynamic improvement was observed in 81.8% of the patients, partial improvement in 10%, and treatment failure in 8.2%. An embolic event occurred in 19.1% of the patients during treatment. The success of thrombolysis was not influenced by the age of the patients, the time of symptom onset, the time of surgery, and the type or position of the valve prosthesis. Atrial fibrillation was a predictor of embolic events.

In the literature, the experience with thrombolysis in tricuspid and pulmonary valve prostheses is smaller, but has shown that the procedure is safe and a good treatment option in patients with those conditions<sup>1,13,14</sup>. High rates of success and low rates of complication have been reported in thrombolysis of the mechanical prosthesis in the tricuspid position.

**Prosthetic valve thrombolysis: indication** – In 1998, the American consensus on valvular heart diseases was published<sup>15</sup>.

Mailing address: Marcelo Katz - Rua Fradique Coutinho, 1692/34 - 05416-002 - São Paulo, SP - Brazil - E-mail: mkatz@terra.com.br  
Received for publication: 09/22/2004  
Accepted for publication: 12/16/2004  
English version by Stela Maris Costalonga

**Table I – Thrombolytic treatment in mitral and aortic prosthetic valves**

Date of the report	N of pts	N of episodes	Mitral/aortic	Embolism	Reop	Thrombolysis Death	Postop. Death
1988	58	62	23/39	11	14	6	4
1992	63	74	33/41	11	11	9	2
1993	12	12	9/3	0	0	0	0
1994	38	44	5/40	0	0	5	0
1994	8	8	1/7	1	0	0	0
Total	179	200	71/30	23 (12%)	25	20	6

N = number; Reop = reoperation; Postop = postoperative. Adapted from Lengyel et al<sup>4</sup>.

Although the consensus did not contraindicate valvular thrombolysis, the recommendations were limited, and the indications were restricted to a small number of patients. The selection of candidates for thrombolysis is frequently complicated, and significant elements to predict success or complications of the procedure lack.

In this context, more recent studies<sup>3,16,17</sup> have aimed at a better selection of candidates for thrombolysis. Echocardiography, particularly transesophageal echocardiography, has proved to be very important for the diagnostic and therapeutic decision<sup>3,6,7,8</sup>.

The largest study analyzing the role of echocardiography in prosthetic valve thrombolysis was recently published (2004)<sup>3</sup>. Considering that transesophageal echocardiography is the best examination to assess metallic prosthetic valves, allowing the detection and characterization of thrombi, the objective of this study was to determine the capacity of transesophageal echocardiography to predict the safety and efficacy of prosthetic valve thrombolysis and to establish the characteristics of the thrombi that increase the risk for thrombolysis.

An international multicenter registry of patients, involving the United States and carried out from 1985 to 2001, has been analyzed. In that registry, patients with prosthetic valve thrombosis underwent thrombolysis, and all of them had undergone transesophageal echocardiography before therapy. The registry comprised 107 patients, 79 of whom had mitral impairment, 13 had aortic impairment, and 15 had tricuspid impairment.

The agents used for fibrinolysis were streptokinase (54.7%), urokinase (17%), and rt-PA (28.9%). All fibrinolytic agents were administered for a longer period of time, and streptokinase was even used for 120 hours. The rt-PA dosage was a 10-mg bolus, followed by 90 mg in 2 to 6 hours.

All patients undergoing thrombolysis were submitted to transesophageal echocardiography before the procedure. Thrombi were visualized in 86% of the cases, and, in the rest of the patients, the inclusion criterion was valvular obstruction detected on Doppler. The thrombi were strictly assessed, and their area was calculated.

Thrombolysis was successfully performed in 85% of the cases. Complications were observed in 17.8% (19) of the patients, and death in 5.6%. Of the patients with complications, 18 had mitral valve impairment, and one had aortic valve impairment. No complications were observed in patients with tricuspid valve thrombosis (tab. II).

Clinical and echocardiographic criteria were analyzed as predictors of complication after thrombolysis. Antecedent of stroke and size of the thrombus observed on the echocardiogram were independent predictors of complication related to the procedure. For each 1-cm<sup>2</sup> increase in the area of the thrombus, a 2.4-fold

**Table II – Complications of the thrombolytic therapy in prosthetic valves**

Type of complication	N (%)
Peripheral embolism	3.7%
CNS bleeding	1.9%
Stroke	2.8%
TIA	2.8%
Coronary embolism	2.8%
Bleeding with transfusion	3.7%
Death	5.6%
Embolic complications	14%
Any complication	17.8%

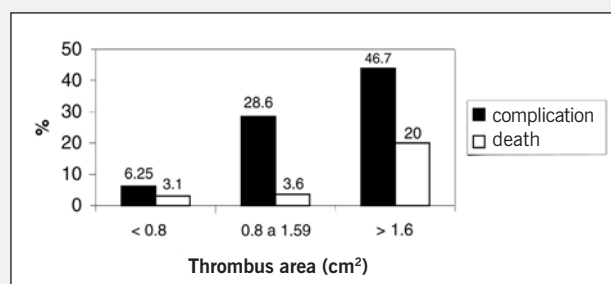
TIA- transient ischemic attack; CNS- central nervous system.  
Adapted from Tong et al<sup>3</sup>.

increase was observed in the rate of complications. The antecedent of stroke increased the risk of adverse events by 4.5 times.

The statistical analysis allowed the establishment of a 0.8 cm<sup>2</sup> cutpoint for the size of the thrombus, ie, patients with a thrombus area smaller than that value had a successful thrombolysis with no important adverse effects. The presence of a thrombus area >0.8 cm<sup>2</sup> was a predictor of complication, with sensitivity of 79% and specificity of 68%. Thrombus size <0.8 cm<sup>2</sup> was a predictor of success, independently of the patient's functional class. Figure 1 shows the relation between the dimensions of the thrombus and the rate of complications.

The correlation between the dimensions of the thrombus and the rate of adverse events is very important for the patient's management. The indication for thrombolysis has always taken into consideration the patient's functional class and the characteristics of the thrombus<sup>4,15</sup>. However, based on the results of this study, it is evident that the most important element for the therapeutic decision is the thrombus itself, allowing a broader selection of the candidates to thrombolysis, encompassing patients in all functional classes.

**Prosthetic valve thrombolysis: the rationale** - As already stated, prosthetic valve thrombosis can be treated clinically, with

Fig. 1 - Adapted from Tong et al<sup>3</sup>, PRO-TEE Registry, J Am Coll Cardiol. 2004; 43:1.



thrombolysis, or surgically, the physician in charge being responsible for this decision. When the thrombosis involves the tricuspid valve, and, more rarely, the pulmonary valve, thrombolysis is the therapy of choice. The studies have reported low complication rates in that group of patients<sup>11,13,14,18</sup>, independently of the clinical findings (asymptomatic, oligosymptomatic, or fully manifested heart failure). When thrombosis involves the left-sided valves (mitral and aortic), some aspects should be considered to choose the best treatment. All patients should undergo transesophageal echocardiography before definitive treatment<sup>3</sup>. The characteristics of the thrombus should be assessed. A thrombus  $<0.8 \text{ cm}^2$  predicts success of the thrombolysis<sup>3</sup>. Therefore, for patients in such conditions, independently of the functional class, ie, from asymptomatic to cardiogenic shock, and independently of the time of thrombosis installation, the thrombolytic therapy can be considered the top choice. This consideration is not valid if the patient has the antecedent of stroke or atrial fibrillation, because the risk of complications is greater. When the thrombus is  $>0.8 \text{ cm}^2$ , surgery should be considered the top choice, unless the clinical conditions are

unfavorable, such as cardiogenic shock, posing high surgical risk. In such conditions, thrombolysis, although potentially complicated, is justified. Also when cardiac surgery is not available, thrombolysis may be an option, mainly when clinical severity is extreme, and expectant management is not recommended.

Once thrombolysis is chosen, the greater experience with fibrinolytic agents makes streptokinase the first choice<sup>1,15</sup>. Its dosage should be a bolus of 250,000 U in 30 minutes, followed by 100,000 U/h. Doppler echocardiography should be used to monitor the time of infusion of the thrombolytic agent and to assess its efficacy. The thrombolytic agent should be interrupted at the 24 th hour of treatment, if no hemodynamic improvement (improvement in the gradient) occurs. It should be interrupted after 72 hours, even if the improvement is partial, or should be interrupted earlier, if the hemodynamic improvement is complete, ie, the transvalvular gradient returns to baseline values admitted as normal for mechanic prostheses. After thrombolysis, the patients should undergo anticoagulation with warfarin so that an INR between 3 and 4 could be reached for the aortic prosthesis, and between 3.5 and 4.5 for the mitral prosthesis<sup>15</sup>.

## References

- Gupta D, Kothari SS, Bahl VK et al. Thrombolytic therapy for prosthetic valve thrombosis: short and long term results. *Am Heart J.* 2000;140:906-16.
- Klugherz BD, Herrmann HC. Mechanical prosthetic valve thrombosis: case report and review of the literature. *J Thromb Thrombolysis.* 1998; 6:253-9.
- Tong AT, Roudaut R, Ozkan M, et al. Transesophageal echocardiography improves risk assessment of thrombolysis of prosthetic valve thrombosis: Results of the International PRO-TEE Registry. *J Am Coll Cardiol.* 2004;43:77-84.
- Lengyel M, Fuster V, Keltai M et al. Guidelines for management of left-sided prosthetic valve thrombosis: a role for thrombolytic therapy. *J Am Coll Cardiol.* 1997; 30:1521-6.
- Cannegieter SC, Rosendaal FR, Briet E. Thromboembolic and bleeding complications in patients with mechanical heart valve prostheses. *Circulation.* 1994; 89: 635-41.
- Parro A Jr, Carramona ML, Amaral CAF, et al. Trombose de prótese biológica mitral. importância do ecocardiograma transesofágico no diagnóstico e acompanhamento pós-tratamento. *Arq Bras Cardiol.* 2004; 82: 346 -59.
- Barbetseas J, Nagueh SF, Pitsavos C et al. Differentiating thrombus from pannus formation in obstructed mechanical prosthetic valves: an evaluation of clinical, transthoracic and transesophageal echocardiographic parameters. *J Am Coll Cardiol.* 1998; 32: 1410-7.
- Rinaldi CA, Heppell RM, Chambers JB. Treatment of left-sided prosthetic valve thrombosis: thrombolysis or surgery? *J Heart Valve Dis.* 2002; 11:839-43.
- Koller PT, Arom KV. Thrombolytic therapy of left-sided prosthetic valve thrombosis. *Chest.* 1995;108:1683-9. Review.
- Shapira Y, Vaturi M, Hasdai D, Battler A, Sagie A. The safety and efficacy of repeated courses of tissue-type plasminogen activator in patients with stuck mitral valves who did not fully respond to the initial thrombolytic course. *J Thromb Haemost.* 2003;1:725-8.
- Luluaga IT, Carrera D, D'Oliveira J et al. Successful thrombolytic therapy after acute tricuspid valve obstruction. *Lancet.* 1971; 1:1067-8.
- Baille Y, Choffel J, Sicard MP et al. Traitement thrombolytique des thromboses de prothese valvulaire. *Nouv Presse Med.* 1974; 3:1233.
- Hurrel DG, Schaff HV, Tajik A. Thrombolytic therapy for obstruction of mechanical prosthetic valves. *Mayo Clin Proc.* 1996; 71:605-13.
- Lopez HP, Loriga FMC, Hernandez KM et al. Thrombolytic therapy with recombinant streptokinase for prosthetic valve thrombosis. *J Card Surg.* 2002; 17:387-93.
- Bonow RO, Carabello B, Leon AC, et al. ACC/AHA Guidelines for the management of patients with valvular heart disease. ACC/AHA Task Force Report. *J Am Coll Cardiol.* 1998; 32: 1486-588.
- Ozkan M, Kaymaz C, Kirma C et al. Intravenous thrombolytic treatment of mechanical prosthetic valve thrombosis: a study using serial transesophageal echocardiography. *J Am Coll Cardiol.* 2000; 35:1881-9.
- Shapira Y, Herz I, Vaturi M et al. Thrombolysis is an effective and safe therapy in stuck bileaflet mitral valves in the absence of high-risk thrombi. *J Am Coll Cardiol.* 2000; 35: 1874-80.
- Shapira Y, Sagie A, Jortner R, Adler Y, Hirsch R. Thrombosis of bileaflet tricuspid valve prosthesis: clinical spectrum and the role of nonsurgical treatment. *Am Heart J.* 1999;137 (4 Pt 1):721-5.