

# Angiographic Morphologic Characteristics in Pulmonary Atresia with Intact Ventricular Septum

Marco Aurélio Santos, Vitor Manuel Pereira Azevedo

Rio de Janeiro, RJ - Brasil

## Objective

To determine the morphological and functional changes in the right ventricle in pulmonary atresia with intact ventricular septum (PAIVS) for assessing the candidates for the different therapeutic procedures currently available.

## Methods

Thirty-one patients underwent cineangiocardio-graphic study with axial projections. Their ages ranged from 1 to 50 days ( $x = 9.6$ ), and 28 of them were studied during the first month of life. The statistical analysis comprised the following: chi-square test, Kruskal-Wallis test for the mean and standard deviation, multiple regression, and the 95% confidence interval (95%CI) was calculated. The significance level adopted was  $\alpha \leq 0.05$ .

## Results

The patients were divided into 3 groups according to the angiographic morphology of the right ventricle (RV): group A – tripartite RV ( $n=16$ ); group B – bipartite RV ( $n=9$ ); and group C – unipartite RV ( $n=6$ ). The diameter of the tricuspid valve was  $10.28 \pm 2.67$  mm (A);  $7.82 \pm 3.41$  (B); and  $5.27 \pm 0.57$  (C) ( $P=0.0005$ ). Pulmonary atresia was of the valvular type in all group A patients and of the infundibular type in all group C patients ( $P<0.0001$ ). Coronary-cavitary connections were rare (2/16) in group A patients, but occurred in all group C patients ( $P=0.0006$ ), with retrograde opacity of the aorta (flow from the RV to the aorta) in 2 group A patients and in all group C patients ( $P=0.0003$ ). Three patients (2 in group C and 1 in group A) had right-ventricular-dependent coronary circulation. Isolated moderate/severe tricuspid regurgitation showed a tendency towards being more frequent in group A ( $P=0.0525$ ). The angle of the ductus arteriosus with the descending aorta was as follows:  $104.06 \pm 8.98$  in group A;  $79.17 \pm 33.08$  in group B; and  $39.0 \pm 6.52$  in group C ( $P=0.0016$ ). The correlation between the diameter of the tricuspid valve and the angle of the ductus arteriosus with the descending aorta was  $0.6568$  ( $P=0.0002$ ).

## Conclusion

Because of the heterogeneity of the morphology of the RV in patients with pulmonary atresia with intact ventricular septum, knowledge about all these data is required for selecting candidates for the different therapeutic procedures.

## Key words

pulmonary atresia, ductus arteriosus, congenital heart disease, prognostic factors, pulmonary valvotomy

Instituto Nacional de Cardiologia Laranjeiras – Rio de Janeiro  
Mailing address: Marco Aurélio Santos - Rua Bulhões de Carvalho,  
245/301 – Cep 22081-000 – Rio de Janeiro, RJ, Brazil  
E-mail: masantos@cardiol.br

Received 02/07/03

Accepted 8/25/03

English version by Stela Maris Costalonga

In 1839, Peacock had already reported 7 cases of pulmonary atresia with intact ventricular septum; however, Peacock attributed the first case reported to John Hunter<sup>1</sup> in 1783. Pulmonary atresia with intact ventricular septum accounts for 1 to 3% of the cardiac malformations; in the neonatal period, however, it accounts for 1/3 of the cyanotic heart diseases<sup>2,5</sup>. Its etiology has not yet been totally clarified, although some researchers claim inflammatory and infectious causes, as well as a certain degree of familial incidence<sup>6,8</sup>. Extracardiac anomalies are rare, although communications between the coronary arteries and the right ventricle may occur in approximately 50% of the cases<sup>9-14</sup>.

The first surgical approach to pulmonary atresia with intact ventricular septum was, according to Kirklin and Barrat-Boyes, attributed to Greenwold et al<sup>15</sup>, who proposed a strategy of treatment based on ventricular morphology. This treatment aimed at performing a pulmonary valvotomy in infants with a right ventricular cavity of normal dimensions. The palliative procedures developed by Glenn, Blalock-Taussig, and Waterston were later replaced by corrective techniques that aimed at clearing the right ventricular outflow tract and pulmonary valve, increasing pulmonary blood flow<sup>16-18</sup>, and, therefore, reestablishing the continuity of the right ventricle with the pulmonary artery.

Since the beginning, all surgical efforts and attempts have undergone several changes; however, the selection of patients for surgery has always been based on the size of the right ventricular cavity, anatomy and function of the tricuspid valve, and the presence of coronary-cavitary connections<sup>3,19-30</sup>. The following surgical techniques have been used: valvotomy with hypothermia or cardioplegia with cardiopulmonary by-pass; pulmonary valvectomy; and transannular patch<sup>3,19-30</sup>.

With the development of interventional techniques for the pediatric patient, a new alternative for the treatment of this malformation appeared with cardiac catheterization. Due to its effectiveness and low incidence of complications, it has been increasingly regarded as a very attractive form of treatment for a great number of investigators<sup>31-41</sup>.

Through angiographic analysis, our study aimed at providing indispensable information for the selection of candidates to the different alternatives of treatment currently available for this malformation.

## Methods

Over a period of 10 years, 31 patients with pulmonary atresia and intact ventricular septum were studied from the angiocardio-graphic point of view. The patients' ages ranged from 1 to 50 days ( $x=9.6$ ), 28 being studied in the first month of life. Nineteen patients were males.

Right ventriculography performed in the caudocranial and lateral projections aimed at evidencing: 1) the degree of tricuspid regurgitation; 2) the diameter of the tricuspid valve<sup>42</sup>; 3) presence of coronary-cavitary connections and right ventricular-dependent coronary circulation (severe proximal stenoses in the native coronary territory, mainly anterior descending and circumflex arteries – complete obstructions in proximal points of the native coronary circulation – fistula between the native coronary territory and the right ventricle – absence of connection of the left coronary artery with the aorta, and the origin of the pulmonary artery); and 4) right ventricular morphology, according to Goor and Lillehei<sup>43</sup> and Bull et al<sup>44</sup>.

Left ventriculography performed in the elongated left anterior oblique projection aimed at the following: 1) assessment of the size and configuration of the left ventricle; 2) opacity of the aorta and, based on its visualization, determination of the angle formed by the ductus arteriosus and the descending aorta; 3) visualization of the right and left coronary arteries and establishment of the type of ventricular perfusion (anterograde: from the aorta to the right ventricle during diastole).

The dichotomic data were assessed with the  $\chi^2$  (chi-square) test and calculating the 95% confidence interval (95%CI). The descriptive data were expressed as mean  $\pm$  standard deviation, and the Kruskal-Wallis test was used. The continuous variables were correlated using multiple regression. The significance level of  $\alpha = 0.05$  was adopted.

## Results

Age at the time of cardiac catheterization was as follows: up to 7 days of life, 23 patients; between 8 and 30 days of life, 5 patients; between 31 and 50 days of life, only 3 patients.

According to the type of right ventricular morphology on the angiocardiographic study<sup>44</sup>, the 31 patients were divided into 3 groups: group A) comprised 16 patients with tripartite right ventricular morphology (inlet portion, trabecular portion, and outlet portion). In 1 patient, the tricuspid valve was dysplastic (fig. 1-C). Only 1 patient in group A did not have tricuspid regurgitation (fig. 2-A). The only patients in whom coronary-cavitary connections were observed had a tricuspid valve diameter smaller (7.2 and 8.7 mm) than the mean in the group. In 1 patient, opacity of the aorta occurred mainly through the right coronary artery (fig. 2-A). In all patients, pulmonary atresia was due to an imperforate valve (fig. 1), and the angle formed by the ductus arteriosus and the descending aorta was obtuse in all patients (fig. 3-A and 4). In this group, only 8 patients used prostaglandin. Group B) comprised 9 patients with bipartite right ventricular morphology (inlet and outlet portions). In 6 patients, tricuspid regurgitation was absent or mild (fig. 5-A). In 2 patients, the opacity of the aorta was retrograde (from the right ventricle to the aorta) and occurred through both coronary arteries (fig. 5-B); in one of them, significant stenosis was observed in the coronary-cavitary/left coronary connection, and was considered right ventricular-dependent coronary circulation (fig. 2-B). The tricuspid valve diameter of these 2 patients was smaller (5.3 and 5.8 mm) than the mean in the group. In 3 patients, the segment with atresia was not at the level of the imperforate valve, and the infundibulum came to a dead end (fig. 2-B and 5-A). In 2 patients, the ductus arteriosus had a completely distinct morphology: it was thin,

tortuous, and formed an acute angle with the descending aorta (fig. 3-B). In the 3rd patient, the opacity of the aorta did not allow visualization of the ductus arteriosus. Of the 9 patients, 6 were using prostaglandin. Group C) this group was characterized in the angiographic study by nonopacity of the infundibular and trabecular portions, the right ventricle being reduced to only its inlet portion (unipartite). Two patients had moderate to severe tricuspid regurgitation (fig. 2-C). Retrograde coronary perfusion occurred as follows: through both coronary arteries in 2 patients; through the left coronary artery in 2 patients; and, through the right coronary

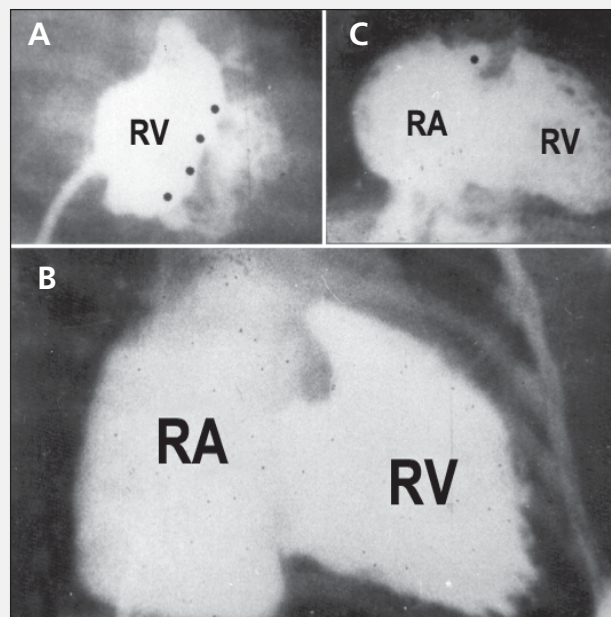


Fig. 1 – Right ventriculography in the anteroposterior projection in 3 group A patients. In all patients, the right ventricle comprises 3 portions: inlet, trabecular, and outlet. In A) tricuspid regurgitation is absent or mild with a clear separation between the inlet and the trabecular portions (asterisks); in B) the regurgitation is moderate to severe with a well-developed right ventricle; in C) the tricuspid valve is dysplastic, with moderate to severe regurgitation (the right atrial appendage and the inferior vena cava are opaque). All patients had pulmonary atresia due to imperforate valve.

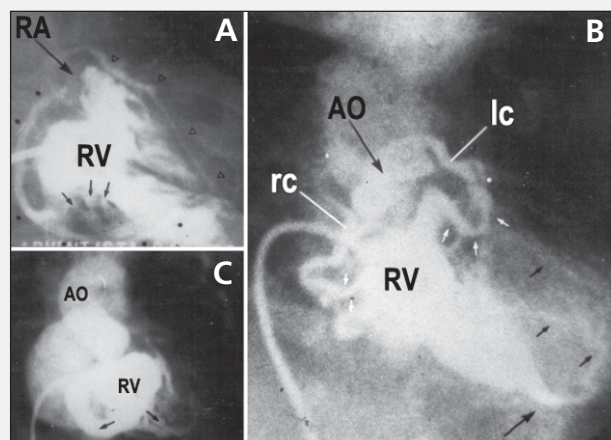


Fig. 2 – Right ventriculography in the anteroposterior projection. In A) pulmonary atresia is due to imperforate valve. Note the great development of coronary-cavitary connections (arrows), originating from the inlet and trabecular portions, with the right and left coronary arteries opaque; in B) pulmonary atresia is infundibular. The tricuspid valve has very reduced dimensions. The white arrows point to coronary-cavitary connections, which communicate with the right and left coronary arteries. Note the stenosis in the myocardial sinusoid/left coronary junction (asterisk); in C) the right ventricle is reduced only in its inlet portion. The tricuspid valve has reduced dimensions. The aorta is densely opaque due to the huge myocardial sinusoid/right coronary communication.

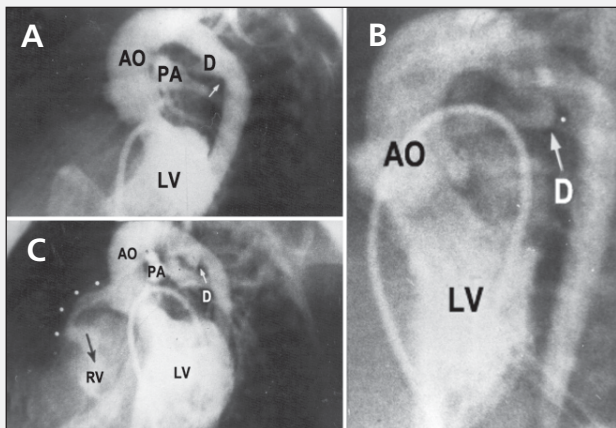


Fig. 3 – Left ventriculography in the left anterior oblique projection. In A) the aorta is opaque, allowing visualization of the pulmonary trunk through the ductus arteriosus, which is undergoing the closure process and forms with the descending aorta an obtuse angle (arrow); in B) a ductus arteriosus with morphologic characteristics completely distinct from those of the previous example. It is long, thin, tortuous, and forms with the descending aorta an acute angle (asterisk); in C) the ductus arteriosus is thin, is in a closing phase, and forms with the descending aorta an acute angle (arrow). In this patient, the aorta is opaque allowing visualization of the abnormally dilated coronary artery (asterisks) and of the right ventricle producing a system of massive bidirectional flow (coronary artery – right ventricle; right ventricle – coronary artery).

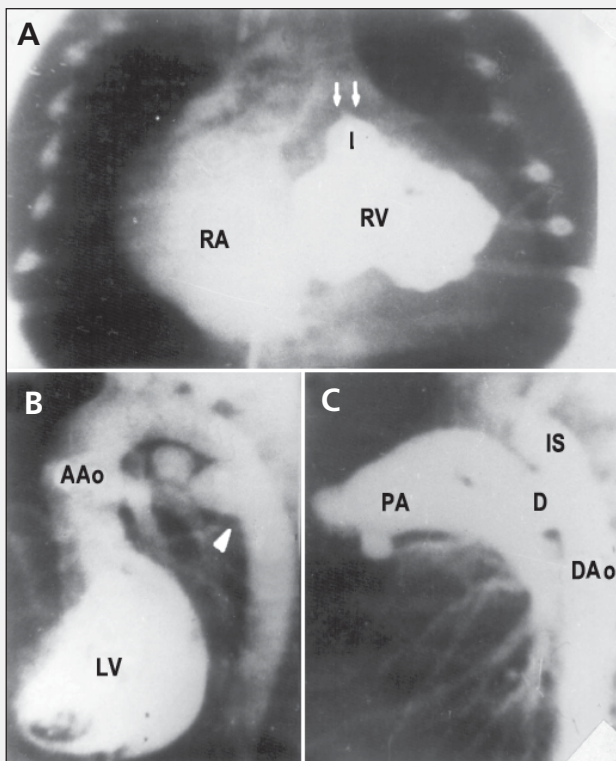


Fig. 4 – A) Right ventriculography in the anteroposterior projection showing pulmonary atresia due to imperforate valve (white arrows); B) left ventriculography in the left anterior oblique projection with opacity of the aorta: clear visualization of a huge ductus arteriosus in the closing phase, forming with the descending aorta an obtuse angle (arrow); C) aortography after infusion of prostaglandin E1, which causes an accentuated dilation of the ductus arteriosus and the pulmonary trunk and branches. With opacity of the pulmonary trunk, the pulmonary leaflets are clearly visualized, confirming the imperforate valve.

artery in the 2 remaining patients. Anterograde coronary perfusion could not be identified in 1 patient. In another patient (fig. 3-C), opacity of the right ventricle was possible starting at the aorta, due to the great dimension of the coronary-cavitary connection, forming a fistula that allowed deviation of the flow of this vessel to the right

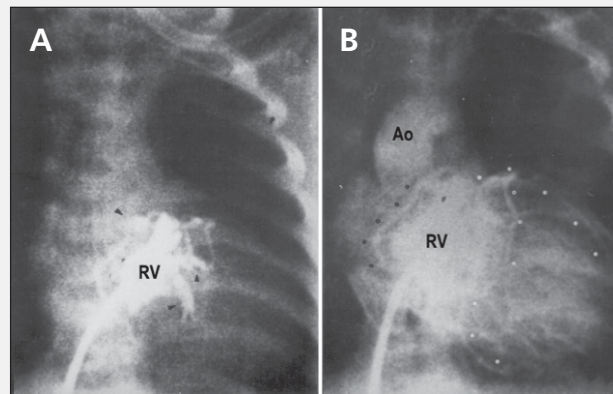


Fig. 5 – Injection of the contrast medium in a minute right ventricle in the anteroposterior projection. A) Note the lack of opacity of the trabecular portion, the presence of coronary-cavitary connections (arrows) originating from the inlet and infundibular portion, and the right and left coronary arteries beginning to become opaque; B) immediately after the right (dark circles) and left (trunk, anterior descending, and circumflex – white circles) coronary arteries become opaque, the ascending aorta is clearly visualized. The dimensions of the tricuspid valve are reduced with absent to mild regurgitation.

ventricular cavity. This observation was confirmed by the finding of an oximetric difference between the right ventricle and the right atrium. This and another patient had right ventricle-dependent coronary circulation. The morphology of ductus arteriosus could not be shown in 1 patient. In all patients, the ductus arteriosus formed an acute angle with the descending aorta (fig. 3-C). All patients in this group used prostaglandin.

The results are shown in tables I and II. Moderate to severe tricuspid insufficiency showed a tendency to be more frequent in group A. Group C was characterized by the presence of coronary-cavitary connections with retrograde coronary perfusion of the right ventricle to the aorta during systole in all patients. The site of pulmonary atresia was valvular in all group A patients (95% CI – 75.9% to 100%) and infundibular in all group C patients (95% CI – 51.7% to 100%) ( $P < 0.0001$ ). The tricuspid valve diameter was smaller ( $6.66 \pm 1.76$  mm) when tricuspid insufficiency was absent or mild, and greater ( $10.67 \pm 3.25$  mm) when tricuspid insufficiency was moderate or severe ( $P = 0.0009$ ). The angle between the ductus arteriosus and the descending aorta was obtuse ( $104.06^\circ \pm 8.98^\circ$ ) in group A and acute ( $39.00^\circ \pm 6.52^\circ$ ) in group C ( $P = 0.0016$ ). The correlation between the tricuspid valve diameter and the angle formed by the ductus arteriosus and the descending aorta was 0.6568 ( $P = 0.0002$ ) (fig. 6).

## Discussion

The greatest morphofunctional changes in pulmonary atresia with intact septum are related to the tricuspid valve, trabecular portion, and right ventricular outlet. Because in pulmonary atresia with intact septum no communication between the right ventricle and the pulmonary trunk exists, the possibility of a patient surviving after birth is very small. Therefore, pulmonary blood is supplied through the ductus arteriosus, and, occasionally, through systemic pulmonary collaterals. The problem is that, in almost all cases, the ductus arteriosus begins the closure process right after birth, and, occasionally, it may remain functional after the 30th day of extrauterine life.

In recent years, several investigators<sup>45,46</sup> have emphasized



the importance of the development of ductus arteriosus in congenital heart diseases, and, particularly, in the critical obstructions of the right ventricular outflow tract, in which the persistence of ductus arteriosus is an indispensable condition for survival<sup>47,48</sup>. Ductus arteriosus has been described as a small-caliber, tortuous vascular structure, which forms with the descending aorta an angle smaller than 90°<sup>49</sup>. These characteristics differ completely from those observed in the normal newborn, who, due to the direction of the fetal flow, has a large-caliber ductus arteriosus, which, in its junction with the descending aorta, forms an angle greater than 90°.

Contrary to that which has been reported in the literature, we have observed patients with pulmonary atresia with intact septum, who, on the angiocardigraphic study, have a normally developed ductus arteriosus, forming an obtuse angle with the descending aorta<sup>7</sup>.

In our case series, 5 of the 6 patients in group C had a ductus arteriosus with the classic morphology reported in the literature. When pulmonary obstruction is completed early during fetal life,

the ductus arteriosus may change its usual morphology, reduce its caliber, increase its tortuosity, and the angle between the pulmonary artery and the descending aorta may change, such that it is no longer obtuse. This change in its configuration could be explained by the absence of normal anterograde flow from the pulmonary artery to the aorta since the earliest phases of fetal life. The flow would occur only from the aorta to the pulmonary artery. This abnormal ductal morphology is also observed in patients with pulmonary atresia with ventricular communication, in whom pulmonary atresia is postulated to occur in even earlier phases of fetal life. On the other hand, all the 16 group A patients had ductus arteriosus of larger caliber, which formed an obtuse angle with the descending aorta. In these cases, the obstruction at the level of the pulmonary valve certainly became progressively more severe during fetal life, and, at birth, the pulmonary valve was not perforated as a final result of this process.

Therefore, pulmonary atresia of the membranous type with imperforate valve is more frequently found in patients with pulmonary atresia with intact septum, who have a ductus arteriosus of usual morphology, forming an obtuse angle with the descending aorta. On the other hand, in patients with ductus arteriosus of anomalous morphology, atresia of the infundibular muscular type is more frequently found. The difference in age between patients in group A (older) and those in groups B and C is noteworthy, and may be due to the greater severity of the clinical findings in the patients of the latter groups, who had less favorable anatomies.

As all neonates with congenital heart disease with pulmonary atresia in whom the pulmonary flow depends on the permeability of the ductus arteriosus, patients with pulmonary atresia with intact septum should be maintained under continuous infusion of prostaglandin until definition of the therapeutic strategy<sup>50,53</sup>. The effects of the action of prostaglandins on the angiographic morphology are little known and cannot be ruled out. Due to the important vasodilating effect of prostaglandins on the pulmonary artery and ductus arteriosus, it is speculated that a tendency exists towards a reduction in the angle formed by the ductus arteriosus

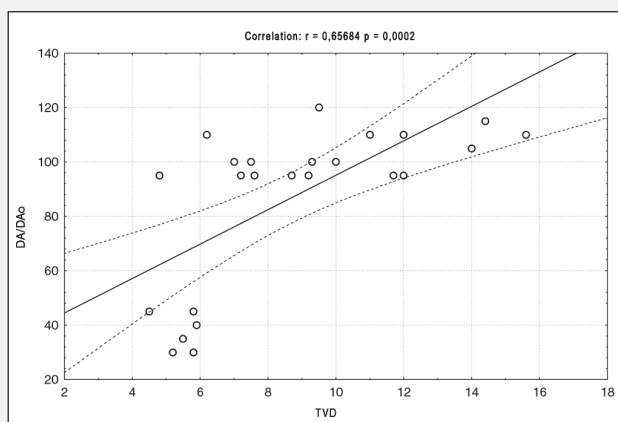


Fig. 6 – Correlation between the tricuspid valve diameter and the angle between the ductus arteriosus and the descending aorta using the multiple regression method. TVD –tricuspid valve diameter; DA/DAo – angle formed by the junction of the ductus arteriosus and the descending aorta.

**Table I - Relative frequency, 95% confidence interval and significance of the angiographic characteristics in the groups**

	Relative frequency and 95%CI			p
	Group A - n = 16	Group B - n = 9	Group C - n = 6	
Mod/severe TI	68.7% (41.3/89.0)	33.3% (9.0/69.0)	16.7% (0.9/63.5)	0.0526
CCC	12.5% (2.2/39.6)	55.5% (22.6/84.6)	100% (51.7/100)	0.0006
Opac. Aorta	12.5% (2.2/39.6)	22.2% (3.9/59.8)	100% (51.7/100)	0.0003
Retrograde CP	12.5% (2.2/39.6)	22.2% (3.9/59.8)	100% (51.7/100)	0.0003
Anterograde CP	100% (75.9/100)	88.9% (50.7/99.4)	83.3% (36.5/99.1)	0.2916

n- number of patients; 95%CI- 95% confidence interval; mod/severe TI- moderate to severe tricuspid insufficiency; CCC- coronary-cavitary connection; opac. aorta- opacity of the aorta; retrograde CP- retrograde coronary perfusion; anterograde CP- anterograde coronary perfusion

**Table II - Mean, standard deviation, and significance of the continuous variables**

	Group A - n = 16	Group B - n = 9	Group C - n = 6	p
Age (days)	15.2 ± 14.9	3.8 ± 2.2	3.5 ± 1.5	0.0608
Weight (Kg)	3.30 ± 0.46	3.27 ± 0.38	3.05 ± 0.19	0.3750
Height (cm)	49.69 ± 1.85	49.67 ± 1.50	48.00 ± 2.83	0.4397
TV diameter	10.28 ± 2.67	7.82 ± 3.41	5.27 ± 0.57	0.0005
Â DA/desc. Ao	104.06 ± 8.98	79.17 ± 33.08	39.00 ± 6.52	0.0016

n- number of patients; TV diameter- tricuspid valve diameter; Â DA/desc Ao- angle formed by the ductus arteriosus and the descending aorta

and the descending aorta, consequent to reorientation of the increased flow from the aorta to the pulmonary artery.

In pulmonary atresia with intact septum, the major objective of the treatment is to promote clearance of the right ventricular outflow tract, either by thoracotomy or by the percutaneous route, aiming at stimulating the intracavitary flow, reducing the degree of hypertrophy, improving ventricular compliance, and enabling enlargement of the ventricular cavity to make biventricular correction feasible. In actual practice, however, the entire current literature agrees that these procedures are not indicated for all patients. This limitation is justified by the morphofunctional spectrum of these patients, thus the need for knowing the heterogeneity existing among patients with this disease.

In the selection of patients, the entire initial attention should be directed to the size or dimensions of the right ventricle. However, the difficulty resides in the importance given to the right ventricular size, because, unlike the left ventricle, the right ventricle does not have a geometrical model with which its volume can be reliably calculated. In addition, in pulmonary atresia with intact septum, the degree of opacity of the trabecular portion is variable, and, therefore, all measures used to calculate its real volume will certainly have an error in its correct estimate. Because of the distortions in right ventricular morphology, the assessment of its volume is accepted with some restrictions, as the formula by Simpson or Dodge cannot be correctly applied to hearts with a bizarre geometry. Due to the obstacle to inferring right ventricular volume, which is an important parameter in the selection of candidates for the different therapeutic procedures available, Zuberbuhler et al<sup>54</sup>, in an anatomic study, found a relation between the tricuspid valve diameter and right ventricular size, the increase in the tricuspid valve diameter being considered an indicator of right ventricular enlargement.

More recently, researchers have been using the z index, which provides information about the sizes of the right ventricle and the tricuspid valve. The z index is obtained with the equation:  $z = \text{measured diameter} - \text{mean normal value} / \text{standard deviation of the mean normal diameter}$ <sup>27,29</sup>. Thus, the presence of a z index of the tricuspid valve ring or a diameter of the tricuspid valve < 70% of the normal or 70% of the diameter of the mitral ring represents a risk factor or failure factor for biventricular correction<sup>15,22</sup>.

In our material, a strong correlation was observed between the diameter of the tricuspid valve and the angle formed by the junction of the ductus arteriosus with the descending aorta. It is possible, therefore, through the analysis of the dimensions of the tricuspid valve, to infer the site of pulmonary atresia (valvular or

infundibular). To our knowledge, this correlation has not yet been reported in the literature.

Another problem, which has significant implications in the prognosis and in the diverse alternatives of treatment, regards the importance of coronary circulation in pulmonary atresia with intact septum<sup>55-59</sup>. This malformation is associated, in 20 to 50% of cases<sup>53</sup>, with coronary-cavitary connections between the right ventricular cavity and the coronary artery system<sup>60,61</sup>. These coronary-cavitary connections are considered persistent communications, which did not involute due to the development of right ventricular suprasystemic pressure during intrauterine life<sup>62</sup>. These abnormal communications during systole allow the nonoxygenated blood of the right ventricle to reach 1 or both coronary arteries, at the same time preventing or hampering its diastolic filling, due to a delay in right ventricular ejection<sup>63</sup>. Considerable histopathologic evidence exists that the myocardium of some neonates and infants may undergo ischemic damage of variable severity, because they have these coronary-cavitary connections between the right ventricle and the coronary circulation<sup>64</sup>. They certainly have right ventricle-dependent coronary circulation. These disorders of myocardial perfusion may already exist during intrauterine life, because these histopathologic alterations have been observed in neonates who die hours after birth<sup>65</sup>.

Therefore, patients with pulmonary atresia with intact septum, who have right ventricle-dependent coronary-cavitary connections, should not have their right ventricle decompressed, because decompression of the hypertensive right ventricle could lead the patient to a myocardial infarction, due to an effective reduction in the head of perfusion pressure.

Therefore, the morphologic characteristics delineated on angiography are fundamental to programming the therapeutic strategy to be adopted. It is worth noting that the type of strategy adopted fundamentally depends on the experience of each surgical group.

In conclusion, pulmonary atresia with intact septum represents an important group of patients with cyanotic congenital heart disease in the neonatal period. The alternatives of treatment of this heterogeneous group require meticulous assessment of the sizes of the right ventricle and the tricuspid valve, and, mainly, the study of the coronary circulation in the form of right ventricle-dependent coronary circulation or other coronary anomalies. Although better results, not only surgical but also of interventional catheterization, have been recently reported in the literature, mortality still remains elevated.

## References

1. Peacock TB. Malformation of the heart: atresia of the orifice of the pulmonary artery. *Trans Pathol Soc Lond* 1869; 20: 61-8.
2. Fyler DA. Report of the New England Regional Infant Cardiac Program. *Pediatrics* 1980; 65: 376-461.
3. Joshi SV, Brawn WJ, Mee RBB. Pulmonary atresia with intact ventricular septum. *J Thorac Cardiovasc Surg* 1986; 91: 192-9.
4. Buckley LP, Dooley KJ, Fyler DC. Pulmonary atresia and intact ventricular septum in New England. *Am J Cardiol* 1976; 37: 124-9.
5. Freedom RM, Wilson GJ, Trusler GA, et al. Pulmonary atresia and intact ventricular septum. *Scand J Thorac Cardiovasc* 1983; 17: 1-28.
6. Chitayat D, McIntosh N, Fuoron JC. Pulmonary atresia with intact ventricular septum and hypoplastic right heart in sibs: a single gene disorder? *Am J Med Genet* 1992; 42: 304-6.
7. Santos MA, Moll JN, Drumond C, et al. Development of the ductus arteriosus in right ventricular outflow tract obstruction. *Circulation* 1980; 62: 818-23.
8. Kutsche LM, Van Mierop LHS. Pulmonary atresia with and without ventricular septal defect: a different etiology and pathogenesis for the atresia in the two types? *Am J Cardiol* 1983; 51: 932-35.
9. Freedom RM, Harrington DP. Contributions of intramyocardial sinusoids in



- pulmonary atresia and intact ventricular septum to a right-sided circular shunt. *Br Heart J* 1974; 36: 1061-5.
10. Santos MA, Simões LC, Resende JC, et al. Implicações cirúrgicas da circulação coronariana na atresia pulmonar com o septo interventricular intacto. *Arq Bras Cardiol* 1986; 47: 193.
  11. Calder AL, Co EE, Sage MD. Coronary arterial abnormalities in pulmonary atresia with intact ventricular septum. *Am J Cardiol* 1987; 59: 436-42.
  12. Kasznica J, Ursell PC, Blanc WA, Gersony WM. Abnormalities of the coronary circulation in pulmonary atresia and intact ventricular septum. *Am Heart J* 1987; 114: 1415-20.
  13. Giglia TM, Mandell VS, Connor AR, et al. Diagnosis and management of the right ventricle dependent coronary circulation in pulmonary atresia with intact ventricular septum. *Circulation* 1992; 86: 1516-18.
  14. Rivera IR, Moises VA, Silva CC, et al. Circulação coronária dependente do ventrículo direito na atresia pulmonar com septo interventricular íntegro. Ausência da origem das artérias coronárias da aorta. *Arq Bras Cardiol* 1998; 71: 143-46.
  15. Kirklin JW, Barrat-Boyes BG. Pulmonary atresia and intact ventricular septum. In: Kirklin JW, Barrat-Boyes RG. *Cardiac Surgery*. 2<sup>nd</sup> ed. New York: Churchill Livingstone, Inc 1993: 1035-54.
  16. Brock RC, Campbell M. Valvotomy for pulmonary valvular stenosis. *Br Heart J* 1950; 12: 377-402.
  17. Swan H, Cleveland HC, Mueller H, Blount SG. Pulmonary valvular stenosis results and technique of open valvuloplasty. *J Thorac Surg* 1954; 28: 504-12.
  18. Gersony WM, Bernhard WF, Nadas AS, Gross RE. Diagnosis and surgical treatment of infants with critical pulmonary outflow obstruction. *Circulation* 1967; 35: 765-76.
  19. Bowman FO, Malm JR, Hayes CJ, et al. Pulmonary atresia with intact ventricular septum. *J Thorac Cardiovasc Surg* 1971; 61: 85-95.
  20. Cobanoglu A, Metzdorff MT, Pinson CW, et al. Valvotomy for pulmonary atresia with intact ventricular septum: a disciplined approach to a functioning right ventricle. *J Thorac Cardiovasc Surg* 1985; 89: 482-90.
  21. Foker JE, Braun EA, St. Cyr JA, et al. Management of pulmonary atresia with intact ventricular septum. *J Thorac Cardiovasc Surg* 1986; 105: 406-27.
  22. Hanley FL, Sade RM, Blackstone EH, Kirklin JW, Freedom RM, Nanda NC, and the Congenital Heart Surgeon's Society. Outcomes in neonatal pulmonary atresia with intact ventricular septum. *J Thorac Cardiovasc Surg* 1993.
  23. Santos MA, Simões LC, Müller RE, et al. Pulmonary atresia and intact ventricular septum: Relationship between right ventricle and ductus arteriosus morphology. 20<sup>th</sup> International Congress of Pediatric of the International Pediatric Association 1992; 192.
  24. Hawkins JA, Thorne JK, Boucek MM et al. Early and late results in pulmonary atresia and intact ventricular septum. *J Thorac Cardiovasc Surg* 1990; 100: 492-7.
  25. Leung MP, Mok CK, Lee J et al. Management evolution of pulmonary atresia and intact ventricular septum. *Am J Cardiol* 1993; 71: 1331-6.
  26. Mc Caffrey FM, Leatherbury L, Moore HV. Pulmonary atresia and intact ventricular septum: definitive repair in the neonatal period. *J Thorac Cardiovasc Surg* 1991; 102: 617-23.
  27. Moulton AL, Bowman FO, Edie RN, et al. Pulmonary atresia with intact ventricular septum – a 16 years experience. *J Thorac Cardiovasc Surg* 1979; 78: 527-36.
  28. Murphy DA, Murphy DR, Guibbons JE, Dobbell ARC. Surgical treatment of pulmonary atresia with intact ventricular septum. *J Thorac Cardiovasc Surg*, 1971; 62: 213-19.
  29. Steinberger J, Berry JM, Bass JL, et al. Results of a right ventricular outflow patch for pulmonary atresia with intact ventricular septum. *Circulation* 1992; 86: 167-75.
  30. Fedderly RT, Lloyd TR, Mendelsohn AM, Beekman RH. Determinants of successful valvotomy in infants with critical pulmonary stenosis or membranous pulmonary atresia and intact ventricular septum. *J Am Coll Cardiol* 1995; 25: 460-5.
  31. Qureshi AS, Rosenthal E, Tynan M, et al. Transcatheter laser-assisted balloon pulmonary valve dilatation in pulmonary valve atresia. *Am J Cardiol* 1991; 67: 428-31.
  32. Latson LA. Non surgical treatment of neonatal with pulmonary atresia and intact ventricular septum by transcatheter puncture and balloon dilatation of atretic valve membrane. *Am J Cardiol* 1991; 68: 277-9.
  33. Parsons JM, Rees MR, Gibbs JL. Percutaneous laser valvotomy with balloon dilatation of the pulmonary valve as a primary treatment for pulmonary atresia. *Br Heart J* 1991; 66: 36-8.
  34. Rosenthal E, Qureshi AS, Chan KC, et al. Radiofrequency-assisted balloon dilatation in patients with pulmonary valve atresia and intact ventricular septum. *Br Heart J* 1993; 69: 347-51.
  35. Piéchaud JF, Ladeia AM, DA Cruz E, et al. Perforation-dilatation des artères pulmonaires à septum interventriculaire intact chez le nouveau-né et le nourrisson. *Arch Mal Coeur Vaiss* 1993; 86: 581-6.
  36. Justo RN, Nykanen DG, Williams WG, et al. Transcatheter perforation of the right outflow tract as initial therapy for pulmonary valve atresia and intact ventricular septum in the newborn. *Cathet Cardiovasc Diagn* 1997; 40: 408.
  37. Fontes VF, Esteves CA, Braga SL, et al. Atresia pulmonar com septo íntegro. Perfuração com radiofrequência. *Arq Bras Cardiol* 1995; 64: 231-3.
  38. Alwi M, Geetha K, Bilkis AA, et al. Pulmonary atresia and intact ventricular septum percutaneous radiofrequency-assisted valvotomy and balloon dilatation versus surgical valvotomy and Blalock-Taussig shunt. *J Am Coll Cardiol* 2000; 35: 468-76.
  39. Gibbs JL, Blackburn ME, Uzun D, et al. Laser valvotomy with balloon valvuloplasty for pulmonary atresia with intact ventricular septum: Five years experience. *Heart* 1997; 77: 225-8.
  40. Ovaert C, Qureshi AS, Rosenthal E, et al. Growth of the right ventricle after successful transcatheter pulmonary valvotomy in infants with pulmonary atresia and intact ventricular septum. *J Thorac Cardiovasc Surg* 1998; 115: 1055-62.
  41. Pedra CAC, de Souza NL, Pedra SRFF, et al. Novas técnicas percutâneas para perfuração da valva pulmonar na atresia pulmonar com septo íntegro. *Arq Bras Cardiol* 2001; 77: 471-8.
  42. de Leval M, Bull C, Hopkins R, et al. Decision making in the definitive repair of the heart with small right ventricle. *Circulation* 1985; 72: 52-60.
  43. Goor DA, Lillehei CW. *Congenital malformation of the heart*. New York, 1975, Grune and Stratton Inc.
  44. Bull C, de Leval MR, Mercanti, et al. Pulmonary atresia and intact ventricular septum. A revised classification. *Circulation* 1982; 66: 266-72.
  45. Heyman MA, Rudolph AM. Effects of congenital heart disease on fetal and neonatal circulation. In *Neonatal Heart Disease*. Ed Fridman WF, Lesch M, Sonnenblick EH. Grune and Stratton Inc, New York and London, 1972, 105-10.
  46. Rudolph AM. *Congenital disease of the heart*. Year Book Publishing Co. Chicago, 1974, 172-92.
  47. Olley PM, Coceani F, Bodach E. E-type prostaglandins: A new emergency therapy for certain cyanotic congenital heart malformations. *Circulation* 1976; 53: 728-34.
  48. Heymann MA, Rudolph AM. Ductus arteriosus dilatation by prostaglandin E in infants with pulmonary atresia. *Pediatrics* 1977; 59: 325-31.
  49. Rudolph AM, Heymann MA, Spitznas V. Hemodynamic consideration in the development of narrowing of the aorta. *Am J Cardiol* 1972; 30: 514-19.
  50. Donahoo JS, Roland JM, Tan J, et al. Prostaglandin E as an adjunct to emergency cardiac operation in neonates. *J Thorac Cardiovasc Surg* 1981; 81: 227-31.
  51. Cobanoglu A, Metz Dorff MT, Pinson CW, et al. Valvotomy for pulmonary atresia with intact ventricular septum. *J Thorac Cardiovasc Surg* 1985; 89: 492-8.
  52. Milliken JC, Lacks H, Hellenbrand W, et al. Early and late results in the treatment of patients with pulmonary atresia and intact ventricular septum. *Circulation* 1985; 72: 61.
  53. Joshi VS, Brawn Wj, Mee, RBB. Pulmonary atresia with intact ventricular septum. *J Thorac Cardiovasc Surg* 1986; 91: 192-7.
  54. Zuberbuhler JR, Fricker FJ, Park SC, et al. Pulmonary atresia with intact ventricular septum. Morbid anatomy. In *Pediatric Cardiology*. Heart disease in the newborn. Ed Godman MJ, Marquis R. Churchill Livingstone, London, 1979.
  55. Patel RG, Freedom RM, Moes CAF, et al. Right ventricular volume determinations in 18 patients with pulmonary atresia and intact ventricular septum. *Circulation* 1980; 61: 428-36.
  56. O'connor WN, Cottrill CM, Johnson GL, et al. Pulmonary atresia with intact ventricular septum and ventricle coronary communications: surgical significance. *Circulation* 1982; 65: 805-12.
  57. Santos MA, Simões LC, Resende JC, et al. Implicações cirúrgicas da circulação coronariana na atresia pulmonar com septo interventricular intacto. *Arq Bras Cardiol* 1986; 47: 193.
  58. Sauer U, Binal L, Pilosoff V, et al. Pulmonary atresia with intact ventricular septum and major right ventricle-coronary "fistule": Selection of patients for surgery. 2<sup>o</sup> World Congress of Pediatric Cardiology 1985 (abstract): 115.
  59. Waldman JD, Lamberti JJ, Mathewson JW, George L. Surgical closure of the tricuspid valve for pulmonary atresia and intact ventricular septum and right ventricle to coronary artery communication. *Pediatric Cardiol* 1984; 5: 221-8.
  60. Grant RT, An unusual anomaly of the coronary vessels in the malformed heart of a child. *Heart* 1926; 13: 273-9.
  61. Elliot LP, Adams P, Edwards JE. Pulmonary atresia with intact ventricular septum. *Br Heart J* 1983; 25: 489-95.
  62. Williams RR, Kent GB, Edwards JE. Anomalous cardiac blood vessel communicating with the right ventricle. *Arch Pathol* 1951; 52: 480-7.
  63. Freedom RM, Harrington DP. Contributions of intramyocardial sinusoids in pulmonary atresia and intact ventricular septum to a right sided circular shunt. *Br Heart J* 1974; 36: 1060-9.
  64. Oppenheimer EH, Esterly JR. Some aspects of cardiac pathology. Eleven unusual coronary endoarteritis with congenital cardiac malformations. *Bull Johns Hopkins Hosp* 1966; 119: 343-9.
  65. Freedom RM, Benson L, Nilson GJ. The coronary circulation and myocardium in pulmonary and aortic atresia with an intact ventricular septum. In *Pediatric Cardiology* vol. 6. Ed Marcelletti C, Anderson RH, Becker A, Corno A, di Carlo D, Mazzene E 1986. Churchill Livingstone.