

## Fat Pulmonary Embolism During Orthopedic Surgery Monitored Through Transesophageal Echocardiogram

João Mansur Filho, Gustavo Luiz Gouvêa de Almeida Júnior, José Kezen Camilo Jorge, Serafin Gomes Sá Júnior, João Renato, Alcino Affonseca  
Hospital Samaritano - Rio de Janeiro, RJ - Brazil

Fat embolism syndrome (FES) is a known clinical situation, especially secondary to long bone trauma conditions. Bone marrow embolism for pulmonary circulation may cause changes in pulmonary function and right ventricular dysfunction, either through the release of chemical mediators from fracture locations, which change blood lipid solubility, causing coalition and subsequent pulmonary embolization, or through direct access of fat to venous circulation and, then, to lungs. A 72-year old female patient was submitted to an orthopedic surgery for femur fracture correction with placement of intramedullary rod. As the patient was aged, with coronary artery disease history and without possibility of a proper

preoperative stratification, as it was an urgent surgery, she was submitted to preoperative monitoring with transesophageal echocardiogram for global and segmental ventricular function assessment. During intrabone preparation for rod receiving (milling), a great amount of hyperechogenic (fig. 1), often forming small pieces (fig. 2), was seen entering through the right heart and reaching out pulmonary circulation. As the interatrial septum was complete, an exuberant contrast difference could be seen between right and left atrial content. There was no change of pulmonary, cardiac or hemodynamic function after procedure completion, and the patient had good postoperative evolution, being discharged afterwards.

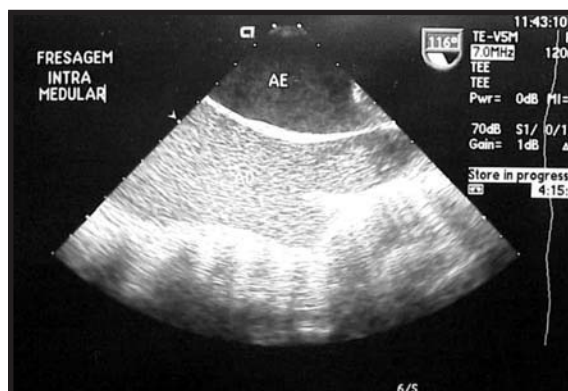

Fig. 1 - During intramedullary milling procedure, a great amount of hyperechogenic material fills out the whole right atrium

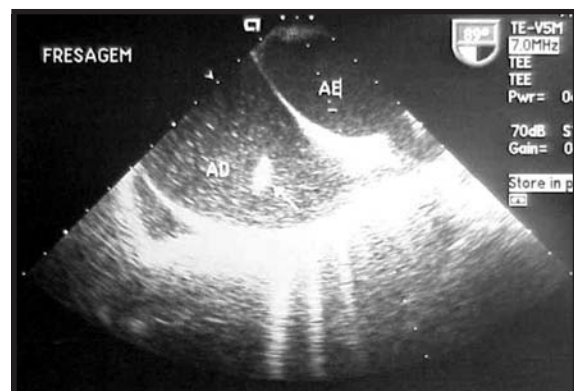


Fig. 2 - Marrow material coalescing in small pieces (arrow) were also seen passing through right heart