

## Radionuclide Imaging of Myocardium with Mental Stress in the Investigation of Thoracic Pain

Lívia Maria Lima da Silva, Gustavo Borges Barbirato, Cantídio Drumond Neto, Antonio Claudio Lucas da Nóbrega, Alexandro Coimbra, Claudio Tinoco Mesquita

Universidade Federal Fluminense, Hospital Universitário Antônio Pedro (HUAP); Hospital Pró-Cardíaco, Rio de Janeiro, RJ, Brazil.

Thoracic pain is a common symptom in emergency services, and stress radionuclide imaging represents one of the phases of risk stratification in these individuals. However, a group of patients with negative functional exams after physical or pharmacological stress develops myocardial ischemia during this psychological stress. Alterations in vascular tonus as a response to endogenous mechanisms are the physiopathologic basis for such alterations. We report a case that illustrates how mental stress radionuclide imaging has the potential to be used in the assessment of myocardial ischemia non-detected by conventional methods in patients with suspicion of ischemic thoracic pain.

### Introduction

In the emergency room, thoracic pain represents a hard-diagnosis entity. This difficulty results in inadequate discharge of carriers of myocardial ischemia syndrome (MIS), who will remain untreated and vulnerable to morbid events. Imaging exams have been playing an important role in the stratification of risk in patients that are suspected to be carriers of myocardial ischemia. Among the most widely used exams, radionuclide imaging is the one that bespeaks the most its value in diagnostic and prognostic evaluation of patients with thoracic pain<sup>1</sup>. Despite the fact that a radionuclide myocardial perfusion imaging is frequently associated with a risk for adverse events lower than 1% per year<sup>2</sup>, some patients with coronary arterial disease only have manifestation of ischemia when submitted to non-conventional ischemia induction techniques, such as psychological stress<sup>3</sup>. While the basis for the induction mechanism for perfusion alteration of radionuclide imaging during physical activity with intravenous dipyridamole is coronary vasodilatation, psychological stress causes epicardial coronary and microvascular vasoconstriction in patients with endothelial dysfunction and/or arteriosclerosis<sup>4</sup>. The use of radionuclide imaging in a patient under psychological stress and negative investigation for myocardial ischemia in the

emergency room by conventional methods has not been described yet.

### Case report

Female patient, 68 years old, Caucasian, was admitted in the emergency service with low intensity precordial discomfort in repose with duration superior to 30 minutes and associated with dyspnea and palpitations. The patient related similar previous episodes without diagnosis.

The physical exam identified no alterations, presenting blood pressure (BP) and heart rate (HR) discretely elevated (BP = 140 x 90 mmHg and HR = 88 bpm). Twelve-derivation electrocardiography showed diffuse unspecific alterations in ventricular repolarization, and myocardial necrosis markers' dosage was normal. Transthoracic echocardiography analysis revealed debt in the left ventricle (LV) relaxation and absence of global or segmental systolic dysfunction of LV. After the hypothesis of myocardial infarction was rejected, the patient was submitted to stratification with radionuclide imaging of myocardial perfusion after physical stress and in rest, with utilization of <sup>99m</sup>Tc-Sestamibi. One-day protocol was applied, initially in repose. In stress phase, the patient was submitted to ergometric test under run-away protocol (VO<sub>2</sub> maximum 36.75 ml/kg.min; Test duration: 11 min 12 sec; MET maximum: 10.5; FC maximum: 159 bpm e MVO<sub>2</sub> maximum: 31.54 ml O<sub>2</sub> 100g VE/min). The image was acquired approximately 90 minutes after the test. No perfusion, contractility or myocardial thickness defects were observed during exam (Figure 1). The patient was discharged asymptomatic and, thus, without a diagnosis for the described symptoms. Afterwards, she was referred to radionuclide imaging with sensorial stress, and application of Stroop method, which is an information processing test that employs the conflict word/color. This method consists of the appearance of successive images in a computer as the patients says out loud the name of the color of the visualized letters and listens to other color names in a headphone, which generates an hearing conflict<sup>5</sup>. During the exam, blood pressure was monitored continually and non-invasively by means of digital infrared photoplethysmography simultaneously to continuum derived 12-lead electrocardiographic assessment. <sup>99m</sup>Tc-Sestamibi was injected at the moment of maximum stress (2.5 minutes of protocol). Stress induction had a maximum duration of five minutes, and the respective image was obtained 60 minutes later with posterior comparison to previous repose period. There was no symptoms reproduction or electrocardiography alteration during sensorial stress. An effective hemodynamic response to stress was observed, with variation of: systolic

### Keywords

Radionuclide Imaging; Psychological Stress; Myocardial Ischemia.

#### Mailing address: Lívia Maria Lima da Silva •

Rua Presidente João Pessoa, 249 / 1206, Jardim Icarai – 24220-330, Niterói, RJ, Brazil

E-mail: limalisi26@yahoo.com.br

Manuscript received December 22, 2008; revised manuscript received May 8, 2009; accepted May 8, 2009.

## Case Report

blood pressure: + 43 mmHg (VR: 10-25 mmHg); diastolic blood pressure: +22 mmHg (VR: 5-15 mmHg); and heart rate: + 7 mmHg (VR: 5-15 mmHg). Radionuclide imaging of psychological stress demonstrated reversible perfusion defects in the segments concerning the anterior and inferior walls, interventricular apex and septum, as shown in Figure 2, results that suggest sensorial stress-induced myocardial ischemia.

The presence of sensorial stress-induced ischemic alterations motivated an anatomic evaluation through coronarygraphy, which showed a 40% lesion in the medium portion of anterior descending coronary artery, 30% lesion in the proximal portion of the second diagonal artery and 40% lesion in the proximal portion of the right coronary artery. An optimized medical treatment with ambulatory follow-up was chosen.

## Discussion

One of the advantages of radionuclide imaging with myocardial perfusion is the revelation of presence of ischemia in patients who did not present obstructive coronary disease<sup>6</sup>. The presence of stress-induced myocardial ischemia in patients with atypical anginous thoracic pain, but without obstructive coronary disease, is frequently associated with endothelial dysfunction<sup>7</sup>. Several experimental studies have contributed to a better understanding on the association between psychological stress and myocardial ischemia, with

emphasis given to the Psychophysiological Interventions in Myocardial Ischemia (PIMI) study, in which the different responses to physical and psychological stress of carriers of coronary arterial disease and the association of psychological stress ischemia with mortality are documented<sup>8</sup>. Psychological stress unleashes an increase in heart rate and in blood pressure, which are measured through stimulation of adrenergic sympathetic activity. In healthy individuals, the integer endothelium promotes a compensatory vasodilator response to sympathetic stimulus. In carriers of coronary arterial disease, whose physiopathologic basis is the endothelial dysfunction, this compensatory mechanism is damaged, which leads to a significant coronary vasoconstriction and to alterations in the myocardial offer and demand of oxygen<sup>9</sup>. An inappropriate response may cause ventricular contraction dysfunction, myocardial ischemia or cardiac rhythm disorders<sup>9</sup>. Due to physiopathologic differences between physical, pharmacological and psychological stress, individual variations in the response to each stimulus are expected. Studies that assessed the genetic variability as polymorphism of  $\beta_1$ -adrenergic receptors, in which patients possessed Ser49 allele homozygosis, demonstrated up to the triple of ischemia cases<sup>10</sup>. In practice, this fact influences the observation of individuals without ischemia that is detectable by conventional stress methods, presenting positivity only after submission to psychological stress. Such fact demonstrates

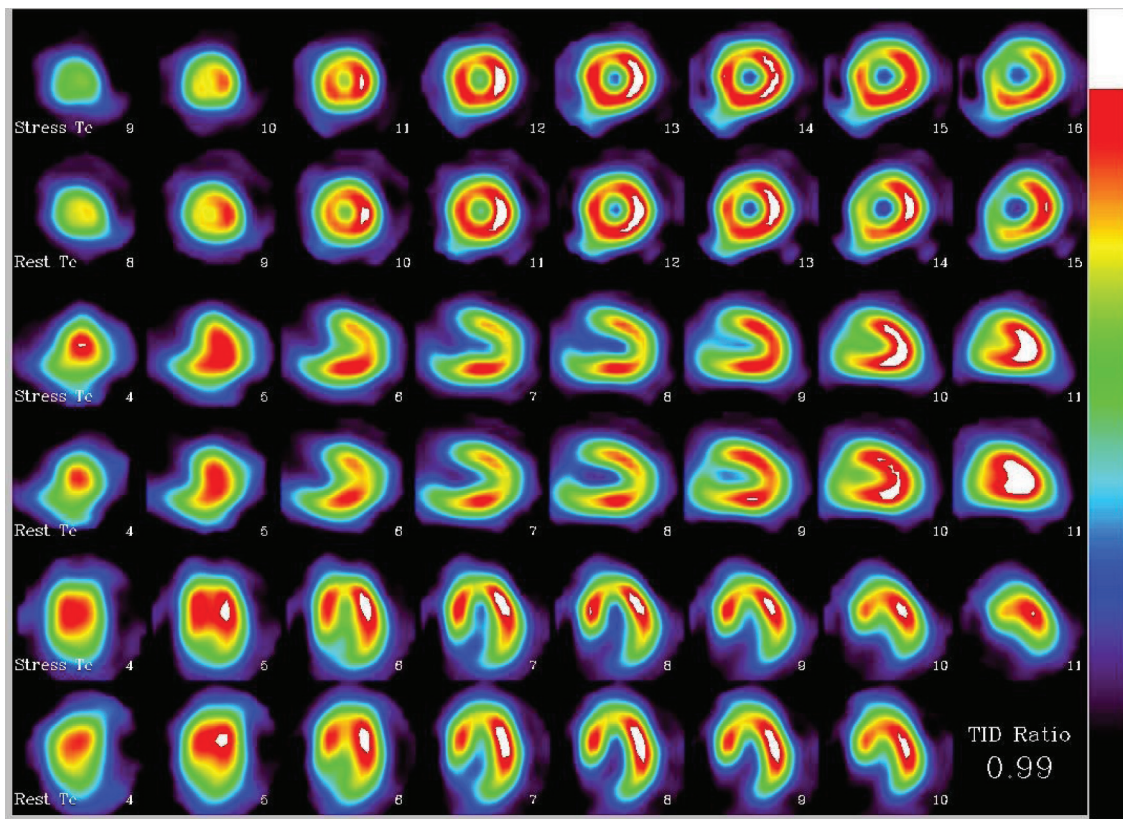
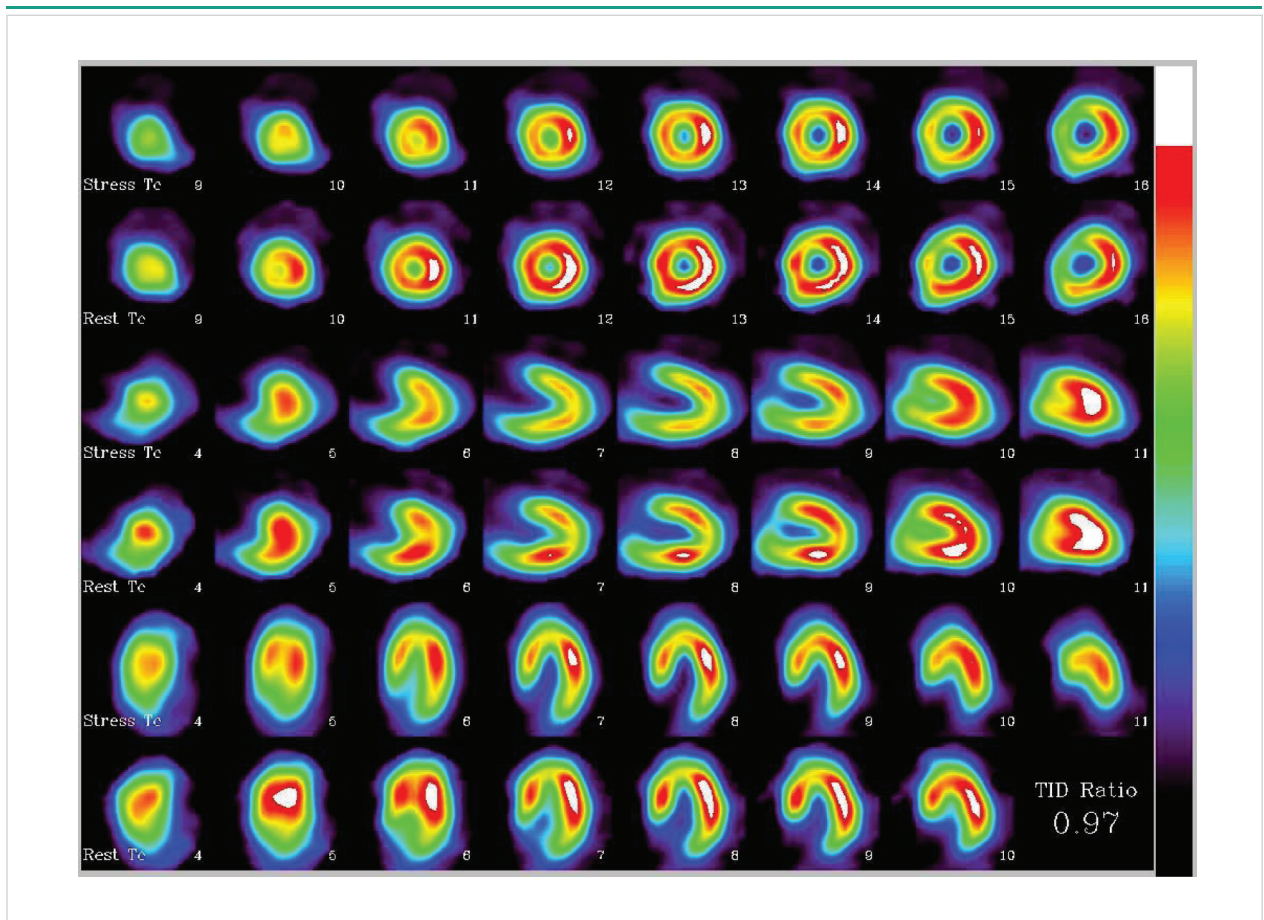


Fig. 1 – Radionuclide imaging of patient under physical stress and in repose, demonstrating left ventricle cuts without perfusion defects.



**Fig. 2** – Radionuclide imaging during psychological stress and in repose of left ventricle cuts, showing extended area of reversible perfusion defects in the left anterior descending coronary artery (LAD) site.

the applicability of this stress modality for the detection of underdiagnosed cases of myocardial ischemia in thoracic pain manifestations. In the abovementioned clinical case, the patient were under stress and had incipient coronary artery disease, but without significant obstruction of arterial light. The patient presented ischemic alterations in the radionuclide imaging only when submitted to psychological stress through Stroop Color method, which consolidates a cardiac etiology for the observed alterations. These data suggest a potential applicability of psychological stress as complementation of myocardial ischemia investigation in patients that present thoracic pain of inexplicable etiology. More studies are currently being conducted for the investigation of this new applicability of stress radionuclide imaging.

#### Potential Conflict of Interest

No potential conflict of interest relevant to this article was reported.

#### Sources of Funding

There were no external funding sources for this study.

#### Study Association

This article is part of the thesis of master submitted by Gustavo Borges Barbirato, from Hospital Pró-Cardíaco e Universidade Federal Fluminense - Hospital Universitário Antônio Pedro.

## References

1. Azevedo JC, Félix RCM, Corrêa PL, Barbirato GB, Dohmann FR, Silva PRD, et al. Prognóstico em médio prazo da cintilografia de perfusão miocárdica de estresse na unidade de dor torácica. *Arq Bras Cardiol.* 2007; 88: 602-10.
2. Hachamovitch R, Berman DS, Shaw LJ, Kiat H, Cohen I, Cabico JA, et al. Incremental prognostic value of myocardial perfusion single photon emission computed tomography for the prediction of cardiac death: differential stratification for risk of cardiac death and myocardial infarction. *Circulation.* 1998; 97 (6): 535-43.
3. Hassan M, York KM, Li Q, Lucey DG, Fillingim RB, Sheps DS. Variability of myocardial ischemic responses to mental versus exercise or adenosine stress in patients with coronary artery disease. *J Nucl Cardiol.* 2008; 15: 518-25.

## Case Report

4. Arrighi JA, Burg M, Cohen IS, Kao AH, Pfau S, Caulin-Glaser T, et al. Myocardial blood-flow response during mental stress in patients with coronary artery disease. *Lancet*. 2000; 356: 310-1.
5. Steptoe A, Vögele C. Methodology of mental stress testing in cardiovascular research. *Circulation*. 1991; 83 (4 Suppl): II-14-24.
6. Gibbons R. Noninvasive diagnosis and prognosis assessment in chronic coronary artery disease: stress testing with and without imaging perspective. *Circ Cardiovasc Imaging*. 2008; 1: 257-69.
7. Zeiher A, Krause T, Schächinger V, Minners J, Moser E. Impaired endothelium-dependent vasodilation of coronary resistance vessels is associated with exercise-induced myocardial ischemia. *Circulation*. 1995; 91: 2345-52.
8. Sheps DS, McMahon RP, Becker L, Carney RM, Freedland KE, Cohen JD, et al. Mental stress-induced ischemia and all-cause mortality in patients with coronary artery disease: results from the psychophysiological investigations of myocardial ischemia study. *Circulation*. 2002; 105: 1780-4.
9. Blumenthal JA, Jiang W, Waugh RA, Frid DJ, Morris JJ, Coleman RE, et al. Mental stress-induced ischemia in the laboratory and ambulatory ischemia during daily life: association and hemodynamic features. *Circulation*. 1995; 92: 2102-8.
10. Hassan M, York KM, Li H, Li Q, Gong Y, Langae TY, et al. Association of  $\beta$ 1-adrenergic receptor genetic polymorphism with mental stress-induced myocardial ischemia in patients with coronary artery disease. *Arch Intern Med*. 2008; 168: 763-70.