

Circulatory Support in Cardiogenic Shock after Acute Myocardial Infarction

Humberto F. G. Freitas, Breno A. A. Falcão, Rafael C. Silva, Jamil C. Ribeiro, Luiz Guilherme C. Velloso, Fabio Sandoli de Brito Junior

Hospital São Camilo Pompéia, São Paulo, SP - Brazil

Mortality is high in patients with acute coronary failure and cardiogenic shock. The most commonly used device for hemodynamic support is the intra-aortic balloon, which, however, may be insufficient in patients with refractory cardiogenic shock. This is a case report of a patient complaining of two days of intense and oppressive chest pain, radiating to the left arm. The ECG showed ST elevation. The patient was submitted to angioplasty and stent implant in the anterior descending artery and developed cardiogenic shock refractory to vasoactive drugs and intra-aortic balloon. Hemodynamic measures were carried out and we chose to use an Impella® 2.5 device, by percutaneous route, for circulatory support.

Introduction

In patients with acute coronary failure and cardiogenic shock, mortality is 55% to 73%, even with use of coronary reperfusion and intra-aortic balloon^{1,2}. Immediate reversal of tissue hypoperfusion is essential for the preservation of other organs during the period required for myocardial functional recovery after coronary reperfusion. The most frequently used device for hemodynamic support is the intra-aortic balloon (IAB), which, however, may be insufficient in patients with refractory cardiogenic shock. Several other mechanical circulatory support devices have appeared to allow patient hemodynamic improvement during ventricular recovery after acute ischemic injury.

The Impella® 2.5 device (Abiomed) is a catheter pump with maximum axial flow of 2.5 L/min, implanted in the left ventricle and ascending aorta by transcatheter femoral route^{3,4}. Several studies have shown Impella® 2.5 effectiveness in patients with cardiogenic shock after acute myocardial infarction, and compare this device with the IAB in the treatment of this hemodynamic disorder.

Keywords

Coronary artery disease; shock, cardiogenic; myocardial infarction; myocardial reperfusion.

Mailing Address: Felício Gonçalves de Freitas •

Av. Dr. Enéas de Carvalho Aguiar, 44, Pinheiros. Postal Code 05403000, São Paulo, SP - Brazil

E-mail: dclfreitas@incor.usp.br

Manuscript received June 01, 2011; manuscript revised September 23, 2011; accepted November 17, 2011.

Case Report

The patient was a 68-year old woman from São Paulo, with a two-day picture of recurring, intense and oppressive chest pain, radiating to left arm, eventually associated with nausea, vomiting and cold sweats. After the initial evaluation was carried out by electrocardiography (ECG) and cardiac enzyme assessment, she was admitted to the coronary unit with a diagnosis of acute coronary syndrome without ST elevation, blood pressure (BP) of 120/80 mmHg, heart rate of 100 bpm, regular heart rhythm with normal heart sounds and pulmonary rales at auscultation.

In the first hours after admission, she had recurrence of chest pain, and a new ECG showed ST-segment elevation in the anterior wall. She developed severe dyspnea, cold sweats and pallor, with a BP of 90/60 mmHg, heart rate 110 bpm and hypoxemia, requiring orotracheal intubation. She was referred to emergency coronary angiography, which showed a proximal occlusion in the anterior descending artery. Angioplasty was performed with stent implantation and abciximab infusion, with TIMI III coronary flow recovery. However, the patient persisted with clinical signs of cardiogenic shock; an infusion of dobutamine and norepinephrine was started, and then an IAB was implanted.

The patient began to experience episodes of cardiac arrest due to rapid ventricular tachycardia and ventricular fibrillation, which were reversed by electrical cardioversion. A Swan-Ganz catheter was used, and as the patient showed no clinical or hemodynamic improvement with the intra-aortic balloon and vasoactive drugs (VAD) support, we decided to implant the Impella® 2.5 device by percutaneous route for circulatory support. The device was implanted through the left femoral artery and catheter placement in the left ventricle was carried out with radiology. Hemodynamic measurements were performed with a Swan-Ganz catheter in four situations: with VAD, VAD and IAB, with the VAD and Impella® 2.5 and with the simultaneous use of VAD, IAB and Impella® 2.5 (Table 1).

After clinical stabilization, the patient was transferred to the intensive care unit and maintained with Impella® 2.5 implanted in the left femoral artery, with hemodynamic monitoring being carried out through the right femoral vein. The patient was maintained with dobutamine, norepinephrine, and maximum Impella® flow, remaining anticoagulated with continuous unfractionated heparin adjusted for clotting time of 260 seconds.

Table 1 – Hemodynamic data

	VAD	VAD and IAB	VAD and Impella®	VAD+IAB+Impella®
BP	100/60	105/60	110/65	100/60
HR	100	100	100	101
CI	1,1	1,6	2,2	1,6
CO	1,8	2,2	3,5	2,4
PCWP	24	19	15	18
CVP	16	15	14	15
SVo2	53	58	74	70

BP – blood pressure; HR – heart rate; CI – cardiac index; CO – cardiac output; PCWP – pulmonary capillary wedge pressure; CVP – central venous pressure; SVo2 – venous oxygen saturation; VAD – vasoactive drugs; IAB – intra-aortic balloon.

Two-dimensional echocardiography showed akinesia of the anterior and apical wall, and left ventricular ejection fraction estimated was at 25% by the Teichholz method.

The patient presented with gradual clinical improvement, and was extubated after 12 hours, remaining stable with a mean BP of 70 to 80 mmHg and pulmonary capillary wedge pressure of 15 mmHg. Laboratory tests showed maximum lactate levels of 48 mEq, CKMB mass of 180 and Troponin of 8.

She showed progressive improvement in the first days post-infarction, and the vasoactive drugs were withdrawn. On the second day post-infarction, she remained only with maximum-flow Impella® support, and angiotensin-converting enzyme inhibitors (ACEI) were prescribed. We decided to progressively decrease the Impella® flow, aiming at the removal of the device. After 45 hours of circulatory support, the patient showed stable hemodynamic measurements and the device was turned off and then removed without complications.

The patient remained stable and adequately tolerated ACEI and beta-blockers orally. She showed normalization of lactate and C-reactive protein levels. There was a significant decrease in serum hemoglobin to 6.8 mg/dL and hematocrit to 28%.

The patient was discharged after 10 days of admission, at NYHA functional class II.

Discussion

The mortality in patients with cardiogenic shock after acute myocardial infarction remains very high, with 50% of the patients dying within 48 hours^{5,6}. This group of patients require a rapid therapeutic and systemic response to improve cardiac output and maintain perfusion of other organs, with the use of vasoactive drugs. When the cardiogenic shock persists, the use of an IAB is mandatory, as it improves coronary and peripheral circulation, by improving left ventricular performance and decreasing peripheral vascular resistance.

However, in some patients with advanced shock and severe left ventricular dysfunction, the IAB may not be enough to improve cardiac output. In such cases, the use of percutaneous peripheral circulatory assistance is indicated, allowing the interruption of the cycle of ischemia, hypoperfusion and myocardial depression, enabling the maintenance of an adequate circulatory status until the spontaneous

improvement of contractile dysfunction occurs or coronary artery bypass graft surgery is performed.

In patients with refractory cardiogenic shock, there have been several reports of good results with the use of circulatory support devices such as the Tandem Heart® and the Impella®^{7,8}. The Impella® works as a centrifugal flow pump with a miniature axial flow pump inserted into the catheter to decompress blood from the left ventricle and deviate it into the ascending aorta. The device can be implanted quickly, it has easy maintenance and have few side effects, and promote a fast and significant improvement in hemodynamic conditions.

There have been reports in the literature showing the synergistic action of the association of IAB and Impella®, with improvement in oxygen extraction and coronary perfusion and oxygenation, as well as of the peripheral arteries; improvement in ventricular performance and decrease in left ventricular overload; also, improvement observed with the use of Impella®, as well as improvement in the perfusion of the systemic carotid and coronary arteries⁹. It is noteworthy, regarding the reported case, that clinical and hemodynamic deterioration occurred with the simultaneous use of an intra-aortic balloon and Impella®. We observed worsening in hemodynamic measurements of pulmonary capillary wedge pressure and cardiac index (see table). This can be explained by the continuous flow of the Impella® device and the action of diastolic function of the intra-aortic balloon, causing some degree of competition between the Impella® flow and the IAB. It is worth mentioning the possibility of decreased length of in-hospital stay observed in patients using short-term circulatory support devices¹⁰.

Potential Conflict of Interest

No potential conflict of interest relevant to this article was reported.

Sources of Funding

There were no external funding sources for this study.

Study Association

This study is not associated with any post-graduation program.

Case Report

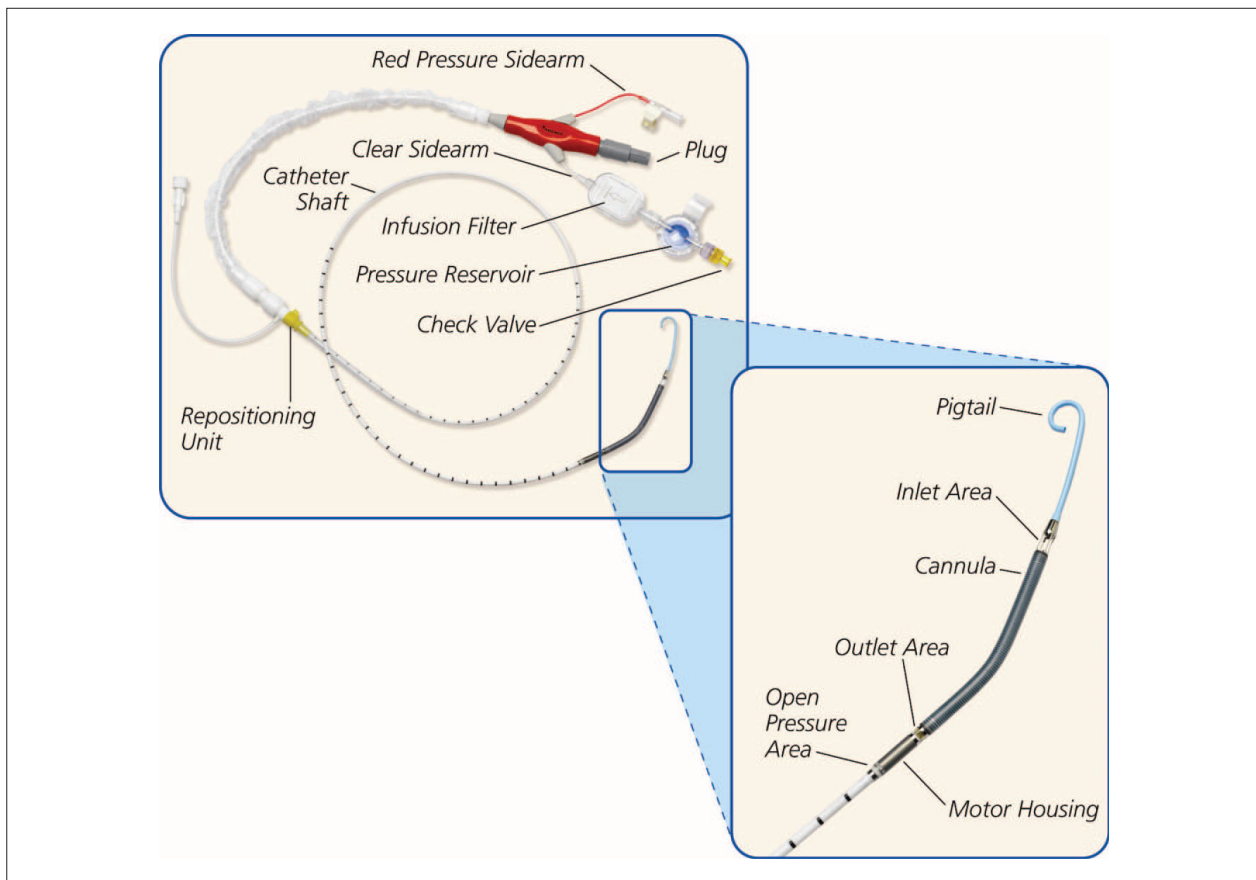


Figure 1 – Illustration of Impella® device, showing the 12F catheter with inflow in the left ventricle and outflow in the ascending aorta.

References

1. Goldberg RJ, Samad NA, Yarzebski J, Gurwitz J, Bigelow C, Gore JM. Temporal trends in cardiogenic shock complicating acute myocardial infarction. *N Engl J Med.* 1999;340(15):1162-8.
2. Holmes DR Jr, Bates ER, Kleiman NS, Sadowski Z, Hogan JH, Morris DC, et al. Contemporary reperfusion therapy for cardiogenic shock: the GUSTO-I trial experience. The GUSTO-I Investigators. Global Utilization of Streptokinase and Tissue Plasminogen Activator for Occluded Coronary Arteries. *J Am Coll Cardiol.* 1995;26(3):668-74.
3. Sjauw KD, Rummelink M, Baan J Jr, Lam K, Engström AE, van der Schaaf RJ, et al. Left ventricular unloading in acute ST-segment elevation myocardial infarction patients is safe and feasible and provides acute and sustained left ventricular recovery. *J Am Coll Cardiol.* 2008;51(10):1044-6.
4. Henriques JP, Rummelink M, Baan J Jr, van der Schaaf RJ, Vis MM, Koch KT, et al. Safety and feasibility of elective high-risk percutaneous coronary intervention procedures with left ventricular support of the Impella® Recover LP 2.5. *Am J Cardiol.* 2006;97(7):990-2.
5. Hochman JS, Sleeper LA, Webb JG, Sanborn TA, White HD, Talley JD, et al. Early revascularization in acute myocardial infarction complicated by cardiogenic shock. SHOCK Investigators. Should We Emergently Revascularize Occluded Coronaries for Cardiogenic Shock. *N Engl J Med.* 1999;341(9):625-34.
6. Hochman JS. Cardiogenic shock complicating acute myocardial infarction: expanding the paradigm. *Circulation.* 2003;107(24):2998-3002.
7. Kar B, Gregoric ID, Basra SS, Idelchik GM, Loyalka P. The percutaneous ventricular assist device in severe refractory cardiogenic shock. *J Am Coll Cardiol.* 2011;57(6):688-96.
8. Seyfarth M, Sibbing D, Bauer I, Fröhlich G, Bott-Flügel L, Byrne R, et al. A randomized clinical trial to evaluate the safety and efficacy of a percutaneous left ventricular assist device versus intra-aortic balloon pumping for treatment of cardiogenic shock caused by myocardial infarction. *J Am Coll Cardiol.* 2008;52; 19:1584-8.
9. Sauren LDC, Accord RE, Hamzeb K, De Jong M, Van der Nage T, Van der Veen FH, et al. Combine Impella® and Intra-aortic Ballon Pump Support to Improve both Ventricular Unloading and Coronary Blood Flow for Myocardial Recovery: an experimental study. *Artif Organs.* 2007;37(11):839-42.
10. Thiele H, Allam B, Chatellier G, Schuler G, Lafont A. Shock in acute myocardial infarction: the Cape Horn for trials?. *Eur Heart J.* 2010;31(15):1828-35.