

### Case 3/2014 — 26-year-old Man with Pulmonary Atresia and Ventricular Septal Defect in Late Postoperative Evolution

Edmar Atik

Clínica privada do Dr. Edmar Atik, São Paulo, SP - Brazil

**Clinical data:** Surgical correction of pulmonary atresia with ventricular septal defect and aortopulmonary collateral arteries was performed in three steps. The first one, with 19 months, with the unification of major collateral artery in the right upper lobe (8 mm) to the right pulmonary artery (RPA), which nurtured the right lower lobe, and Blalock-Taussig anastomosis from the right subclavian artery with its own collateral artery. The second one, with 27 months, with unification of the collateral artery to the left lower lobe with the left pulmonary artery (LPA) of 4 mm and Blalock-Taussig to the left with 6 mm tube in the pulmonary hilum. The third one, with nine years, with no. 18 valved corrugated pericardium tube placement and expansion of LPA and RPA anastomosis with right upper lobe artery. Immediate evolution was considered good, with pulmonary systolic pressure of 22 mmHg. Late evolution was good until the age of 26, remaining without symptoms and without medication.

**Physical examination:** Good general condition, eupneic, acyanotic, normal pulses. Weight: 74 kg; height: 183 cm; BP = 105/70 mmHg; HR: 86 bpm. Aorta discreetly palpated with mild systolic murmur at the suprasternal notch.

In the precordium, apical impulse was not palpable and there were no systolic impulses. The heart sounds were normal and moderate systolic murmur of ++ intensity was harsh across the left sternal border (LSB), not accompanied by fremitus. Diastolic murmur was mild, +/+, at the LSB. The liver was not palpable and the lungs were clear.

#### Complementary tests

**Electrocardiogram:** Showed sinus rhythm, moderate right ventricular (RV) overload without right bundle branch block. Rs morphology in V1 and qRs in V6. Until six years ago, maintained rsr' morphology in V1. QRS duration was 0.94 from the total correction. AP: +70°, AQRs: +90°, AT: +70°.

**Chest radiography:** Shows normal cardiac silhouette, rounded shape and normal pulmonary vasculature (Figure 1).

#### Keywords

Pulmonary atresia / surgery; Heart septal defects, ventricular; Adult.

**Mailing address:** Edmar Atik •

Rua Dona Adma Jafet, 74, conj. 73, Bela Vista. Postal Code 01308-050, São Paulo, SP - Brazil

E-mail: eatik@cardiol.br, conatik@incor.usp.br

Manuscript received July 23, 2013; manuscript revised July 23, 2013; accepted July 30, 2013.

DOI: 10.5935/abc.20140045

**Echocardiogram:** Showed cardiac chambers with normal dimensions, no myocardial hypertrophy (septum = posterior wall = 10 mm) and maximum pressure gradient of 83 mmHg and average of 47 mmHg on the right ventricle outflow tract. Pulmonary insufficiency was severe and biventricular function was normal (RV: 70% and LV: 74%). LPA was 14 mm and RPA was 20 mm.

**Nuclear magnetic resonance:** Showed pulmonary regurgitation fraction of 50% with RV slightly dilated (Vd2VD = 110 ml). RV function = 81% and LV = 64% (Figure 1). Ascending aorta = 46 mm, Vd2VE = 55 ml; delayed myocardial enhancement was not detected.

**Cardiac catheterization:** Showed obstruction of the pulmonary valve (pressure gradient of 82 mmHg), severe pulmonary insufficiency and right ventricle of normal size with normal biventricular contractility. Moderate stenosis (13 mm) in LPA (20 mm) and of similar size to RPA (21 mm). The peripheral pulmonary tree was preserved. The pressures were: RA = 5, RV = 110/10, RPA = 28/10-16, LPA = 20/10-13, PC = 10 mmHg (Figure 2).

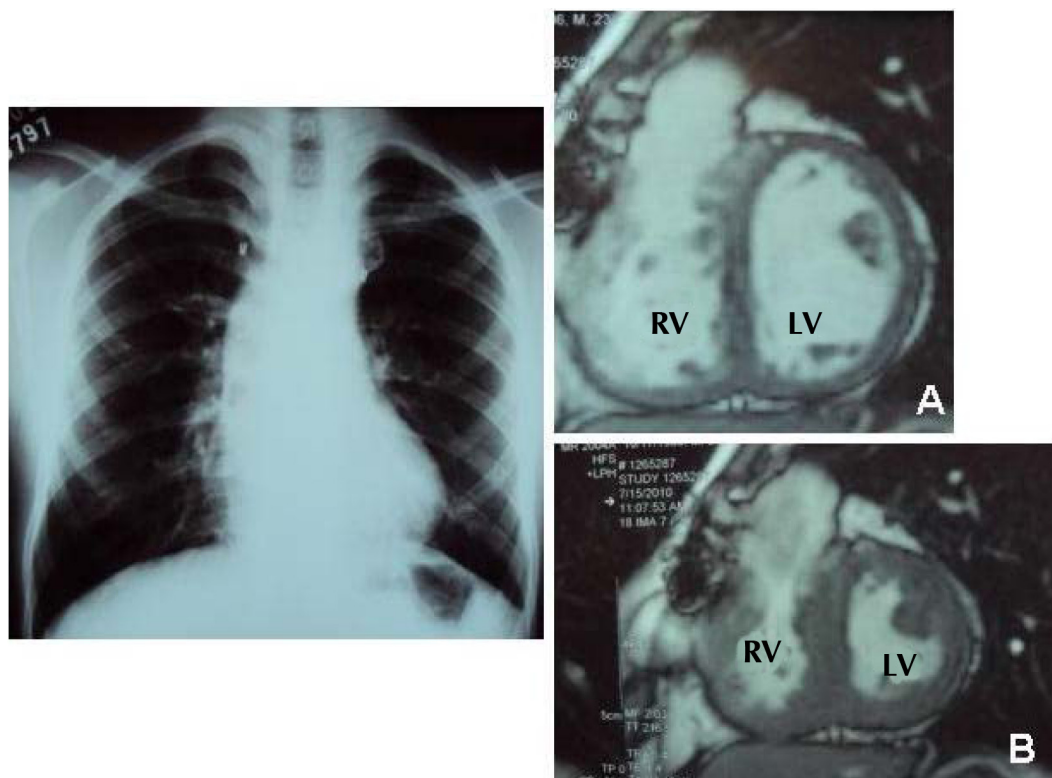
**Clinical diagnosis:** Pulmonary atresia, ventricular septal defect, pulmonary circulation nurtured by aortopulmonary collateral arteries corrected 17 years before with pulmonary unifications and valved tube, severe dual pulmonary lesion and maintenance of RV of normal size and function in an asymptomatic patient.

**Clinical reasoning:** The clinical elements of evolution were compatible with the diagnosis of moderate obstruction in the right ventricle outflow tract, with signs of marked pulmonary valve insufficiency with no corresponding RV increase. Clear systolic murmur with moderate right ventricular overload on electrocardiogram was consistent with the pressure gradient of 82 mmHg found in cardiac catheterization. Diastolic murmur was not accompanied by clinical signs of RV dilatation, despite the diagnosis of marked pulmonary insufficiency in imaging tests.

**Differential diagnosis:** After anatomic correction of PA + VSD with valved tube placement, it is usually observed the presence of dual pulmonary valve lesion whose differential diagnosis leads to cases with tetralogy of Fallot and other anomalies in which the pulmonary valve annulus is expanded.

**Conduct:** Valve-type Melody stenting in the obstructed valved tube, and subsequent placement of a stent at the beginning of the obstructed LPA.

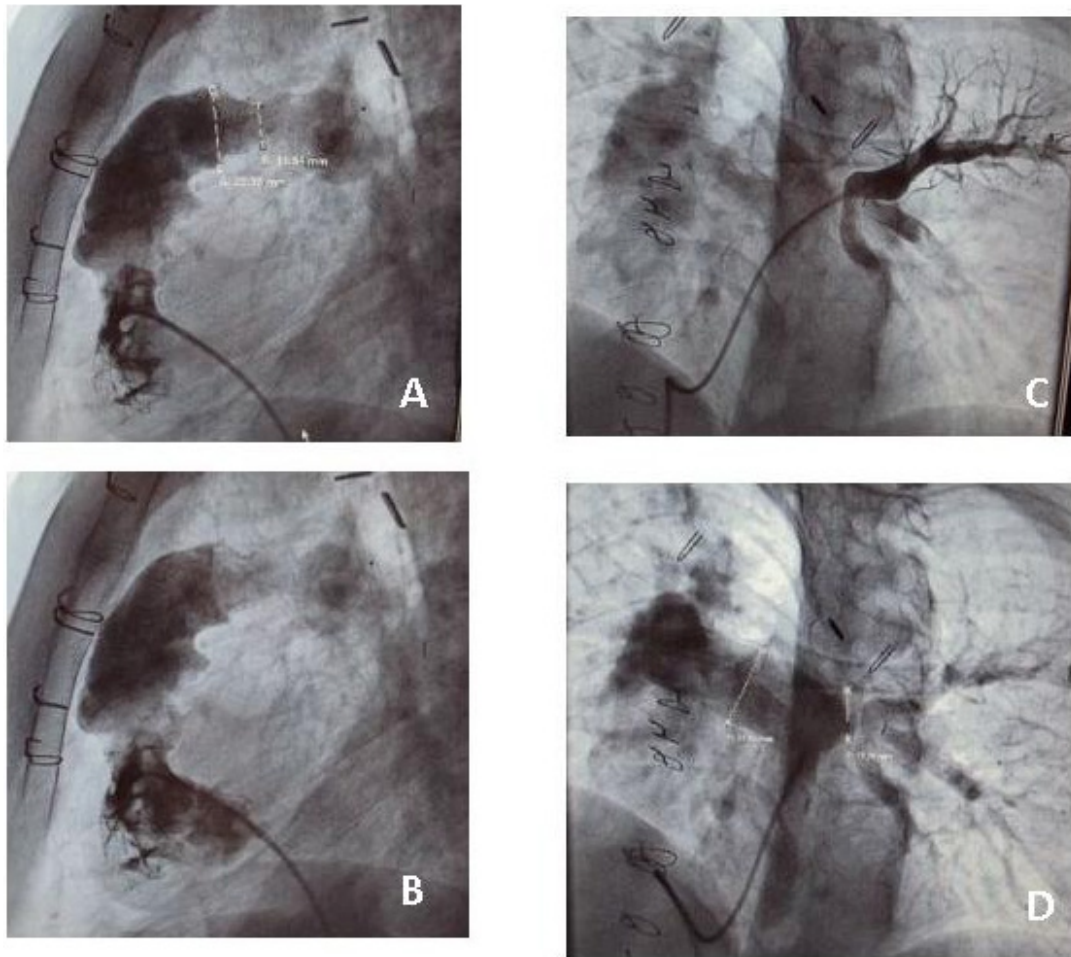
**Comments:** Postoperative evolution after PA + VSD + aortopulmonary collateral arteries correction after several procedures until total correction evolves smoothly, except for the systematic emergence of dual pulmonary valve lesion.



**Figure 1** - Chest radiograph stresses the normal size of the cardiac silhouette, and MRI in diastole (A) and systole (B) shows the normal size and function of both ventricles.

However, in this case, attention is drawn to two aspects to be highlighted. The first one is a sharp disagreement on the marked degree of pulmonary insufficiency with normal right ventricular cavity, which characterizes a smaller ventricular complacency that due to unknown reasons, tending to the

acceptance of morphofunctional characteristics to be better elucidated. Another aspect to be highlighted is that this complex anomaly is undoubtedly possible to be corrected, as long as, in the initial stages, broad standardization of the pulmonary arterial tree is achieved.



**Figure 2** - Cardiac angiography stresses the pulmonary valve stenosis in the RV-PT tube with right ventricular hypertrophy in A and B, and left pulmonary artery stenosis with greater development of the right pulmonary artery in C and D.