

Late Heart Evaluation of Children with Rheumatic Mitral Regurgitation Submitted to Reconstructive Surgery with Implantation of Gregori's Ring

Vitor Hugo Soares Machado e Francisco Gregori Júnior

Universidade Estadual de Londrina, Hospital Evangélico de Londrina, Santa Casa de Londrina e Hospital João de Freitas de Arapongas - Londrina, PR - Brazil

OBJECTIVE

Assess late cardiological evolution of children with rheumatic mitral regurgitation (RMR) who underwent mitral valve reconstructive surgery with implantation of Gregori's ring (MVR), from 1987 to 2003.

METHODS

A study was conducted to analyze a series of cases of 43 children with RMR who underwent MVR with ages ranged from five to twelve years (mean age 9.7 ± 2.2 years); 25 of the patients were females (58.1%). Patients were evaluated as per the following clinical parameters: functional class of heart failure, heart auscultation, electrocardiogram, chest X-ray and echocardiographic findings.

RESULTS

Forty-three patients underwent preoperative evaluation during the postoperative period, the number of patients evaluated decreased to 31 due to the fact that six patients had died and six others underwent valve replacement surgery. Follow-up was carried out for one hundred percent of the patients. A significant reduction of heart failure functional class was observed. Mitral systolic murmur became less intense during the postoperative period. The cardiac area on chest X-ray and the presence of left ventricular overload on electrocardiogram were reduced, as well as the mitral regurgitation level on echocardiographic study. After 188 months, the survival rate was 82%, and the annual mortality rate, 0.38%. Thirty-one (72.6%) patients did not require reoperation and the annual rate of patients who required further surgery was 0.51%.

CONCLUSION

MVR is an effective procedure for treating RMR in children, resulting in a significant improvement of functional class, mitral systolic murmur and level of mitral regurgitation, as shown on Doppler echocardiogram.

KEY WORDS

rheumatic mitral regurgitation, children, annuloplasty

Mitral valve reconstructive surgery started to be used in several cardiac surgery centers after the development of the technique by Carpentier et al¹, which proved to be superior to valve replacement techniques. In 1987, mitral valve reconstructive surgery with implantation of Gregori's ring started to be performed.

The mitral valve (left atrioventricular ring) is made up of the mitral annulus, the leaflets, the chordae tendineae, the papillary muscles and the left ventricle wall underlying the annulus. The main anatomopathological changes affecting the mitral valve are caused by rheumatic disease or myxomatous degeneration. These two diseases may lead to mitral regurgitation, stenosis or double mitral lesion. The dilatation of the mitral valve annulus is the most common cause of mitral regurgitation. The annulus is made up of an anterior portion and a posterior portion. The anterior portion is attached by the right and left fibrous trigones of the heart, whereas the posterior portion is supported by the left ventricular free wall. During the ventricular systole, the annulus contracts like a sphincter taking on a kidney-shaped appearance. When the mitral annulus is dilated, the posterior portion pulls away from the anterior portion, increasing the anteroposterior diameter mainly to the right. Leaflets may be retracted or redundant. In general, leaflet retraction is typical of rheumatic disease sequelae, whereas redundancy usually results from myxomatous degeneration. The posterior leaflet is more susceptible to retraction than the anterior leaflet. Commissural fusion is a common feature when the etiology is rheumatic mitral valve disease. The chordae tendineae may be retracted, elongated or ruptured. The retraction of the primary chordae tendineae may cause them to fuse together or adhere to the papillary muscles. Secondary or tertiary chordae tendineae are also important because, when fibrosed, they may cause localized retractions of the leaflets.

In the rheumatic disease, papillary muscles are thick and fibrous, while this is not the case with myxomatous degeneration in which the muscles are usually slender.

The left ventricular wall, the papillary muscles, the chordae tendineae, the leaflets and the annulus all play an important role in the physiology of the left ventricle contraction³⁻⁵.

Lesions produced by rheumatic disease can impair mitral valve function due to the loss of its functional integrity in the following cases: dilatation of the valve annulus, hypoplasia of the posterior leaflet, commissural fusion, chordae shortening or elongation, and rupture of anterior and/or posterior chordae, which consequently leads to mitral regurgitation and/or stenosis.

Gregori's ring draws the anterior and posterior leaflets together, more effectively to the right, even correcting the posteromedial commissure widening. This new ring leaves aside the anterior portion, considered useless and even undesirable, especially when it is used in growing children.

This study assessed, by means of clinical and Doppler echocardiography parameters, children with rheumatic

mitral regurgitation who underwent mitral valve reconstructive surgery with implantation of Gregori's ring during their late clinical evolution.

METHODS

The cases were analyzed by means of a longitudinal study featuring descriptive and analytical components and divided into two phases: the first one is called the preoperative phase, and the second one, the current postoperative phase.

During the preoperative phase, children were submitted to examinations and tests, and were then referred to mitral valve reconstructive surgery with implantation of Gregori's ring, through the *Sistema Único de Saúde – SUS* (Unified Health System) in hospitals located in Londrina and Araongas (state of Paraná). For the postoperative phase, patients were evaluated in private clinics in Londrina.

During the preoperative phase, a total of 43 children, up to twelve years of age with rheumatic mitral regurgitation were submitted to mitral valve reconstructive surgery with implantation of Gregori's ring in consecutive operations, by the same cardiac surgery service, between October 1987 and July 2002. The mean follow-up was 86.47 +/- 53.27 months, with a minimum of 0 (in-hospital death) and a maximum of 188 months.

For the postoperative phase, a thirty-one patient sample was obtained during 2002 and 2003. Six patients who had to be reoperated for mitral regurgitation correction were excluded, and six other patients died. Sample size was determined as was convenient and established according to the number of patients who had undergone surgery at the *Serviço de Cirurgia Cardíaca de Londrina* (Cardiac Surgery Service in Londrina).

During the preoperative phase, medical charts of the 43 patients were reviewed and the addresses necessary to locate these individuals were obtained. Patients underwent heart auscultation, electrocardiograms, chest X-rays, and Doppler echocardiograms. During the postoperative phase, a total of 31 patients were enrolled in a specific protocol and, after the consent form was signed by the person responsible for the child, they were evaluated with clinical examinations, electrocardiograms, chest X-rays and Doppler echocardiograms.

After sedation, asepsis and antisepsis, the access route was established by median thoracotomy with longitudinal sectioning of the sternum. Extracorporeal circulation was installed and cardiac arrest was induced; myocardial anoxia was produced by clamping the ascending aorta with reperfusion every 15 minutes, and unclamping it for 5 minutes. Moderate systemic hypothermia was used (28 °C to 32 °C). Duration of extracorporeal circulation ranged from 29 to 105 minutes (mean 62.81 ± 20.8 minutes); myocardial anoxia lasted from 14 to 80 minutes (mean 35.38 ± 15.69 minutes). The prosthesis was

implanted (Fig. 1) in the mitral annulus using U-stitches passed through the outer surface of the annulus. Several reconstructive techniques were employed alone or in combination with others, as shown on Table I.

The Braile-Biomédica (São José do Rio Preto – SP) prosthesis is semicircular and made of stainless steel coated with a thin layer of silicon and Dacron velvet. The anterior portion is open and the lower portion, to the right side, is straightened (Fig. 1). Ring sizes range from 24 to 36, with corresponding ring sizers. The selection of the ideal ring size should be based on the distance between right and left fibrous trigones of the heart. Ring sizes 24, 26, 28, 30, 32, 34, and 36 mm were used.

During the clinical evaluation, patients were analyzed as to the functional class of their heart failure according to the New York Heart Association Criteria Committee¹⁰, comparing preoperative and postoperative values.

During the preoperative phase, each patient was auscultated for cardiac murmurs in the hospital by the surgical team who reported on the intensity and type of murmur. During the postoperative phase, patients underwent auscultation performed by the author in the medical office and rated according to an auscultation scale scored from 0 to 4+.

The preoperative Doppler echocardiography transthoracic study was performed by one single echocardiographer using mechanical transducers ranging from 2.5 to 5.0 MHz; after surgery, it was done by the author using electrical transducers ranging from 2.5 to 3.5 MHz with second harmonic signals. The incidences, measurements and interpretations abided by the recommendations of the American Association of Echocardiography.

Measurements of right and left cavities were expressed in millimeters; the ventricular function, in % (shortening percentage and Teichholz¹¹ method; in the ejection

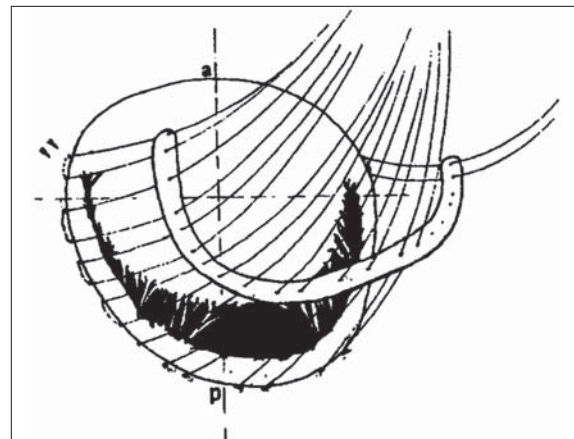


Fig. 1 – Gregori's ring implantation technique. In the anterior portion of the Gregori's ring there is an open hemielliptical shape. The lower portion, to the right, is straightened and is used to draw this region towards the anterior leaflet

fraction). The mean mitral valve gradient and the pulmonary artery pressure were expressed in millimeters of mercury (mmHg) and the left ventricular mass, in grams (g). The calculation of the mitral valve area was expressed in square centimeters according to the Pressure Half Time (PHT) method. The quantification of the mitral reflux was obtained by color Doppler mapping, as per Colette¹² classification that quantifies mitral regurgitation based on the extension and magnitude of the regurgitation jet during left ventricular systole.

The cardiothoracic index was utilized to estimate heart size on chest X-rays, using a scale of scores from 0 to 4+.

To assess the left ventricle overload on the electrocardiogram, Sokolow & Lyon¹³ criteria were used, and for the left atrial overload evaluation, the Morris Jr.¹⁴ index was used. Patients were evaluated as to the presence or absence of atrial fibrillation.

Table I – Procedures and surgeries associated with mitral annuloplasty by means of Gregori's ring

Associated procedures*	No.	%
Chordae shortening as per Gregori's technique	25	58
Chordae shortening as per Carpentier's technique	21	49
Chordae transposition	9	21
Chordae shortening as per Fratter's technique	9	21
Partial rectangular resection of the posterior leaflet	2	4.6
Bilateral Wooler ⁷ technique	1	2.3
Debridement of calcium deposits	1	2.3
Transposition of chordae from the posterior leaflet of the tricuspid valve to the anterior leaflet of the mitral valve	1	2.3
Commissurotomy		
Bilateral papillotomy	1	2.3
	1	2.3
Associated surgeries	No.	%
Aortic valve replacement	2	4.6
Aortic valvoplasty	2	4.6
Tricuspid valvuloplasty (De Vega ⁸)	1	2.3
Cox ⁹ surgery	1	2.3

* Isolated or combined procedures

Results were displayed in tables and figures. The Wilcoxon test (paired samples) was used for the comparison between phases with ordinal variables. The (postoperative) numerical variables with normal distribution were presented as mean, median, standard deviation, minimum value, maximum value and quartile values. The association between death and gender was calculated using Fisher's exact test. Survival analysis and the time to valve replacement were performed using the Kaplan & Meier product-limit estimation¹⁵. All decisions were based on a 5% alpha error, and P values * 0.05 were considered significant. All analyses were performed using SPSS 9.1 software for Windows and Statistica 6.0.

The protocol was validated by the Research Ethics Committee of the State University, and each patient was informed before being enrolled in the study.

RESULTS

A total of 43 children underwent preoperative evaluations. Eighteen (41.9%) patients were males and 25 (58.1%) were females, with no significant gender difference ($p = 0.286$). The postoperative evaluation was performed with only 31 participants, as 6 patients died (all females) and 6 (excluded) were submitted to valve replacement (3 females and 3 males). This explains why, at this phase, the study had fifteen male patients (48.3%) and sixteen female patients (51.7%), with no significant difference between the genders; these patients represented 72% of the cases enrolled at the beginning of the study sixteen years before. Patients' ages during the preoperative phase ($n = 43$) ranged from five to twelve years (mean age 9.7 ± 2.2 years). During the postoperative phase ($n = 31$), ages ranged from eleven to twenty-six years (mean age 17.6 ± 4.6).

A significant improvement in the functional class was

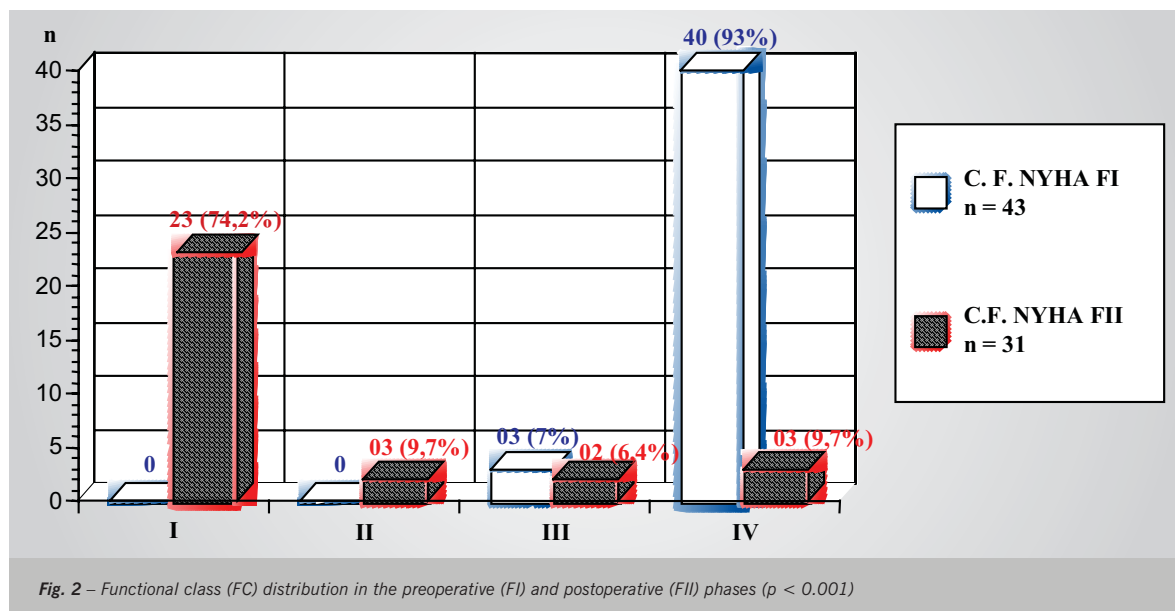
observed in the postoperative period as compared to the preoperative period ($p < 0,001$) (Fig. 2). During the preoperative phase, three patients (7%) were classified as FC III and forty (93%) were classified as FC IV.

In the postoperative period, 23 patients (74.2%) were classified as FC I; three (9.7%) were FC II; two (6.4%) were FC III, and three (9.7%) were classified as FC IV.

A significant decrease ($p < 0.001$) in the intensity of the mitral systolic murmur (MSM) was seen in the postoperative phase compared to the preoperative phase. During the preoperative period, 16 (37.2%) patients were MSM IV, 19 (44.2%) were MSM III, six (14%) were MSM II and 2 (4.7%) had no report of a murmur. During the postoperative, of the 31 MSM patients evaluated, one (3.2%) was MSM IV, six (19.4%) were MSM III, 12 (38.7%) were MSM II and 12 (38.7%) were MSM I.

There was a significant reduction ($p < 0,001$) in the cardiac area as shown on the postoperative chest X-ray. In the preoperative phase, three patients (7%) had a normal cardiac area on the X-ray, four (9.3%) had a slight increase, eight (18.6%) had a moderate increase, 25 (58.1%) had a significant increase in the cardiac area, and for 3 patients (7%) no chest X-ray reports were found. Thirty-one patients were evaluated in the postoperative period: 22 (71%) of them had a normal cardiac area on the X-ray, 3 (9.7%) showed a slight increase, five (16.1%) had a moderate increase and 1 (3.2%) had a significant increase in the cardiac area.

A significant reduction ($p < 0.001$) in left ventricle overload was seen on the electrocardiogram (LVO-ECG). In the preoperative phase, thirty patients (69.8%) had LVO-ECGs exams performed; nine (20.9%) did not have this test and for four patients (9.37%) no electrocardiograms or reports were found. During the postoperative phase, seven patients (22.6%) had LVO-ECGs and 24 (77.4%) did not.



During the preoperative phase, 37 (86%) patients showed sinus cardiac rhythm, 2 (4.7%) had atrial fibrillation and 4 (9.3%) had no ECGs or reports. Postoperatively, 26 patients (83.9%) were in sinus rhythm and 5 (16.1%) were in atrial fibrillation. No significant difference in rhythm was observed between the pre- and postoperative phases ($p < 0.083$).

Thirty patients (69.8%) had left atrial overload on the electrocardiogram (LAO-ECG) in the preoperative phase, eight (18.6%) did not, and for five patients (11.6%) no electrocardiogram reports were found. During the postoperative period, twenty patients (64.5%) had LAO-ECGs and 11 (35.5%) did not. No significant difference was observed between the pre- and postoperative phases ($p < 0.285$).

Thirty-one patients with Gregori's ring underwent Doppler echocardiograms during the postoperative phase. The left ventricular mass had an average of 220.45 ± 94.76 grams, with a minimum value of 80 g and a maximum value of 498 g. As to the left atrium size, minimum and maximum diameters were 29 mm and 84 mm, respectively (mean diameter 49.26 ± 13.20 mm). The left ventricle diastolic diameter measured in millimeters had an average of 51.06 ± 7.07 mm, with value of 40 mm, minimum, and of 69 mm, maximum. The mitral area was estimated using the Pressure Half Time (PHT) method; minimum area was 1.0 cm^2 and maximum area was 2.8 cm^2 (mean area $1.9 \pm 0.48 \text{ cm}^2$). Echocardiograms performed during the preoperative period indicated that two (4.7%) patients had moderate mitral regurgitation, and 41 (95.3%) had significant insufficiency (Fig. 3).

During the postoperative phase, five patients (16.1%) showed no mitral regurgitation, fourteen had mild

insufficiency, ten (32.3%) had moderate insufficiency, and two (6.4%) had significant mitral regurgitation. A significant decrease in mitral regurgitation was observed on echocardiograms comparing the pre- and postoperative phases ($p < 0.001$).

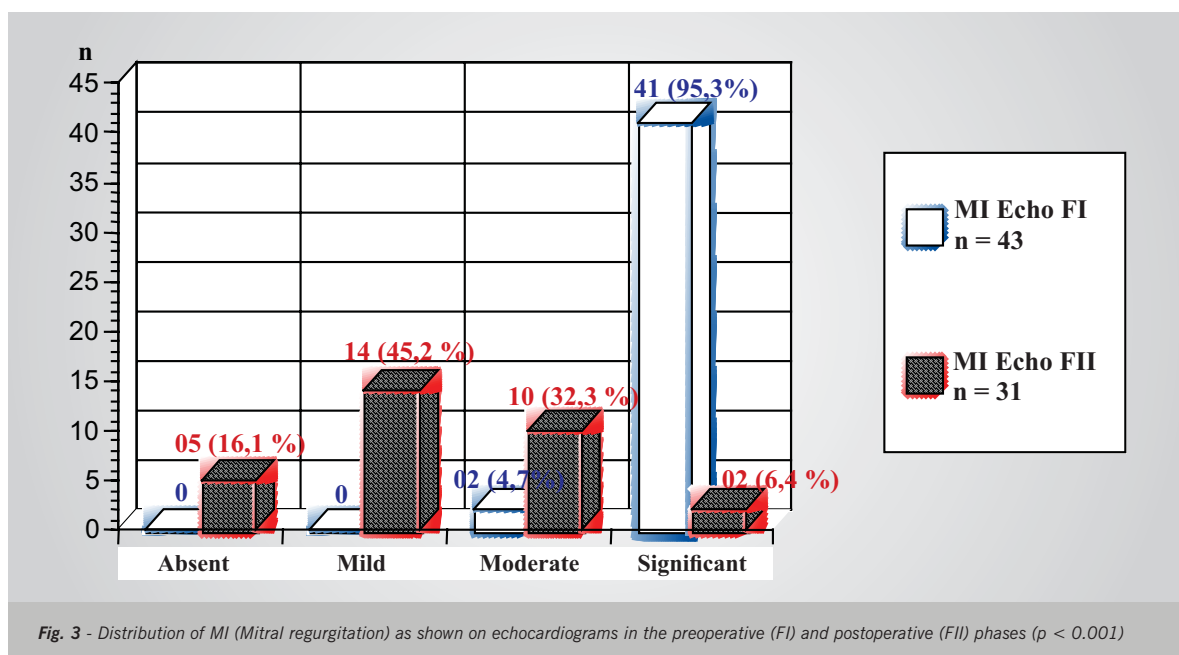
The ejection fraction (EF) estimated by the Teichholz⁷ method indicated a minimum value of 54% and a maximum value of 76% (mean: $67.78\% \pm 6.09\%$). Peak pulmonary artery pressures measured in millimeters of mercury (mmHg) ranged from 25 mmHg (minimum) to 78 mmHg (maximum) with a mean value of 41.32 ± 13.03 mmHg. Mitral valve mean gradient measured in mmHg ranged from 3 mmHg (minimum) to 20 mmHg (maximum) with a mean value of 7.19 ± 3.66 mmHg.

Aortic valve maximum gradient measured in mmHg ranged from 4 mmHg (minimum) to 39 mmHg (maximum), with a mean value of 7.94 ± 6.13 mmHg.

A total of six patients died between 1987 and 2003 (14%), whereas 37 (86%) survived. After 188 months, annual mortality rate was 0.38%.

The median postoperative time to death was 24 months, with corresponding quartiles of nine and sixty-three months (1st and 3rd) and an amplitude between zero and 108 months. Of the six patients who died, one (2.3%) died in-hospital and five (11.6%) died later, two (4.6%) due to non-cardiac causes and three (6.9%) due to cardiac causes. All patients who died were females (6/25), which shows an association between death and gender ($p = 0.03$ as per Fisher's exact test). All six patients who died were FC IV.

Figure 4 shows the actuarial curve (Kaplan & Meier¹⁵) for the survival analysis.



experienced recurrences of rheumatic activity and had late deaths, six and 52 months after the first surgery.

DISCUSSION

Mitral valve reconstructive surgery has increasingly become the method of choice thanks to the concern of surgeons with the preservation of the valvar apparatus, and its importance in maintaining ventricular function, which resulted in decreased morbidity and mortality rates. This favorable evolution has also been observed in children with high functional class (FC III and IV). In this study, functional class improved significantly between the pre- and postoperative phases, as shown in Fig. 2, confirming the results of former studies¹⁶⁻²³. Antunes et al²⁰ analyzed patients with rheumatic disease, and of all the patients formerly classified as FC III or IV, 85% became FC I. This improvement observed during the postoperative period is due to the preservation of the continuity between the chordae tendineae and the mitral annulus.

The systolic murmur intensity level in the mitral area decreased significantly after surgical correction. These results are similar to those indicated by other studies¹⁷ that showed the predominance of a mild murmur during the postoperative phase with an improvement in 93% of the cases, in comparison with the preoperative period. Carvalho et al²³ demonstrated that 92.4% of all patients evaluated presented predominantly with just a mild murmur or no murmur at all during the postoperative phase.

The cardiac area on the X-ray and the presence of LVO on ECG showed significant reductions after surgical correction.

A significant decrease was observed in the degree of mitral regurgitation on echocardiogram from the preoperative to the postoperative phase (Fig. 3). The Doppler echocardiographic study was a great advance in assessing not only the indication, but also the results of the surgery. This non-invasive method in most cases replaces the hemodynamic study, especially in children. It is considered a "gold standard" for the evaluation of cardiac valves due to its image technology features such as second harmonic imaging, transesophageal echocardiography, contrast echocardiogram and real-time tridimensional reconstruction. Until the year 2000, all children underwent previous cardiac catheterization during the preoperative phase. From that time on, however, the indication for surgery was made based on the results from the Doppler echocardiogram, as well as on clinical parameters. There are several studies correlating Doppler echocardiographic studies with the results of mitral valvoplasty^{16,19,22,24-29}. According to the results achieved by Spencer et al²⁴, from a total of 95 patients who were followed, 82 did not have regurgitation, whereas 12 had mild regurgitation. According to Carvalho et al²³, 85% of the patients had no regurgitation at all, or a very mild one, with a significant

decrease after treatment. This same incidence was also observed by Gregori Jr. et al²², who used the same ring and the same Carpentier surgical technique.

The presence of a mild or moderate regurgitation is very common during the postoperative phase of mitral valvoplasty, as described by some authors^{16,19,22-26,29}, and the late clinical evolution is always satisfactory. Fix et al²⁸ conducted a pioneer study comparing the late evolution of patients who were classified as having regurgitation intensity of I or II (76 patients). After four years, they observed that mortality, thromboembolism, functional classification, survival (86%) and number of re-hospitalizations were the same. There was, however, a small difference in the rate of reoperations in patients with a mild and/or moderate regurgitation (83% x 94%).

The low in-hospital mortality rate (one patient – 2.3%) in this study is within the results reported in medical literature^{17,18,20,26,30-36}. Pomerantzeff et al³⁴ reported a mortality rate of 2.6% in 301 patients who had undergone surgery. Gregori Jr. et al²² noted a 1.9% mortality rate in 105 patients who underwent surgery. In a study conducted with 275 patients, Lessana et al³⁷ registered a 4% mortality rate. In 1983, Carpentier et al³² conducted a study with the largest number of cases worldwide (1,421 patients) and registered a 3.6% in-hospital mortality rate.

Cosgrove et al¹⁸ correlated functional class and mortality. FC III patients had a 4.9% rate and those in FC IV, a 12.5% rate.

As described in medical literature³⁸, intraoperative mortality is higher in the acute phase of rheumatic fever, and surgery is indicated for patients with severe valve dysfunction for whom clinical treatment is ineffective. But even for these patients, annuloplasty proved to be more effective than valve replacement since it preserves the whole subvalvar apparatus, which should result in better ventricular function after the postoperative period³⁴.

According to Kumar et al³⁹, the intraoperative mortality rate in children and adolescents up to 15 years of age with rheumatic disease undergoing reconstructive surgery was 4.8%. In this study, a total of six patients died (14%), 37 survived (86%), and the annual mortality rate was 0.38%. Five patients (12.6%) had late deaths. One death (2.3%) occurred in-hospital. Eight patients (18.6%) had to be reoperated, with an annual reoperation rate of 0.51%, and 31 patients (72.6%) were free of reoperations during the 188-month follow-up period.

In a study with 551 patients, Carpentier et al³¹ registered a 7% mortality rate in a ten-year period, with survival rate of 82%.

After 17 years of clinical evolution, Deloche et al¹⁶ registered a 19% mortality rate and a 72.4% survival rate. The evolution was better in patients with rheumatic disease than in those with myxomatous degeneration (81.1% and 71.1%, respectively).

Reconstructive surgery is technically more difficult to perform, with high rates of failure for the group of patients with rheumatic disease (reoperation rate ranges from 4.8% to 27%)⁴⁰⁻⁴³. The rate of reoperations increases inversely with age^{41,44}. Antunes et al²⁰ have also reported that rheumatic disease is the main cause for reoperation. In his experience with 201 patients who had undergone surgery, reoperation incidence was 10.4% during an average period of 9.9 months. The authors of the study also observed that leaflet retraction was the most common cause of valve dysfunction. After 54 months, 78% of patients were free from reoperation. This high rate of success was justified by the fact that the technique preserves the natural valve of the organism (and it is advantageous even though 44.4% of the patients were under 15 years of age).

Compared to valve replacement, mortality and morbidity rates associated with mitral valve reconstructive surgery have decreased, as has been published by other authors^{18,20,35,45-48}. Mortality rate due to isolated mitral valve replacement ranges from 3% to 8% in several medical centers (mean value of 6.4%)⁴⁹ with 13,936 patients having undergone surgery due to mitral regurgitation and/or stenosis. According to the same database (National Cardiac Surgery Database), the mortality rate for isolated reconstructive surgery was 3%, in a total of 4,167 patients.

Adebo & Ross²⁷ observed that, after six years, the survival rate of patients who had undergone annuloplasty was 95%, whereas that of patients who underwent valve replacement ranged from 66% to 78% with mechanical prostheses, and 82% to 90% with biological prostheses. Galloway et al⁴⁵ observed in their practice that 75% of the patients were free of events caused by the conventional procedure, whereas 45% were free of events when submitted to valve replacement, a statistically significant incidence.

There is controversy about the utilization of rings, probably due to the impairment of ventricular function. After analyzing 27 patients who received flexible and rigid rings, David et al⁵⁰ confirmed the good performance

of the flexible ring. They observed also that both rings caused an important decrease in the left ventricle diastolic diameter (LVDD), whereas the systolic diameter (LVSD) was reduced mainly with the flexible ring. After four months, they noted a better LV performance in the series of patients who received the flexible ring. They also reported that the rigid ring hinders final ventricular contraction and recommended its use mostly in cases of myxomatous degeneration. According to these authors, the rigid ring does not alter LV contraction because the patient's natural ring has been hardened by the disease itself. A better systolic function in the inferobasal portion of the LV was observed in postoperative studies conducted by Duran & Ubago⁵¹ in patients with flexible rings. However, Deloche et al¹⁶ showed that there were no differences between the two types of rings, pointing out that the incidence of dehiscence with flexible and rigid rings was 2.8% and 0.5%, respectively. The flexible ring interfered less with mitral annulus motion and caused less reduction in the basal contractility of the LV. The rigid ring caused mild aortic subvalvar insufficiency due to its compression, reducing the posterior leaflet motion as well, though without any clinical significance. These facts were observed by video-endoscopy in experimental work with porcines⁵².

The ring used in the surgeries analyzed in the present study is considered a rigid, and is fixed in its posterior portion and open in the anterior one (Fig.1).

CONCLUSIONS

Mitral valve reconstructive surgery with implantation of Gregori's ring is an effective procedure to treat children with rheumatic mitral regurgitation. The procedure significantly improves heart failure functional class, mitral systolic murmur and degree of mitral regurgitation evaluated by Doppler echocardiogram. Moreover, echocardiographic findings showed that the implantation of an open prosthesis allowed the development of the mitral annulus during the child's normal development and growth.

REFERENCES

1. Carpentier A, Deloche A, Dauptain J et al. A new reconstructive operation for correction of mitral and tricuspid insufficiency. *J Thorac Cardiovasc Surg* 1971; 61: 1-13.
2. Gregori Jr F. Cirurgia reparadora da valva mitral com novo modelo de anel protético. São Paulo, 1990. Tese (Doutorado em Medicina) - Escola Paulista de Medicina, Universidade Federal de São Paulo.
3. Lillehei CW, Levy MJ, Bonnabeau RC. Mitral valve replacement with preservation of the papillary muscles and the chordae tendineae. *J Thorac Cardiovasc Surg* 1964; 47: 532-43.
4. David TE, Burns RJ, Bacchus CM, Druck MN. Mitral valve replacement for mitral regurgitation with and without preservation of chordae tendineae. *J Thorac Cardiovasc Surg* 1984; 88: 718-25.
5. Sarris GE, Cahill PD, Hansen DE, Derby GC, Miller DC. Restoration of left ventricular systolic performance after reattachment of mitral chordae tendineae: the importance of valvular-interaction. *J Thorac Cardiovasc Surg* 1988; 95: 969-79.
6. Frater RWM, Gabbay S, Shore D, Factor S, Strom J. Reproducible replacement of elongated or ruptured mitral valve chordae. *Ann Thorac Surg* 1983; 35: 14-19.
7. Wooler GH, Nixon PGE, Grimshaw VA. Experiences with repair of the mitral valve in mitral incompetence. *Thorax* 1962; 17: 49-57.
8. De Vega NG. La anuloplastia selectiva, regulable y permanente. Una tecnica original para el tratamiento de la insuficiencia tricuspide. *Rev Esp Cardiol* 1972; 25: 555-6.
9. Cox JL, Boineau JP, Schuessler RB, Kater KM, Lappas DG. Five-year experience with the maze procedure for atrial fibrillation. *Ann Thorac Surg* 1994; 56: 814-24.
10. New York Heart Association Criteria Committee Inc.: Diseases of the Heart and Blood Vessels Nomenclature and Criteria for Diagnosis. 6th ed. Boston: Little, Brown and Co., 1964: 114.
11. Teichholz LE, Kreulen T, Herman MV, Gorlin R. Problems in graphic correlations in the presence or absence of asynergy. *Am J Cardiol* 1976; 37: 7.

12. Colette V. Pulsed Doppler echocardiographic indices for assessing mitral regurgitation. *Br Heart J* 1984; 51: 130-8.
13. Sokolow M, Lyon TP. The ventricular complex in left ventricular hypertrophy as obtained by unipolar precordial and limb leads. *Am Heart J* 1949; 37: 161.
14. Morris Jr JJ, Dunlap WM, Thompson Jr HK, Mc Intosh HD, Estes Jr EH. P wave analysis in the electrocardiographic diagnosis of left ventricular hypertrophy. *Circulation* 1965; 32 (suppl III): 154.
15. Kaplan EL, Meier, P. Nonparametric estimation from incomplete observations. *Journal of the American Statistical Association*, 1958; 53: 457-81.
16. Deloche A, Jebara VA, Relland JYM et al. Valve repair with Carpentier techniques: the second decade. *J Thorac Cardiovasc Surg* 1990; 99: 990-1002.
17. Lessana A, Carbone C, Romano M et al. Mitral valve repair: results and the decision-making process in reconstruction: report of 275 cases. *J Thorac Cardiovasc Surg* 1990; 99: 622-30.
18. Cosgrove DM, Chavez AM, Lytle BM et al. Results of mitral valve reconstruction *Circulation* 1986; 74 (3 Pt 2): 182-7.
19. David TE, Armstrong S, Sun Z, Daniel L. Late results of mitral valve repair regurgitation due to degenerative disease. *Ann Thorac Surg* 1993; 56: 7-14.
20. Antunes MJ, Magalhães MP, Colsen PR et al. Valvoplasty for rheumatic mitral valve disease: a surgical challenge. *J Thorac Cardiovasc Surg* 1987; 94: 44-56.
21. Gregori Jr F, Takeda R, Façanha L et al. Nova técnica reconstrutora na insuficiência valvar mitral por alongamento das cordas tendíneas da cúspide anterior. *Arq Bras Cardiol* 1990; 54: 205-9.
22. Gregori Jr F, Silva SS, Hayashi SS, Aquino W, Cordeiro C, Silva LR. Mitral valvuloplasty with a new prosthetic ring: analysis of the first 105 cases. *Eur J Cardiothorac Surg* 1994; 8: 168-72.
23. Carvalho RG, Giublin PR, Lopes LR, Mulinari L, Loures DRR. Plástica da valva mitral com emprego do anel de Gregori-Braille: análise de 66 pacientes. *Rev Bras Cir Cardiovasc* 1998; 13(4): 295-316.
24. Spencer FC, Colvin SB, Culiford AT, Isom OW. Experiences with the Carpentier techniques of mitral valve reconstruction in 103 patients (1980-1985). *J Thorac Cardiovasc Surg* 1985; 90: 341-50.
25. Pomerantzeff PMA, Azevedo JG, Ratti M et al. Plástica da valva mitral em pacientes consecutivos. Como é a evolução tardia?: avaliação clínica e ecocardiográfica. *Rev Bras Cardiovasc* 1991; 6: 63-79.
26. Galler M, Kronzon I, Slater J et al. Long-term follow-up after mitral valve reconstruction: incidence of postoperative left ventricular outflow obstruction. *Circulation* 1986; 74(3 pt 2): 99-103.
27. Adebo OA, Ross JK. Conservative surgery for mitral valve disease: clinical and echocardiographic analysis of results. *Thorax* 1983; 38: 565-71.
28. Fix J, Isada L, Cosgrove D et al. Do patients with less than "echo-perfect" results from mitral valve repair by intraoperative echocardiography have a different outcome? *Circulation* 1993; 88 (5 Pt 2): 39-48.
29. Souza Uva M, Grare P, Jebara V et al. Transposition of chordae in mitral valve repair: mid-term results. *Circulation* 1993; 88 (5 Pt 2): 35-8.
30. Carpentier A, et al. Conservative management of the prolapsed mitral valve. *Ann Thorac Surg* 1978; 26: 294-302.
31. Carpentier A, Chauvaud S, Fabiani JN et al. Reconstructive of mitral incompetence: ten years appraisal. *J Thorac Cardiovasc Surg* 1980; 79: 338-48.
32. Carpentier A Cardiac valve surgery: the "French Correction". *J Thorac Cardiovasc Surg* 1983; 86: 323-37.
33. Lessana A, Tran Viet T, Ades F et al. Mitral reconstructive operations: a series of 130 cases. *J Thorac Cardiovasc Surg* 1983; 86: 553-61.
34. Pomerantzeff PMA, Brandão CM, Monterio AC et al. Plástica da valva mitral no InCor HC-FMUSP: resultados tardios de doze anos de evoluções das técnicas. *Arq Bras Cardiol* 1993; 61 (Supl.II): 175.
35. Orszulak TA, Schaff HV, Danielson GK et al. Mitral regurgitation due to ruptured chordae tendineae: early and late results of valve repair. *J Thorac Cardiovasc Surg* 1985; 89: 491-8.
36. Scott ML, Stowe CL, Nunnaly LC et al. Mitral valve reconstruction in the elderly population. *Ann Thorac Surg* 1989; 48: 213-7.
37. Lessana A, Herreman F, Boffety C et al. Hemodynamic and cineangiography study before and after mitral valvuloplasty (Carpentier's technique). *Circulation* 1981; 64 (2 Pt 2): 195-202.
38. Pomerantzeff PMA, Snitcowsky R, Trevisan IV, Marcial MB, Verginelli G, Jatene AD. Surgical treatment of acute episodes of rheumatic fever. *Cardiol Young* 1992; 2: 244-6.
39. Kumar AS, Rao PN, Saxena A. Results of mitral valve reconstruction in children with rheumatic heart disease. *Ann Thorac Surg* 1995; 60: 1044-7.
40. Chauvaud SM, Deleuze P, Perier PM, Carpentier AF. Failures in reconstructive mitral valve surgery [Abstract]. *Circulation* 1986; 74 (Suppl 2): 393.
41. Skoularigis J, Sinovich V, Joubert G, Sareli P. Evaluation of long term results of mitral valve repair in 254 young patients with rheumatic mitral regurgitation. *Circulation* 1994; 90 (Suppl 2): 167-74.
42. Prabhakar G, Kumar N, Gometza B, Gala O, Al-Halees Z, Duran CMG. Triple valve operation in the young rheumatic patient. *Ann Thorac Surg* 1993; 55: 1492-6.
43. Aharon AS, Laks H, Drinkwater DC et al. Early and late results of mitral valve repair in children. *J Thorac Cardiovasc Surg* 1994; 107: 1262-71.
44. Duran CMG, Gometza B, De Vol EB. Valve repair in rheumatic mitral valve disease. *Circulation* 1991; 84 (Suppl 3): 125-32.
45. Galloway AC, Colvin SB, Baumann FG et al. A comparison of mitral valve reconstruction with mitral valve replacement: intermediate - term results. *Ann Thorac Surg* 1989; 47: 655-62.
46. Angel WW, Oury JII, Shah P. A comparison of replacement and reconstruction in patients with mitral regurgitation. *J Thorac Cardiovasc Surg* 1987; 93, 665-74.
47. Sand ME, Naftel DC, Blackstone EH, Kirklin JW, Karp RB. A comparison of repair and replacement for mitral valve incompetence. *J Thorac Cardiovasc Surg* 1987; 94: 208-19.
48. Yacoub M, Halim M, Radley-Smith R et al. Surgical treatment of mitral regurgitation caused by floppy valves: repair versus replacement. *Circulation* 1981; 64 (supl.II): 210-6.
49. Jamieson WRE, Edwards FH, Schwartz M et al. Risk stratification for cardiac valve replacement. *National Cardiac Surgery Database. Ann Thorac Surg* 1999; 67: 943.
50. David TE, Komeda M, Pollick C, Burns R J. Mitral valve annuloplasty: the effect of the type on left ventricular function. *Ann Thorac Surg* 1989; 47: 524-8.
51. Duran CG, Ubago JL. Clinical and hemodynamic performance of a totally flexible prosthetic ring for atrioventricular valve reconstruction. *Ann Thorac Surg* 1976; 22: 458-6
52. Van Rijk-Zwikker GL, Mast F, Schipperheyn JJ, Huysmans HA, Brusckhe AV. Comparison of rigid and flexible ring for annuloplasty of the porcine mitral valve. *Circulation* 1990; 82(5 Suppl.): 58-64.