

Cholesterol Pericarditis. A Specific but Rare Cause of Pericardial Disease

Fábio Fernandes, Glacy Sabra Vieira, Edmundo Arteaga, Barbara Maria Ianni,
Paulo Pêgo-Fernandes, Charles Mady

São Paulo, SP - Brazil

During a diagnostic investigation in a 40-year-old male with pericardial effusion associated with hypothyroidism, cholesterol pericarditis was detected. We report a brief review on the etiopathogeny, clinical findings, and therapeutical possibilities of this entity.

Pericardial diseases have diverse causes, which determine the different types of morphological involvement. A rare but specific entity is cholesterol pericarditis. This term is used in cases of chronic pericardial effusion with the presence of cholesterol crystals or an elevated concentration of cholesterol, or both¹. Cases associated with systemic diseases, such as tuberculosis, rheumatoid arthritis, and hypothyroidism have been reported, as have idiopathic cases.

The objective of this study was to report a case of cholesterol pericarditis and review the medical literature.

Case Report

The patient is a 40-year-old male from the city of Recife, in the Brazilian state of Pernambuco, who was referred to the Instituto do Coração with a diagnosis of pericardial effusion of unknown etiology. The patient reported that 6 months prior to hospital admission he began to feel progressively tired on exertion, and also noted edema in the lower limbs and enlargement of the abdominal volume. A chest X-ray depicted an enlarged cardiac silhouette. An electrocardiogram showed low-voltage QRS complexes. An echocardiogram revealed a significant pericardial effusion with no signs of restriction. The laboratory test results were as follows: total cholesterol of 322mg/dL; triglycerides of 386mg/dL; antinuclear factor, LE cells, and rheumatoid factor were negative. Measurements of thyroid hormones were as fol-

lows: T3=0.2 ng/mL (0.8-2.0); T4=1.2 µg/dL (4.5-12.5); and TSH >47 µIU/mL (0.3-4.5). The diagnostic hypothesis of pericardial effusion secondary to hypothyroidism was established and treatment with 50 µg of levothyroxine (Puran T4®) per day was started. As the patient remained clinically symptomatic in NYHA functional class IV, we decided to perform a pericardial drainage via video pericardioscopy on 9/5/98. An anterior pericardiotomy was performed, and 2000 mL of pericardial fluid of a gold-yellow color were withdrawn. Microscopic examination revealed the presence of multinucleated giant cells compatible with a chronic inflammatory process. The search for neoplastic cells, bacteria, and fungi was negative. Results of the biochemical analysis of the pericardial fluid were as follows: amylase, 65; cholesterol, 63 (normal up to 70mg/dL); glucose, 83mg/dL; triglycerides, 10mg/dL; total protein, 7.1; albumin, 5; and lactic dehydrogenase, 218 U/L. The anatomicopathological study revealed mild fibrosis, lymphocytic and plasmacytic infiltrate, and proliferation of capillary vessels. The material adhered to the pericardium consisted of a large amount of xanthomatous macrophages (fig. 1) and foreign body giant cells engulfing cholesterol crystals (fig. 2). Deposits of intracytoplasmic hemosiderin in the macrophages were also found. On the basis of these findings, the diagnosis of cholesterol pericarditis was made. After a 1-year ambulatory follow-up, no recurrence of the pericardial effusion was observed, and the patient remained asymptomatic.

Discussion

In 1919, Alexander² reported the first case of pericardial effusion with a sparkling gold paint appearance secondary to the presence of cholesterol. Since then, several cases of cholesterol pericarditis have been reported in the literature. The incidence of cholesterol pericarditis has not been progressively increasing due to the diagnosis and treatment of the associated diseases¹. Pericarditis has been reported associated with systemic diseases, such as tuberculosis, rheumatoid arthritis, and hypothyroidism, and idiopathic pericarditis has been reported as well.

Cholesterol pericarditis is not properly a pericarditis. It

Instituto do Coração do Hospital das Clínicas - FMUSP
Mailing address: Fábio Fernandes - InCor - Unidade Clínica de Cardiopatias Gerais - Av. Dr. Enéas C. Aguiar, 44 - 05403-900- São Paulo, SP, Brazil - E-mail: car_fabio@incor.usp.br
English version by Stela Maris C. Gandour

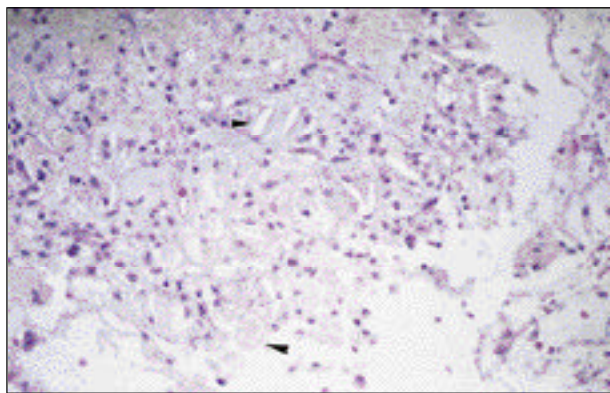


Fig. 1 - Cholesterol pericarditis: xanthomatous macrophages containing fat and crystals of cholesterol (HE, 10x).

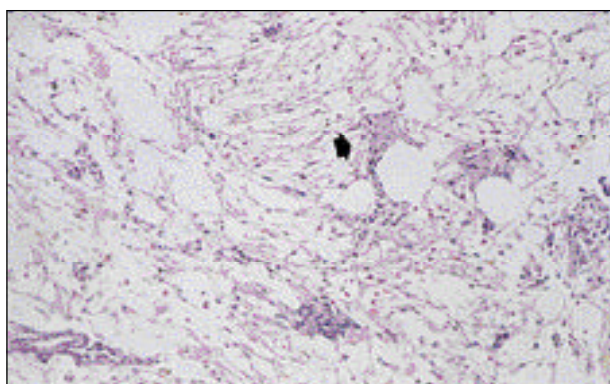


Fig. 2 - Multinucleated giant cells engulfing a large amount of crystals of cholesterol. (HE, 10x).

is a special type of pericardial effusion rich in LDL-cholesterol, which may form masses along with debris and fibrin, crystallizing over time and depositing in the pericardium, leading to pericarditis. LDL-cholesterol levels in the pericardial fluid are higher than those in the plasma, while in healthy individuals, they are lower³. Cholesterol pericarditis is secondary to recurring outbreaks of acute pericarditis, which in many situations are subclinical, resulting in inflammation with effusion, pericardial thickening, and change in the absorption capacity of the pericardium. The increase in cholesterol concentration, particularly of the LDL fraction, causes precipitation of the crystals, which, located in the pericardial membrane, trigger a granulomatous response of the foreign body type. The result is exudation of the pericardial fluid, which leads to effusion^{4,5}.

Clinically, cholesterol pericarditis may manifest as pericardial effusion, cardiac tamponade⁵, and constrictive pericarditis⁶. Usually, the patient remains asymptomatic for a long time, because pericarditis is secondary to chronic diseases, and, consequently, accumulation of the pericardial fluid is slow.

The diagnosis of cholesterol pericarditis is made by the presence of crystals of cholesterol or an elevated concentration of cholesterol in the pericardial fluid (above 70mg/dL).

Treatment of cholesterol pericarditis consists of the treatment of the underlying disease. In recurring cases, a pleuropericardial window is indicated, and, in more refractory cases, pericardiectomy may be a good therapeutical option.

Cholesterol pericarditis is a specific disease, even though rare, that should be considered in the course of chronic diseases involving the pericardium.

References

1. Torres S, Carvalho H, Moreira I, Gomes L, Pimenta A. Pericardite de colesterol. A propósito de um caso clínico. *Rev Port Cardiol* 1989; 8: 715-19.
2. Alexander JS. A pericardial effusion of gold paint appearance due to the presence of cholesterol. *Br Med J* 1919; 2: 463.
3. El Maraghi, NRH. Diseases of the pericardium. In: Silver MD (ed.). *Cardiovascular Pathology*. New York: Churchill Livingstone, 1983: 125-70.
4. Brawley RK, Vasko JS, Morrow AG. Cholesterol pericarditis: considerations of its pathogenesis and treatment. *Am J Med* 1966; 41: 235-48.
5. Ford EJ, Bear PA, Adams RW. Cholesterol pericarditis causing cardiac tamponade. *Am Heart J* 1991; 122: 877-9.
6. Stanley RJ, Subramanian R, Lie JT. Cholesterol pericarditis terminating as constrictive calcific pericarditis. *Am J Cardiol* 1980; 46: 511-4.