

Case 5/2013 - A Four-Year-Old Boy with a Rhabdomyoma-Type Cardiac Tumor in Both Ventricles and Repeated Ventricular Tachycardia

Edmar Atik

Clínica privada do Dr. Edmar Atik, São Paulo, SP – Brazil

Clinical data: Chest radiography performed during upper respiratory tract infection at 5 months of age suggested heart disease because of a deformity observed in the ventricular arch. At that time, echocardiography confirmed the presence of two tumor masses in both ventricles. At nine months of age, the patient started to present with episodes of paroxysmal ventricular tachycardia, with a heart rate of approximately 200 bpm, accompanied by diaphoresis and paleness, all reverted after electrical cardioversion. The episodes recurred for five times, despite the systematic use of antiarrhythmic medication comprising propranolol and amiodarone.

Physical examination: Active, eupneic, mucous membranes pink, normal pulses. Weight: 17 kg. Height: 97 cm. BP: 90/52-61 mmHg. HR: 100 bpm. Aorta non-palpable in the suprasternal notch area.

No deformities were observed in the precordium; the apical impulse was not palpable and there were no systolic impulses. The heart sounds were normal with no murmurs. The liver was not palpable.

Laboratory tests

Electrocardiogram (Figure 1) showed normal sinus rhythm and signs of left ventricular overload. QR complex in aVL with negative T wave in aVL and isoelectric in D1 were observed, thus characterizing the diagnosis of electrical ischemia of the high lateral wall. AP: +60°. AQRS: +80°. AT: +90°. During an episode of tachycardia, ECG showed complete right bundle branch block, with a ventricular rate of 210 bpm.

Chest radiography showed normal cardiac silhouette and pulmonary vascular network, and a deformity characterized by a mild bulging located in the middle of the left ventricular arch (Figure 1).

Keywords

Heart Neoplasms; Rhabdomyoma; Tachycardia, Ventricular.

Mailing Address: Edmar Atik •
Rua Dona Adma Jafet 74 , cj 73 01308-050 São Paulo, SP - Brazil
E-mail: conatik@incor.usp.br

DOI: 10.5935/abc.20130193

Ecocardiogram (Figure 2) showed two homogeneous and echodense images with well-defined round contours. The smallest was located in the right ventricular free wall and its diameters were 39 x 21 mm, with an area of 6.9 cm²; the largest, in the left ventricular anterior wall, was 51 x 37 mm, with an area of 12.5 cm². Both masses showed a cleavage plane with the contiguous ventricular walls and did not cause obstruction in the ventricular inflow and outflow tracts. Function of both ventricles was normal.

Tomography of the thoracic aorta (Figure 2) showed the same pattern, with the larger mass protruding from the left ventricle, however without causing obstruction to the flow.

Clinical diagnosis: Biventricular cardiac tumors without obstruction in the inflow and outflow tracts, no heart failure, but with repeated paroxysmal ventricular tachycardia. The tumors were classified as rhabdomyomas because of their multiple locations, well-defined cleavage plane with the myocardium, and for not causing obstruction to the flow.

Clinical reasoning: The clinical elements were consistent with a normal cardiovascular system, except for the electrocardiogram and chest radiography, which showed electrical ischemia of the high lateral wall and protrusion of the ventricular arch, respectively. These findings suggested the presence of a “mass” corresponding to the region described, presumably in the pericardium, myocardium or endocardium. Other imaging tests were decisive to find the ventricular intracavitary mass which projected itself in the left ventricular anterolateral wall, and was responsible for the abnormalities described. The other mass found in the free wall of the right ventricle was smaller and lacked clinical relevance.

Differential diagnosis: The abnormal findings observed in the electrocardiogram and chest radiography could also be present in pericardial processes such as cysts and tumors, or even in myocardial processes such as fibroma or other benign tumors.

Management: Because of the paroxysmal manifestation of the cardiac arrhythmia of left ventricular origin, of the right bundle branch block found on the electrocardiogram during a tachycardia episode, the dose of antiarrhythmic drugs was increased. If an adequate clinical response is not observed, surgical removal of the tumor becomes a priority, since the electrophysiological study was unable to demonstrate possible foci of arrhythmia.

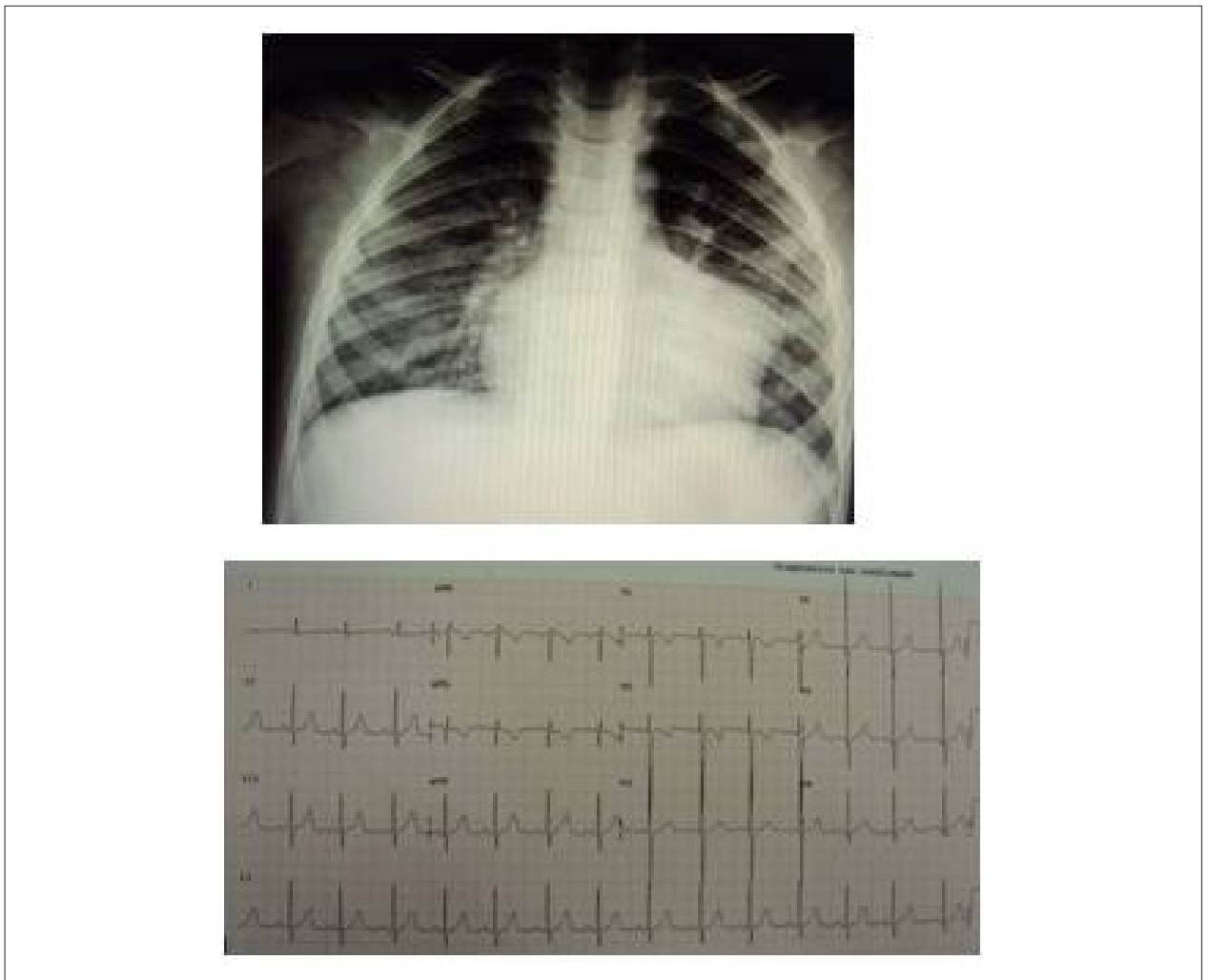


Figure 1 - Electrocardiogram showing electrical ischemia of the high lateral wall with characteristic abnormalities in D1 and aVL. Chest radiography shows a protrusion in the ventricular arch corresponding to the intracavitary left ventricular mass.

Comments: The clinical manifestations of benign tumors of the heart commonly include heart failure, supraventricular and ventricular arrhythmias, and sudden events such as syncope and low cardiac output, whether or not accompanied by cerebral symptoms. They are usually diagnosed during an episode of infection, convulsion or fainting. In the present case, chest radiography was the first test to raise the diagnostic hypothesis of a cardiac tumor because of the bulging observed in the ventricular arch. The electrical ischemia found in the electrocardiogram may characterize the exact location of the abnormality,

and the diagnostic imaging tests – echocardiography and MRI, confirmed the diagnosis. Today, arrhythmias in general may be better treated by means of more appropriate medications, or ablation after the triggering electrophysiological mechanism has been established, or even of surgical resection of the tumor mass that is causing the arrhythmia. All are valid and adequate options. A more conservative approach, with the use of antiarrhythmic drugs, should be the first option. Over time, other steps may be necessary to achieve the clinical control of the ventricular arrhythmia.

Clinicoradiological Session

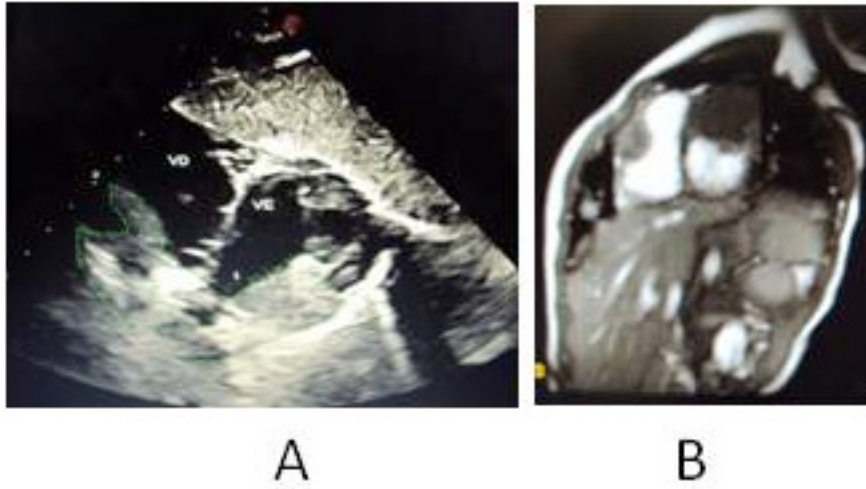


Figure 2 - Echocardiogram, in cross-sectional view, showing the diagnostic elements of the biventricular intracavitary mass not causing obstruction to the flow (A). Tomography shows that the tumor on the left side fills the ventricular cavity more than does the tumor on the right side (B).