

Minimally Invasive Procedures – Direct and Video-Assisted Forms in the Treatment of Heart Diseases

Josué Viana Castro Neto^{1,2}, Emanuel Carvalho Melo¹, Juliana Fernandes Silva¹, Leonardo Lemos Rebouças², Larissa Chagas Corrêa², Amanda de Queiroz Germano², João José Aquino Machado¹

Instituto do Coração do Nordeste (INCONE)¹, Fortaleza, CE; Universidade de Fortaleza (UNIFOR)², Fortaleza, CE – Brazil

Abstract

Background: Minimally invasive cardiovascular procedures have been progressively used in heart surgery.

Objective: To describe the techniques and immediate results of minimally invasive procedures in 5 years.

Methods: Prospective and descriptive study in which 102 patients were submitted to minimally invasive procedures in direct and video-assisted forms. Clinical and surgical variables were evaluated as well as the in hospital follow-up of the patients.

Results: Fourteen patients were operated through the direct form and 88 through the video-assisted form. Between minimally invasive procedures in direct form, 13 had aortic valve disease. Between minimally invasive procedures in video-assisted forms, 43 had mitral valve disease, 41 atrial septal defect and four tumors. In relation to mitral valve disease, we replaced 26 and reconstructed 17 valves. Aortic clamp, extracorporeal and procedure times were, respectively, $91,6 \pm 21,8$, $112,7 \pm 27,9$ e $247,1 \pm 20,3$ minutes in minimally invasive procedures in direct form. Between minimally invasive procedures in video-assisted forms, $71,6 \pm 29$, $99,7 \pm 32,6$ e $226,1 \pm 42,7$ minutes. Considering intensive care and hospitalization times, these were $41,1 \pm 14,7$ hours and $4,6 \pm 2$ days in minimally invasive procedures in direct and $36,8 \pm 16,3$ hours and $4,3 \pm 1,9$ days in minimally invasive procedures in video-assisted forms procedures.

Conclusion: Minimally invasive procedures were used in two forms - direct and video-assisted - with safety in the surgical treatment of video-assisted, atrial septal defect and tumors of the heart. These procedures seem to result in longer surgical variables. However, hospital recuperation was faster, independent of the access or pathology. (Arq Bras Cardiol. 2014; 102(3):219-225)

Keywords: Heart Diseases; Surgical Procedures, Minimally Invasive; Video-Assisted Surgery.

Introduction

The reconfiguration of the surgery is about a process through which this medical specialty incorporated the technical advances and became a practice over the past few years¹. These advances were important in making surgical procedures safer for patients. In this context, such said Minimally Invasive procedures (MI) has been introduced alternatively in heart surgery².

With the purpose of making universal the access in cardiovascular surgical procedures, from the beginning of 1960³, surgeons have adopted the total median sternotomy as the preferred incision, at the expense of initial thoracotomy⁴. With sternotomy it was enabled the access to all surfaces,

compartments and great vessels of the heart, with central cannulations. This access, which communicates widely the middle mediastinum with the operative environment, brought comfort to the surgeon. However, possibly due to the wide opening and also due to the inherent bone division, it has been considered a stigma for the patients to be operated.

In 1997, with incentives from previously published work by Laborde et al⁵, it was clear the necessity for a technical involvement for the development of an initial experience in video-assisted surgical procedures⁶. Continuing, in 1999 a project was developed with a focus on experimental laparoscopic surgery, which due to structural problems, has not moved on. Only since 2006 is that the team started to develop strong actions oriented to MI surgery, based on the initial experience of other authors^{7,8}. At this stage, it took intensive training and additional training of capabilities, the first procedures were performed from the end of 2007. The fact is that the process to achieve the method used nowadays was progressive and graduated.

This paper had the purpose of describing the methodology used and the immediate results obtained over 5 years experience in a total of 102 patients undergoing MI cardiovascular surgeries.

Mailing Address: Josué Viana Castro Neto •

Avenida Santos Dumont, 5.753/108, Papicu. Postal Code 60175-047, Fortaleza, CE – Brazil

E-mail: jvcn@uol.com.br, jvcn@cardiol.br

Manuscript received July 10, 2013; revised manuscript August 26, 2013; accepted September 26, 2013.

DOI: 10.5935/abc.20140004

Methods

In the period between December 2007 and December 2012, 102 patients underwent, after informed consent form was obtained, MI procedures. This single-center, prospective, descriptive, quantitative approach study evaluated the clinical and operative variables, in addition to the immediate evolution during hospitalization of the patients, and was approved by the ethics committee of the University of Fortaleza.

Selection of patients

Symptomatic patients with mitral, aortic and tricuspid heart disease, patients with septal defect and patients with cardiac tumor who underwent surgical procedures, with a recommendation of therapy grounded on the guidelines of cardiology societies⁹.

Exclusion criteria were: age superior to 70 years, body mass index > 32 kg/m²; patients with chronic obstructive pulmonary disease ($FEV_1/FVC < 0.7$); patients subjected to prior heart surgery; patients with renal failure, patients with prior surgical procedure in the right pleural cavity or inflammatory lung disease with significant pleura-pulmonary adhesions; patients with chest deformities and diffuse calcification of the ascending aorta, patients with important calcification of the valvular annulus, systolic pressure in pulmonary artery of > 80 mmHg, associated coronary artery disease not susceptible to coronary stent implantation (stent), severe tricuspid insufficiency, calcification of iliac or femoral artery, femoral artery diameter of < 5 mm and doubt in direct puncture of the femoral vessel; patients with heart valve disease or mitral septal defect with moderate or severe associated aortic insufficiency, and patients who, at some point, decided not to participate in the study.

Operative Technique

All procedures have been carried out in the form of MI. These were categorized in two levels:

Direct MI (D): procedure carried out by means of a < 8 cm incision and with preferential use of direct view;

Video-Assisted MI (VA): procedure carried out by means of four portals; working port or incision (4 cm) and three auxiliary portals (0.5 cm), with preferential use of imaging view obtained by optical and in monitor.

MI D Procedure

Individuals with aortic valvular heart disease, pulmonary valvular heart disease, aortic subvalvular heart disease, individuals with procedures in the aortic root and septal defect of venous sinus type were subjected to this type of surgical access.

The patient was positioned in supine position; peripheral venous and arterial punctures in the left upper limb were performed. Anesthetic induction was performed, and the patient was intubated with a usual endotracheal tube. The echocardiography esophageal tube was positioned. The central venous puncture was performed in the right subclavian vein, disposable plates for external cardioversion were positioned, and the catheter was inserted.

Access was made through an incision of approximately 6 cm in length. The sternal division was partial, from the jugular notch until the third right intercostal space (Figure 1). A bone saw was kept on the operating table during the procedure.

The pericardium was partially open and fixed to the fields, offering broad access to the upper mediastinum.

After administration of heparin at a dose of 4 mg/kg, the circulatory support was established by arterial cannulation in the ascending aorta and venous cannulation of the right femoral triangle by femoral vein puncture. The aortic occlusion was performed directly in the ascending aorta through hinged clamp. Myocardial protection was achieved with cold crystalloid solution rich in potassium. The operative field was flooded with continuous infusion of CO₂ at 2 L/min. When necessary, a vent was introduced in the left superior pulmonary vein to drain blood from the pulmonary venous return.

The procedure was performed preferably under direct view with the use of video reserved to clarify any questions and to assist the mediastinal drainage.

MI VA Procedure

Left and right intra-atrial interventions were subjected to the video-assisted surgical procedure with this type of access, i.e., valvuloplasty and valve replacement, closure of the atrial septal defect, removal of cardiac tumor, and arrhythmia ablation, all through thoracoscopy.

The initial preparation of the patient for this type of access was similar to that described for the direct MI form. The only modification was the positioning of the patient. A small right subscapularis cushion moved between 15 and 30° the patient in the supine position to the left.

Access was made through four intercostals portals. The portal or work incision of 4 cm (always maximized with soft tissue retractor, ALEXIS®) and three auxiliary portals of 0.5 cm (Figure 2). The work incision site varied according to the gender of the patient and the cardiac chamber to be addressed, but always directed to the fourth right intercostal space.

In men, the incision was subareola¹⁰ and oriented through the intercostal space of the pectoralis major muscle (transpeitoral). In women, the incision was made in the inframammary fold and oriented to the subpectoral space.

For left intra-atrial procedures, the skin incision was located between the mammary line and right anterior axillary line; for right intra-atrial procedures, the midpoint of the incision was the mammary line.

The support was provided through the peripheral arterial and venous cannulation in the right femoral triangle. Both cannulas were introduced by puncturing the vessel under direct view between 6.0 polypropylene sutures, with puncture needle, guidewire, dilator and the introduction and the correct positioning of the cannula confirmed by image obtained by echocardiography.

The selection of the arterial cannula was based on two variables: pre-operative internal diameter of the right femoral artery and the patient's body surface.

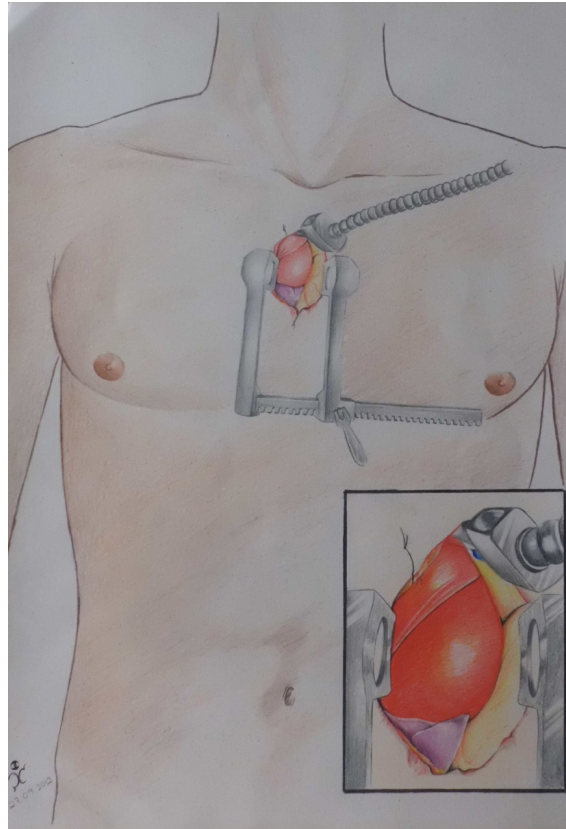


Figure 1 – Descriptive drawing of the direct minimally invasive procedure.

Through the three auxiliary portals of 0.5 cm located at the front of the right middle axillary line, the following was introduced: transthoracic clamp for aortic occlusion in the second space, optical of 0.5 cm in the fourth or fifth space and CO₂ vacuum/blower in the seventh intercostal space.

The operative field was permeated with continuous infusion of CO₂ at 2 L/min.

The pericardiotomy was performed from the aorta until the inferior vena cava, and pericardium fixed with three lower sutures, externalized through the auxiliary portals and two upper points fixed internally on the thoracic wall.

For the procedures in the left atrium, specific retractor was introduced. For procedures in the right atrium, exposure was obtained with points in the atrial wall, fixed in the pericardium.

Demographics

Among the 102 patients, 64 (62.75%) were women. Patients undergoing surgical therapy in the MI D form (n = 14) presented the following diseases: aortic valve heart disease (n = 13), septal sinus venosus defect (n = 1). The form of VA MI (n = 88) presented: mitral valvular heart disease (n = 43, and stenosis - n = 18, failure - n = 17

and mixed - n = 8); septal defect (n = 41, being ostium secondary - n = 37, primary ostium - n = 1 and permeable foramen ovale - n = 3), cardiac tumor (n = 4) (Table 1).

Results

The procedures of patients undergoing therapeutic MI D included aortic valve replacement (n = 11), valve repair (n = 1), valve replacement with annular enlargement (n = 1) and septoplasty with pulmonary flow redirection (n = 1).

The procedures of 88 patients undergoing therapeutic MI VA included valve repair (n = 17), valve replacement (n = 26), septorrhaphy (n = 22), septoplasty with pericardium (n = 19), tumor resection (n = 4).

In the group of patients with MI VA, it is noteworthy that the mitral repair consisted of five commissurotomy (associated with papillectomy in three cases), 11 partial resections of the leaflet with annuloplasty (semi-rigid ring in seven cases and pericardial strip in four) and in one case commissuroplasty with neochochord. In addition to the mitral valve procedures, four ultrasonic isolation of the pulmonary veins were carried out.

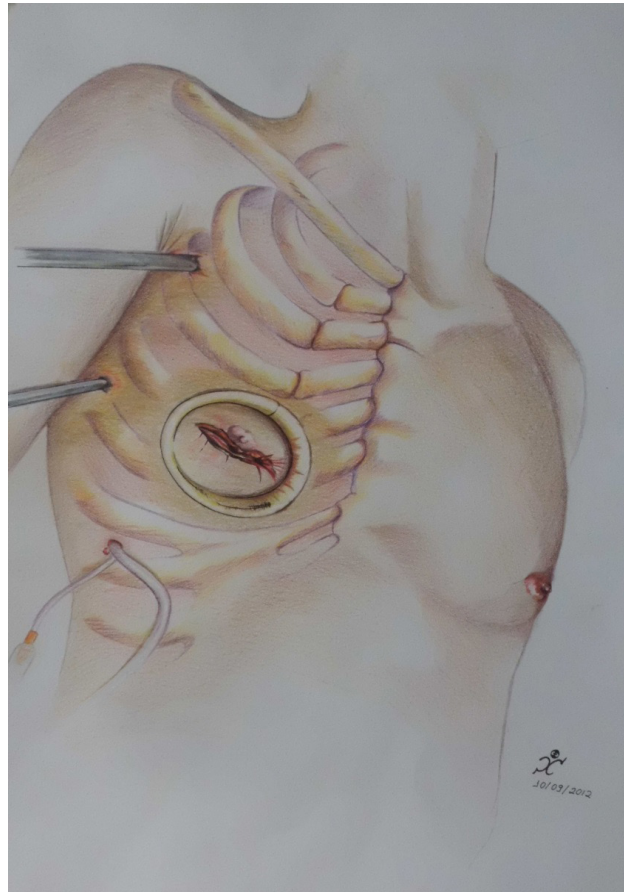


Figure 2 - Descriptive drawing of the right intra-atrial video-assisted minimally invasive procedure

Table 1 – Clinical variables

Clinical variable	MI D (n = 14)	MI VA (n = 88)	Total (n = 102)
Age (a)	39.7 ± 15.8	37.2 ± 12.5	37.6 ± 13
Gender (M/F)	9/5	29/59	38/64
Aortic CV	13	-	13
Septum Deffect	1	41	42
Mitral CV	-	43	43
Tumor	-	4	4

MI D: direct minimally invasive; MI VA: video-assisted minimally invasive; M: male; F: female; CV: valvular heart disease.

Mean aortic clamping time was 91.6 ± 21.8 minutes in the MI D group and 71.6 ± 29 min in the MI VA group. The mean cardiopulmonary bypass time was 112.7 ± 27.9 minutes in the MI D group and 99.7 ± 32.6 minutes in the MI VA group. These and other temporal variables are described in Table 2.

There was one death (0.98%) in the MI D group. There were two new episodes of atrial fibrillation that was pharmacologically reversed. There was one post-operative pericardial drainage in the MI D group and two revisions of hemostasis in the MI VA group. One patient in MI VA group reported transient numbness in the thigh, this being one of the first patients in the series. One patient developed pneumothorax requiring re-drainage. One female patient undergoing septoplasty presented reversed pulmonary hypertension with vasodilator. Among the patients submitted to VA MI, 15 (17%) has tubes removed

at the room. The final aspect of portals in one patient in MI VA group is shown in Figure 3.

Discussion

One of the foundations of the MI procedures, regardless of the form of access, consists of a well balanced and skilled team. Supporting this team, the following are important: Detailed knowledge of the inner and surface anatomy of the chest, careful selection of patients, use of proper equipment, development of skills and expertise in laparoscopic surgery; in addition, philosophical and conceptual change, and sheer determination are also necessary .

In fact, the Brazilian cardiac surgery, after an initial experience, is another of the surgical specialties to incorporate, in a more definitive manner, the MI surgical

Table 2 – Time variables

Variable	MI D	MI VA	Total
	(n = 14)	(n = 88)	(n = 102)
Clamping (min)	91.6 ± 21.8	71.6 ± 29	74.4 ± 28.9
CEC (min)	112.7 ± 27.9	99.6 ± 32.5	101.4 ± 32.2
Procedure(min)	247.1 ± 20.3	226.1 ± 42.7	228.1 ± 41.6
Tube removed in the room (%)	-	15 (17.04)	15 (17.04)
ICU (hours)	41.1 ± 14.7	36.8 ± 16.3	37.3 ± 16.2
Hospitalization (days)	4.6 ± 2	4.3 ± 1.9	4.4 ± 1.9

MI D: direct minimally invasive; MI VA: video-assisted minimally invasive; CEC: cardiopulmonary bypass; ICU: Intensive care unit.

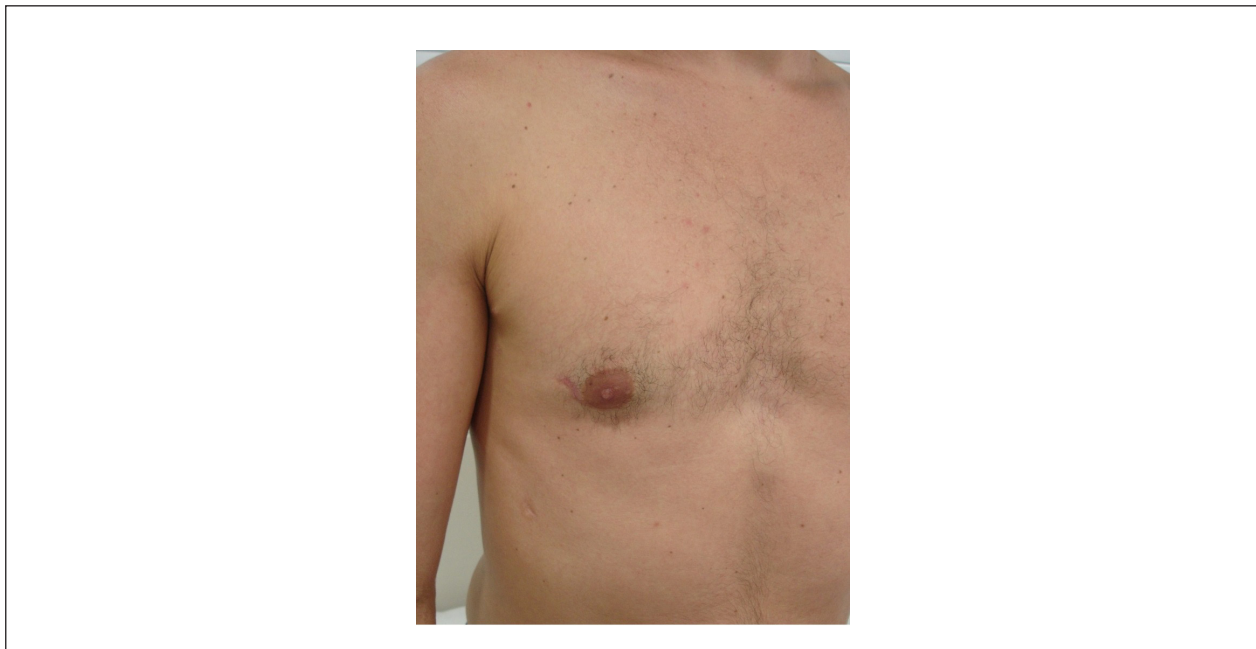

Figure 3 - Final result of the four portals in patient of the video-assisted minimally invasive procedure.

procedures. Nowadays, mitral valve surgery and correction of atrial septal defects surgery are performed with the same safety for the patient, as previously demonstrated¹¹⁻¹⁵. This benefit could be extended to other procedures: removal of cardiac tumors, surgical ablation, arrhythmia, pericardial procedures and dissection of grafts. This has boosted our experience, so that these video-assisted surgical procedures represent 24% of our surgical movement.

The process of incorporation of this methodology allowed our team to outline some priorities, such as heart surgery, clinical cardiology and pre-anesthetic consultation, this added to the assessment and guidance of physiotherapy and nursing. In addition to the usual tests needed - blood count, coagulation, biochemistry, urinalysis, electrocardiogram and chest radiograph in posteroanterior and profile views – we specifically ask for arterial ultrasound with doppler of the aortic, iliac and femoral arteries with quantification of the internal diameter of these vessels. The pre-operative evaluation of the coronary circulation is carried out in fairly stratified manner. In patients without major risk factors for myocardial ischemic disease, we prefer an assessment of the anatomy of the coronary arteries with CT angiography, associated with an ischemic provocative testing with myocardial scintigraphy and ergometric testing. Any changes, questions or greater risk recommended an invasive coronary angiography via the left femoral or upper limb.

Some authors reported extensive experience with this procedure¹⁶⁻¹⁹. This has shown that, in specialized centers, certain diseases can be preferentially addressed by MI accesses. All this accumulated experience has shown that the benefits include greater protection of the operated area, lower incidence of bleeding, less use of blood products, better pain control, less infection, better healing, shorter hospital stay, faster recovery and rehabilitation of the patient to its daily activities. The benefits can be extended to the members of the team: less contamination, better sharing of the operative field and better quality of life for the surgeon, with fewer visits and sharing of responsibilities. Moreover, some disadvantages can be indicated: access to two spaces in the chest, peripheral cannulation, increased surgical time in the adjustment curve of the method, higher cost for formatting the software and adaptation to specific instruments.

Among surgical patients, there was a predominance of females. In women undergoing MI VA procedure, the portal to work is very similar to the incision for breast augmentation. In this situation, the advantage is the subpectoral access without muscle division. On the other hand, Poffo et al¹⁰ introduce the periareolar access, which maximizes the cosmetic appearance, however implying in division of mammary glands and muscle division.

In MI D procedures, aortic valve heart disease has prevailed. A MI approach is already widely employed by others, in which the aortic valve replacement is performed by anterior right minithoracotomy²⁰. So there is an observation to be made, in those cases, about the impossibility of compression of the heart during

reperfusion phase, sometimes necessary in cases of significant myocardial hypertrophy. Therefore, I see just one limitation of this method, which may have contributed to the single death in the series.

Regarding MI VA procedures, mitral procedures and procedures for closure of atrial septal defect were predominant.

Among the mitral, valve replacement was the most common. However, 17 valves were repaired, which represents 40% of video-assisted surgical mitral procedures. This percentage can be considered low if we analyze the indexes for mitral valve repair in severe impairment of degenerative etiology²¹. However, considering that the valve injury was an isolated failure in only 17 patients and the inflammatory-rheumatic etiology was very common, this video-assisted surgical valve repair procedures index can be acceptable and comparable to the one reported in the literature for transternal access²².

Considering the septal procedures, there was a balance between the closure by suture and closure with pericardium. In closure by suture, we have modified our initial technique, which consisted of double continuous suture to suture with stitches separated in U, anchored in a Teflon cushion. Other authors have also shown good results, with video-assisted surgical procedure for the closure of septal defect²³.

Finally, four tumors were removed with MI VA access. The histopathological result was myxoma in all of them. We believe this is an excellent access to treat this disease, including verifying in details the interior of the left ventricle. This impression is also supported by other authors²⁰. It is here recorded the necessary attention to sessile tumors of the right atrium regarding the positioning of the cannula from the inferior vena cava and the use of vacuum, as well as the myxomas of papillary or villous type, which tend to be extremely friable in the left atrium and of high emboligenic risk.

Considering the temporal variables, we have noticed that, although long clamping time and cardiopulmonary bypass, this did not influence the patients' evolution. Rather, there was a rapid recovery in the Intensive Care Unit (ICU) and post-operative hospitalization. These findings confirm those already published in the literature that compared MI access and access by sternotomy^{2,15,24}.

Our impression is that cardiovascular surgeons today live a time of transformation in the specialty. Innovations and technical modifications may progressively be incorporated into surgical practice, should they make the procedure more precise and safe.

Conclusion

Minimally invasive procedures have been employed in two forms – Direct and Video-Assisted – safely in the treatment of valvular heart diseases, septum defect and heart neoplasia. We evidenced longer times of operative variables in these procedures. However, the recovery in hospital was fast, regardless of access and disease treated.

In selected cases, such forms of access may become the preferred method of surgical approach.

Author contributions

Conception and design of the research: Castro Neto JV, Melo EC; Acquisition of data: Silva JF, Rebouças LL, Correia LC, Queiroz AG; Analysis and interpretation of the data: Castro Neto JV, Melo EC, Silva JF; Statistical analysis: Rebouças LL, Correia LC; Writing of the manuscript: Castro Neto JV, Silva JF, Aquino JJM; Critical revision of the manuscript for intellectual content: Castro Neto JV.

References

1. Melo MC. A reconfiguração da cirurgia: uma nova percepção através da janela bidimensional. Recife: Prazer de Ler; 2010.
2. Falk V, Cheng DC, Martin J, Diegeler A, Folliguet TA, Nifong LW, et al. Minimally invasive versus open mitral valve surgery: a consensus statement of the International Society of Minimally Invasive Coronary Surgery (ISMICS) 2010. *Innovations (Phila)*. 2011;6(2):66-76.
3. Julian OC, Lopez-Belío M, Dye WS, Javid H, Grove WJ. The median sternal incision in intracardiac surgery with extracorporeal circulation: a general evaluation of its use in heart surgery. *Surgery*. 1957;42(4):753-61.
4. Neptune WB, Bailey CP. Mitral commissurotomy through the right thoracic approach: technique and indications. *J Thorac Surg*. 1954;28(1):15-22.
5. Laborde F, Noirhomme P, Karam J, Batisse A, Bourel P, Saint Maurice O. A new video-assisted thoracoscopic surgical technique for interruption of patient ductus arteriosus in infants and children. *J Thorac Cardiovasc Surg*. 1993;105(2):278-80.
6. Castro Neto JV, Vieira FM, Leite RR, Carvalho R, Sena JI, Pinheiro LG, et al. Estudo anatomopográfico do canal arterial em fetos natimortos dirigido para videotoroscopia. *Acta Cir Bras*. 2001;16(1):62-4.
7. Chitwood WR Jr, Wixon CL, Elbeery JR, Moran JF, Chapman WH, Lust RM. Videoassisted minimally invasive mitral valve surgery. *J Thorac Cardiovasc Surg*. 1997;114(5):773-82.
8. Mohr FW, Falk V, Diegeler A, Walther T, Van Son JA, Autschbach R. Minimally invasive port-access mitral valve surgery. *J Thorac Cardiovasc Surg*. 1998;115(3):567-76.
9. Bonow RO, Carabello BA, Kanu C, de Leon AC Jr, Faxon DP, Freed MD, et al. ACC/AHA 2006 guidelines for the management of patients with valvular heart disease: a report of the American College of Cardiology/American Heart Association Task Force on Practice Guidelines. *Circulation*. 2006;114(5):84-231.
10. Poffo R, Pope RB, Toschi AP, Mokross CA. Video-assisted minimally invasive mitral valve repair: periareolar approach. *Rev Bras Cir Cardiovasc*. 2009; 24(3):425-7.
11. Jatene FB, Pêgo-Fernandes PM, Hayata AL, Arbulu HE, Stolf NA, de Oliveira SA, et al. VATS for complete dissection of LIMA in minimally invasive coronary artery bypass grafting. *Ann Thorac Surg*. 1997;63(6):110-3.
12. Souto GL, Tinoco RC, Tinoco AC, Caetano CS, Souza JB, Paula AG, et al. Ligadura videotoracoscópica da persistência do canal arterial. *Rev Bras Cir Cardiovasc*. 2000;15(2):154-9.

Potential Conflict of Interest

No potential conflict of interest relevant to this article was reported.

Sources of Funding

There were no external funding sources for this study.

Study Association

This study is not associated with any thesis or dissertation work.

13. Poffo R, Pope RB, Selbach RA, Mokross CA, Fukuti F, da Silva Júnior I, et al. Video-assisted cardiac surgery: results from a pioneer project in Brazil. *Rev Bras Cir Cardiovasc*. 2009;24(3):318-26.
14. Fortunato Júnior JA, Branco Filho AA, Branco A, Martins AL, Pereira M, Ferraz JG, et al. Padronização da técnica para cirurgia cardíaca videoassistida: experiência inicial. *Rev Bras Cir Cardiovasc*. 2008;23(2):183-9.
15. Castro Neto JV, Melo E, Fernandes J, Gomes R, Freitas C, Machado J, et al. Cirurgia valvar mitral e da comunicação interatrial - abordagem minimamente invasiva ou por esternotomia. *Arq Bras Cardiol*. 2012;99(2):681-7.
16. Vanermen A, Van Praet F, Degrieck I, Casselman FP, Dossche KM, Deblier ID, et al. Endoscopic mitral valve repair. *Op Tech Thorac Cardiovasc Surg*. 2011;16(4):278-92.
17. Modi P, Hassan A, Chitwood WR Jr. Minimally invasive mitral valve surgery: a systematic review and meta-analysis. *Eur J Cardiothorac Surg*. 2008;34(5):943-52.
18. Seeburger J, Borger MA, Falk V, Kuntze T, Czesla M, Walther T, et al. Minimal invasive mitral valve repair for mitral regurgitation: results of 1339 consecutive patients. *Eur J Cardiothorac Surg*. 2008;34(4):760-5.
19. Modi P, Rodriguez E, Hargrove WC 3rd, Hassan A, Szeto WY, Chitwood WR Jr. Minimally invasive video-assisted mitral valve surgery: a 12-year, 2-center experience in 1178 patients. *J Thorac Cardiovasc Surg*. 2009;137(6):1481-7.
20. Glauber M, Miceli A, Gilmanov D, Ferrarini M, Bevilacqua S, Farneti PA, et al. Right anterior minithoracotomy versus conventional aortic valve replacement: a propensity score matched study. *J Thorac Cardiovasc Surg*. 2013;145(5):1222-6.
21. Castillo JG, Anyanwu AC, Fuster V, Adams DH. A near 100% repair rate for mitral valve prolapse is achievable in a reference center: implications for future guidelines. *J Thorac Cardiovasc Surg*. 2012;144(2):308-12.
22. Bakir I, Onan B, Onan IS, Gul M, Uslu N. Is rheumatic mitral valve repair still a feasible alternative? Indications, technique, and results. *Tex Heart Inst J*. 2013;40(2):163-9.
23. Vistarini N, Aiello M, Mattiucci G, Alloni A, Cattadori B, Tinelli C, et al. Port-access minimally invasive surgery for atrial septal defects: a 10-year single-center experience in 166 patients. *J Thorac Cardiovasc Surg*. 2010;139(1):139-45.
24. Iribarne A, Russo MJ, Easterwood R, Hong KN, Yang J, Cheema FH, et al. Minimally invasive versus sternotomy approach for mitral valve surgery: a propensity analysis. *Ann Thorac Surg*. 2010;90(5):1471-8.