

Persistent Respiratory Insufficiency Secondary to Diastolic Heart Failure

José Acylino de Lima Neto, Claudio Buarque Benchimol, Ricardo Segadas Acylino de Lima

Rio de Janeiro, RJ - Brazil

This study assessed two 85-year-old patients diagnosed with diastolic heart failure and persistent respiratory insufficiency characterized by severe obstructive ventilatory disorder and gas exchange alterations. The possibility that the respiratory impairment was consequent to primary pulmonary disease was excluded. Radiological signs of mild pulmonary edema had been observed in 1 of the patients during the 4 years preceding the first hospitalization. The respiratory findings were attributed to pulmonary lesions conditioned to the presence of chronic pulmonary edema. The incidence of the disease in very elderly patients may create an illness that can be called congestive pulmonary disease.

The incidence and prevalence of congestive heart failure have progressively increased in industrialized countries, because of their population aging and the longer survival of individuals with coronary artery disease¹. Consequently, an increasing number of clinical findings, as of yet unknown, may be present in elderly patients with congestive heart failure.

This study assesses 2 elderly patients with diastolic heart failure, who developed severe and persistent respiratory impairment, which led to death. The possibility that the respiratory findings could be attributed to primary pulmonary disease was ruled out based on clinical data and complementary tests. These respiratory findings, characterized by the presence of severe obstructive ventilatory disorder and important and persistent gas exchange alterations, also differ from the respiratory manifestations already described in chronic congestive heart failure.

Case report

Case 1 - The patient was an 85-year-old man, who sought medical care at the Hospital São Vicente de Paulo in August 1998 for the first time, when, reporting worsening of the dyspnea initiated months before, he was brought to the emergency unit and immediately referred to the ICU. The patient denied antecedents of smoking and of respiratory disease, but reported exposure to vegetal coal in an open environment during work.

On physical examination, the patient was restless, objectively dyspneic, cyanotic, and had jugular venous distension at 90°. The use of the inspiratory musculature was markedly visible, and the respiratory sounds were intensely and diffusely reduced. His heart rate was 104 bpm with regular rhythm, and his blood pressure was 190/100 mmHg. His abdomen was distended and hypertympanic. The lower limbs were not edematous, but signs of chronic venous insufficiency existed. Previous chest X-rays performed during the 4 years preceding his first visit to our hospital showed alterations compatible with mild pulmonary edema (fig. 1A and 1B).

His first arterial blood gas analysis in the ICU showed PO₂ of 26.5 mmHg and PCO₂ of 67.4 mmHg. The diagnosis of respiratory insufficiency was established and a ventilatory prosthesis was installed. The echocardiogram showed preserved systolic function (this result was repeated in all tests performed later, the left ventricular ejection fraction being always above 70%), and pulmonary capillary pressure oscillating from 15 to 23 mmHg in the first 24 hours. The chest X-rays had alterations characteristic of pulmonary congestion. The pulmonary arteriography was negative for thromboembolic disease and showed an increase in the caliber of the pulmonary arteries. A pulmonary biopsy was performed, the result being negative for primary pulmonary disease and compatible with pulmonary edema. In the ICU, the patient received diuretics and vasodilators discontinuously. He improved progressively, which allowed ventilator weaning and discharge from the ICU.

Signs of pulmonary congestion persisted on chest computed tomography 30 days after his hospitalization (fig. 1C). Diuretics were started on a regular basis, which resulted in a significant improvement confirmed on the exami-

Pneumology Service of the Hospital São Vicente de Paulo - Rio de Janeiro, RJ
Mailing address: Dr. José Acylino de Lima Neto - Rua Cel. Antonio Ribeiro, 36
Cep 37472-000 - Carmo de Minas, MG, Brazil - E-mail: acylino@starweb.com.br
Received: 7/29/02
Accepted: 8/11/03
English version by Stela Maris C. e Gandour

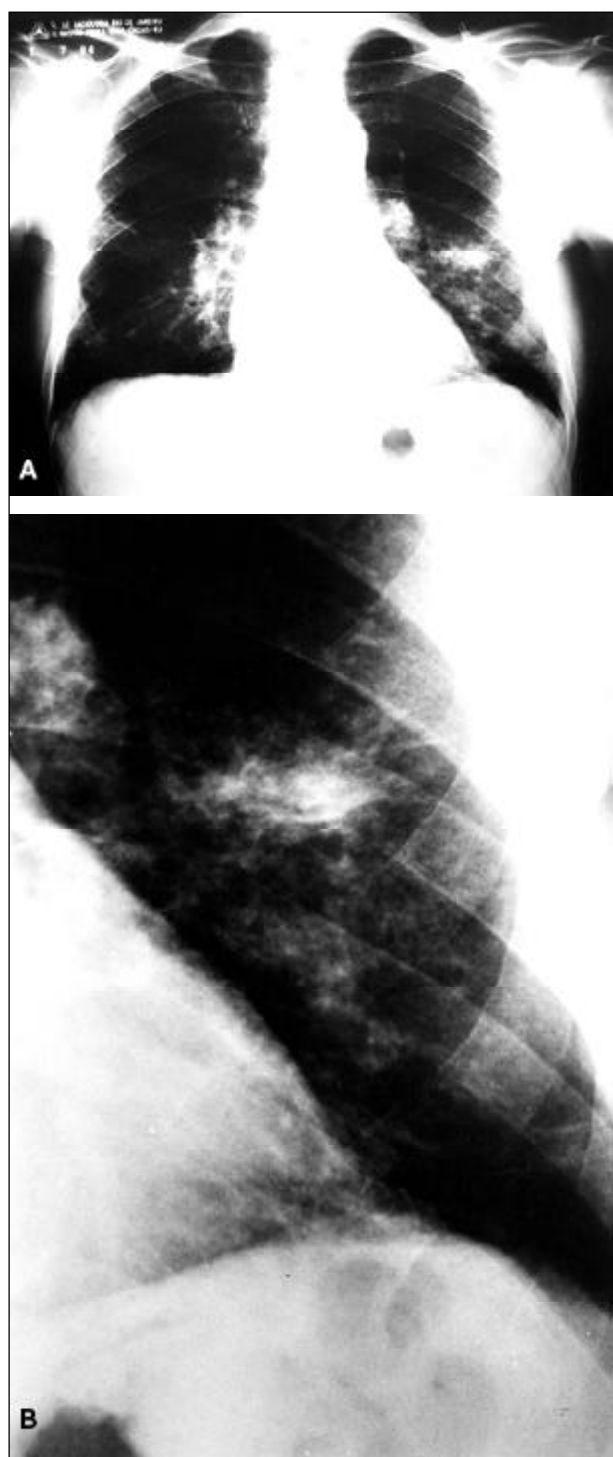
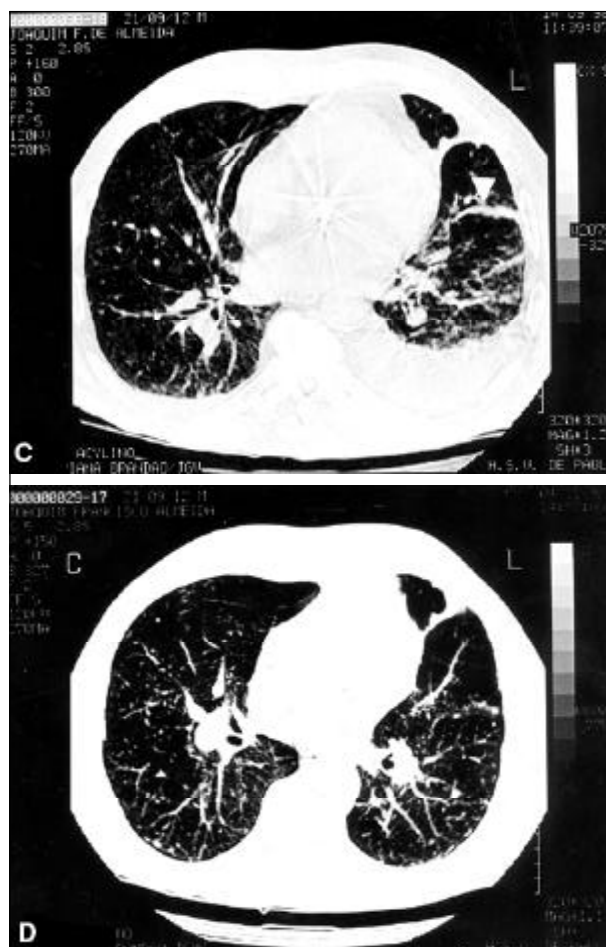


Fig. 1 - Radiological examinations in case 1 - A) radiography performed 4 years before the first hospitalization, where the image of subpleural edema along a lobar septum can be seen; B) detail of the same radiography focusing the Kerley B line in the base of the left lung.

nation performed 40 days after the beginning of that medication (fig. 1D). Gas exchanges also improved with the introduction of the diuretics, allowing the patient to be discharged from the hospital.

Despite the evident progress obtained with the diuretics, which resulted in normalization of the PCO_2 on the first



Cont. Fig. 1 - Radiological examinations in case 1 - C) chest computed tomography showing the presence of bilateral pleural effusion, subpleural infiltration (arrow), nodular images, and septal thickenings; D) chest computed tomography after regular use of diuretics showing regression of the pleural effusion and of the pulmonary infiltrations.

ambulatory assessment (36.6 mmHg), the patient remained with a severe and irreversible hypoxemia during his entire evolution (fig. 3). The ventilatory assessment indicated the presence of severe obstructive syndrome. The forced expiratory volume in 1 second to forced vital capacity ratio (FEV1/FVC) was 45%.

During ambulatory follow-up, the patient continuously used diuretics, theophylline, and domiciliary oxygen. However, this medication could not prevent the occurrence of progressive intolerance to effort and exacerbations of respiratory insufficiency, which resulted in repeated hospitalizations. The patient died in June 1999.

Case 2 - The patient was an 85-year-old retired military male, asymptomatic on his first visit to the Hospital São Vicente de Paulo in February 2000. He reported being hospitalized 3 months before, when the diagnoses of pneumonia and pleural effusion were established. Radiographies performed on that occasion showed signs of mild pulmonary edema (fig. 2A). The patient reported that later he underwent thoracentesis to clarify a left pleural effusion, but the result was inconclusive. He reported quitting smoking 30 years before and denied previous diseases and respiratory symptoms.

The physical examination was almost normal. His heart rate was 70 bpm and his blood pressure was 130/60 mmHg. The results of the ventilatory function test performed in the preceding year showed a forced expiratory volume in 1 second to a forced vital capacity ratio (FEV1/FVC) of 37%. The first measurement of the arterial gases showed a PO₂ of 60.2 mmHg and a PCO₂ of 48.3 mmHg. The chest radiographies showed the presence of free pleural effusion. The patient underwent thoracentesis with a pleural biopsy, but again the results were unspecific. Pulmonary scintigraphy was negative for thromboembolic disease.

In May 2000, the patient complained of intolerance to effort for the first time, spontaneous and complete regression of the pleural effusion then being observed. In January 2001, the patient returned complaining of fatigue. The electrocardiogram showed fibrosis in the inferior wall. In the following 6 months, dyspnea increased, nocturia and cough appeared, and rales persisted in the left pulmonary base (the patient used to lie in the left lateral decubitus position). In July 2001, the patient had edema of the lower limbs, being hospitalized then for the first time. A new evaluation of the ventilatory function confirmed the presence of severe obstructive syndrome. Chest computed tomography identified signs of pulmonary edema in the left inferior lobe (figs. 2B and 2C). Sequential measurements of the arterial gases showed persistence of hypoxemia (fig. 3). Partial and temporary improvements were obtained with the use of diuretics, vasodilators, and theophylline. Five echocardiograms were performed throughout the evolution period, all of which showed preservation of systolic function with the left ventricular ejection fraction greater than 70%.

In October 2001, the patient was hospitalized again. During this new hospitalization, a negative angiotomography for thromboembolic pulmonary disease and the marked elevation in the serum levels of the cerebral natriuretic peptide – 931 pg/mL (fluorescent immunoassay – Biosite, BNP) – contributed to confirmation of the diagnosis of heart failure. Irreversible deep coma occurred due to cardiopulmonary arrest, and the patient died in December 2001.

Discussion

Respiratory findings conditioned by congestive heart failure have long been well known; in 1833, Hope introduced the term cardiac asthma². Currently, the knowledge about the pulmonary alterations associated with chronic congestive heart failure has been the object of extensive reviews^{2,4}, but a report on the pulmonary manifestations attributed exclusively to diastolic heart failure is still lacking.

The respiratory function assessed at rest in patients with chronic congestive heart failure has long been known to be impaired. The alterations are as follows: irregularity between ventilation and perfusion; a reduction in pulmonary distensibility; obstruction of the airways; bronchial hyperreactivity; a reduction in the capacity of pulmonary diffusion; and a reduction in the strength and resistance of the respiratory muscles^{2,3}.

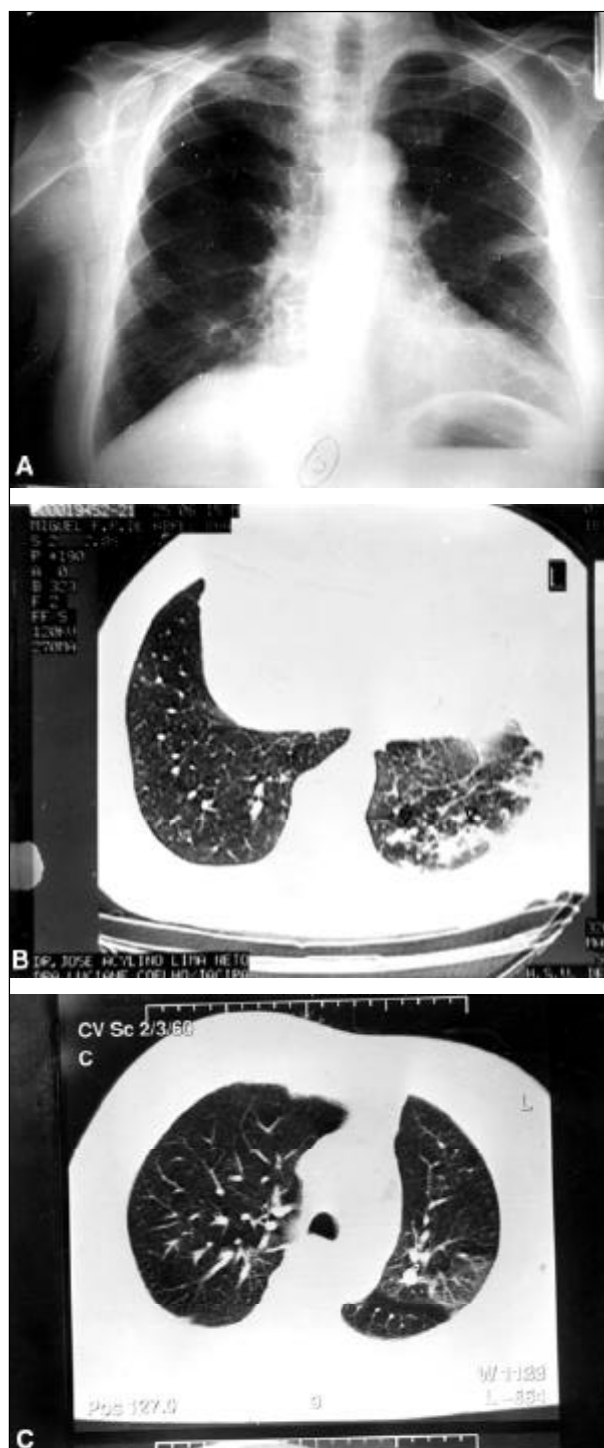


Fig. 2 - Radiological examinations in case 2 - A) radiography performed at the beginning of the evolution evidencing the presence of subpleural effusion; B) chest computed tomography showing peribronchovascular interstitial thickening (arrows) in the inferior lobe of the left lung; C) chest computed tomography showing an increase in the diameter of the vessels and "ground glass" infiltration.

Obstructive ventilatory alterations in patients with congestive heart failure have been reported by several authors according to reviews. Light and George³ reported evidence of obstructive ventilatory disorder in 53% of their nonsmoking patients with the disease. However, only one of them had the FEV1/FVC ratio below 60% in the best test ob-

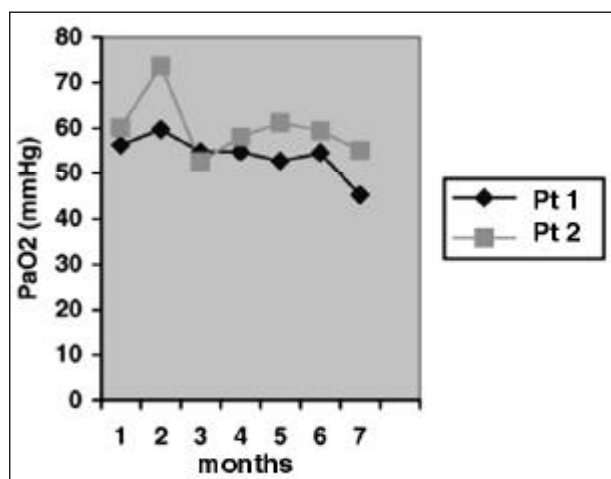


Fig. 3 - Sequential values of PO_2 corresponding to the best result obtained during the months the examination was performed, with patients spontaneously breathing room air.

tained during the period observed, indicating that, in that group, most patients had mild obstructive ventilatory disorder. Petermann et al⁴ also reported a mild obstructive disorder in 60 patients with decompensated congestive heart failure, with no significant impairment in gas exchanges. Other authors reported a significant bronchodilating response to the use of salbutamol and ipratropium bromide, indicating that chronic congestive heart failure may result in a mild obstructive ventilatory disorder. Experimental evidence associating peribronchial vascular congestion and increased airway resistance supports this finding⁵.

Caruana et al⁶ ruled out the diagnosis of diastolic heart failure in some of their patients because they had FEV1 results < 70% of the foretold value, which, according to the above reported, is unacceptable. These same authors did not try to correlate this finding with antecedents of smoking and other clinical and radiological findings characteristic of primary obstructive pulmonary disease, which should have been considered to correctly establish the diagnosis of chronic obstructive pulmonary disease. Despite the flaws in their methods, these authors were recently cited in 2 studies^{7,8}, as providing examples of patients with respiratory disorders incorrectly diagnosed as having diastolic heart failure. In fact, we believe that, at least in the population older than 75 years, the inverse has been more frequent, ie, patients with diastolic heart failure and associated obstructive ventilatory disorder are erroneously labeled as having chronic obstructive pulmonary disease.

Spirometry of our 2 patients revealed the presence of severe obstructive ventilatory disorder, although both responded to the use of salbutamol. In their cases, the diagnosis of chronic obstructive pulmonary disease was ruled out due to the lack of chronic cough, significant smoking, radiological signs of emphysema, and histological alterations compatible with disease in lung biopsy, among others. The unequivocal signs of fluid accumulation in the lungs and pleural space contributed to rule out the diagnosis of the

disease (figs. 1 and 2), because these are not part of the natural history of that illness. These data left us with no option other than attributing this severe obstructive disorder to diastolic heart failure corroborating the findings of Light and George³. However, in contrast with the mild abnormalities described by these authors, our patients showed severe obstruction ($FEV_1/FVC < 50\%$). This difference can be, in part, attributed to patient's age, since these authors patients aged 75 years or less.

Severe and persistent alterations in gas exchanges have also been observed in our patients. The insaturation of arterial oxygen, which has been referred to as uncommon in chronic congestive heart failure, even when measured during exercise, was present in our patients throughout several months of follow-up (fig. 3). In the first patient, a PO_2 of 53.7 mmHg measured with oxygen supplementation at 5 L/min through a nasal catheter prior to the introduction of diuretics evolved to 56.3 mmHg with room air in 5 days of regular use of that medication. However, his best result did not exceed 59.8 mmHg with room air during ambulatory follow-up.

PCO_2 was elevated, characterizing the presence of severe hypoventilation during the exacerbations of the disease. The substantial improvement observed in the first patient 5 days after the regular introduction of diuretics translated the improvement in the ventilatory function obtained with the removal of the fluid accumulated in the lungs and in the pleural cavity (fig. 1D), with a consequent reduction in the respiratory work overload.

These functional alterations maintained even after confirming the regression of the radiological signs of fluid accumulation in the lungs and in the pleural cavities were attributed to structural alterations induced in the lungs by chronic hydrostatic pulmonary edema². They consisted of intense proliferation of fibroblasts and histiocytes in the alveolar septa, resulting in dense deposits of collagen fibers that Bachofen et al⁵ denominated congestive pulmonary fibrosis, which may lead to compression of the small adjacent airways. The pulmonary blood vessels of all dimensions undergo important changes, among which are the deposition of dense connective tissue in the intima and adventitia layers^{2,5}. An intense proliferation of type II pneumocytes is still observed, translating into the presence of a reparative activity, as are alveolar macrophages phagocytizing proteins and red blood cells. Fragmentation of the capillary basal membrane, when present, correlates with the duration and severity of the disease.

These morphological and functional alterations associated with chronic hydrostatic pulmonary edema have been intensely investigated aiming at clarifying their possible participation in the pathophysiology of intolerance to exercise, characterizing chronic congestive heart failure^{2,9}. However, our clinical observations suggest that, similarly to that which has already been experimentally confirmed, more than contributing to the intensification of the symptoms, they can damage the pulmonary parenchyma and originate severe functional disorders, which have not been reported in the literature so far, requiring the chronic use of supplementary oxygen.

The pulmonary manifestations induced by chronic congestive heart failure tend toward irreversibility. The description of extensive fibrosis in the alveolar septa and pulmonary vessels points towards this direction⁵. Other indications of irreversibility are the persistence of the reduced capacity of pulmonary diffusion after cardiac transplantation and absence of enhancement in the alterations of pulmonary function after improvement in left ventricular function obtained with the use of carvedilol. These irreversible alterations or alterations of complex reversibility seem to influence the prognosis of the disease, worsening it.

In conclusion, our patient cases suggest that, with an insidious course in elderly individuals, diastolic heart failure may cause pulmonary impairment, whose severity may apparently overlap that of the hemodynamic disorder causing it. Its slow start, fortunately documented in one of our

patients, seems to be marked by mild clinical and radiological manifestations, which are spontaneously reversible. Over time, structural and functional alterations end up resulting in severe respiratory findings, marked by the presence of obstructive ventilatory syndrome and changes in arterial gases. In this stage, the use of diuretics, although able to revert the characteristic images of hydrostatic pulmonary edema, is not able to revert the functional changes.

In the literature about diastolic heart failure, no reference was found about the characteristic respiratory manifestations of this disease. They may appear, as the disease is better assessed and conceptualized. Further investigations are required to confirm, or not, whether advanced cases of the disease may effectively result in this severe respiratory syndrome, which could be called congestive pulmonary disease.

References

1. Sharpe N, Doughty R. Epidemiology of heart failure and ventricular dysfunction. *Lancet* 1998; 352(suppl I): 3-7.
2. Mancini DM. Pulmonary factors limiting exercise capacity in patients with heart failure. *Prog Cardiovasc Dis* 1995; 37: 347-70.
3. Light RW, Geoge RB. Serial pulmonary function in patients with heart failure. *Arch Intern Med* 1983; 143: 429-33.
4. Petermann W, Barth J, Entzian P. Heart failure and airway obstruction. *Int J Cardiol* 1987; 17: 207-09.
5. Bachofen H, Bachofen M, Weibel ER. Ultrastructural aspects of pulmonary edema. *J Thorac Imag* 1988; 3: 1-7.
6. Caruana L, Petrie MC, Davie AP, McMurray JJV. Do patients with suspected heart failure and preserved left ventricular systolic function suffer from "diastolic heart failure" or from misdiagnosis? A prospective descriptive study. *Br Med J* 2000; 321: 215-18.
7. Vasan RS, Benjamin EJ. Diastolic heart failure – No time to relax. *N Eng J Med* 2001; 344: 56-9.
8. Senni M, Redfield MM. Heart failure with preserved systolic function. A different natural history? *J Am Coll Cardiol* 2001; 38: 1277-82.
9. Myers J, Salleh A, Buchanan N, et al. Ventilatory mechanisms of exercise intolerance in chronic heart failure. *Am Heart J* 1992; 124: 710-19.