

Recurrent Infection in a Late Presentation of Catecholaminergic Polymorphic VT

Sérgio Craveiro Barra, Ana Catarina Faustino, Rui Providência, Maria Carmo Cachulo, José Nascimento
Coimbra Hospital and University Centre

Introduction

Catecholaminergic polymorphic ventricular tachycardia (CPVT) is characterized by episodic syncope resulting from fast VT (bidirectional or polymorphic) occurring during exercise/acute emotion in individuals without structural cardiac abnormalities. Mean age of onset is between seven and nine years, although onset as late as the fourth decade of life has been reported. We present the oldest reported patient with index event of CPVT.

Our patient's atypical condition, already emphasized by a very late CPVT event, included multiple consecutive episodes of device-related infection.

Case Report

A 45-year-old male patient, the offspring of consanguineous (first-cousin) parents and with mild hepatic dysfunction (alcoholic etiology), was admitted for syncope associated to acute anxiety. Family history of sudden death (SD) was reported: four brothers had died suddenly at ages 10-20 (autopsies inconclusive, but deaths reportedly attributed to epilepsy). He denied ever having had palpitations, dyspnea, syncope or chest pain. Physical examination was unremarkable, except for mild bruising/ecchymosis in both feet, and baseline electrocardiogram showed sinus tachycardia, only (due to anxiety). At the emergency department, an episode of sustained polymorphic VT [pVT] (with intermittent beat-to-beat axis variation) caused presyncope (Figure 1). Echocardiogram, cardiac-MRI and coronary angiography results were normal, but exercise stress testing disclosed runs of non-sustained ventricular arrhythmia starting at the second stage of Bruce protocol (isolate premature ventricular complexes, progressively followed by bigeminy, couplets and runs of non-sustained VT) (Figure 2). Programmed electrical stimulation failed to induce ventricular arrhythmias, but isoprenaline at increasing infusion rates led to spontaneous short bursts of non-sustained pVT.

Keywords

Tachycardia, Ventricular; Anti-Bacterial Agents / adverse effects; Drug Hypersensitivity; Pericarditis.

Mailing Address: Sérgio Craveiro Barra •

Centro Hospitalar e Universitário de Coimbra - Hospital Geral (Hospital dos Covões), Serviço de Cardiologia - Quinta dos Vales - 3041-801
S. Martinho do Bispo - Coimbra, Portugal
E-mail: sergioncbarra@gmail.com
Manuscript received March 17, 2012; revised manuscript June 18, 2012; accepted June 18, 2012.

Syncope caused by bidirectional or pVT induced by acute anxiety despite absence of structural heart disease or baseline electrocardiographic abnormalities suggested CPVT, especially considering family history of SD and early induction of malignant ventricular arrhythmias during exercise stress testing. Nevertheless, genetic testing was negative for ryanodine receptor channel (RYR2) and calsequestrin (CASQ2) gene mutations. A beta-blocker was prescribed (plus Diazepam SOS) and a defibrillator (ICD) was implanted (ICD lead inserted through left subclavian vein). Following the procedure, the patient developed a hematoma that resolved conservatively. Three weeks later, the patient received appropriate defibrillator shock for fast VT, with no further recurrence.

Exercise stress tests were performed on the remaining patient's brothers. Following early induction of sustained VT in one brother with history of syncope, an ICD was implanted.

The following paragraphs summarize subsequent hospitalizations:

- **Month 4:** Pocket infection causing generator extrusion, exudate positive for multiresistant *Staphylococcus epidermidis*. Three-week course of vancomycin prematurely interrupted (18th day) due to severe thrombocytopenia/leukopenia and generalized exanthema/pruritus. Device extraction, but one week later, unexpected hemodynamic shock (septic/allergic?) was aggressively treated with fluid resuscitation, dopamine, prednisolone, linezolid (four-week treatment). Transesophageal echocardiogram performed two weeks later revealed no signs of IE.
- **Month 6:** End of four-week linezolid treatment and new generalized petechial rash, pruriginous desquamative dermatitis, fever, kidney failure, severe thrombocytopenia. ICD pocket abscess documented and surgically drained. Patient started on meropenem. Exudate cultures subsequently positive for vancomycin-resistant *Staphylococcus aureus* and allergic reaction to meropenem (generalized exanthema/pruritus), then replaced by linezolid (four-week treatment). Three weeks after starting linezolid, as patient remained afebrile and had very low inflammatory markers, ICD re-implantation on contralateral side and patient was discharged soon thereafter on antibiotic therapy. One week later, a new pocket hematoma occurred.
- **Month 7:** Twelve days following previous discharge, patient was re-admitted for sepsis and urticarial exanthema. Possibility of allergy to amoxicillin (initiated three days before for respiratory infection), but echocardiogram disclosed a two-square centimeter mass adherent to

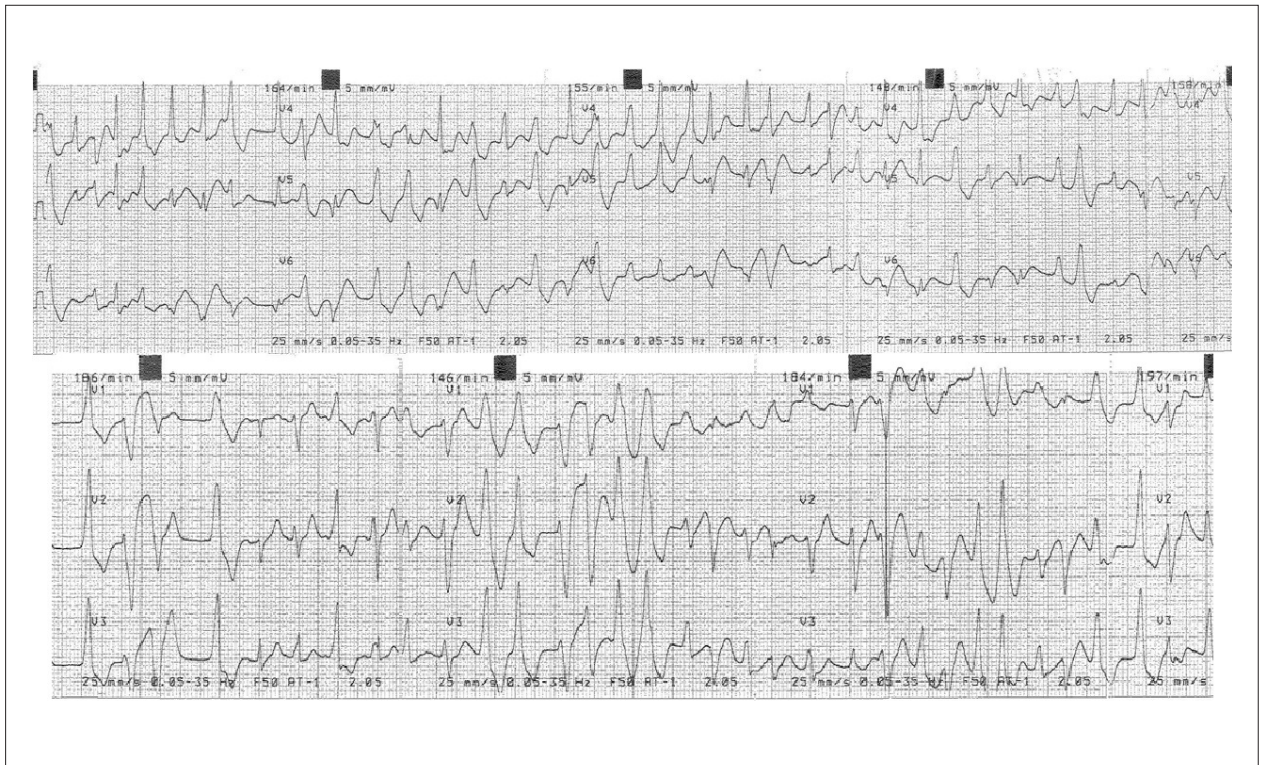

Figure 1 – Polymorphic ventricular tachycardia with intermittent periods of alternating bidirectional QRS axis.




Figure 2 – Induction of ventricular tachycardia during exercise stress testing.

Case Report

defibrillator lead. Patient was restarted on linezolid (five-week treatment). Intracardiac mass was eliminated.

- **Month 9:** Patient re-admitted for new pocket infection. ICD was extracted and new antibiotic course initiated. Considering high risk of reinfection and patient preference, defibrillator was not re-implanted.

Six months later, patient is asymptomatic. Patient's brother had several runs of non-sustained VT during follow-up, but no pocket hematoma/infection was reported.

Discussion

CPVT is a potentially lethal inherited arrhythmogenic disorder, characterized by adrenergically-mediated ventricular arrhythmias, typically bidirectional or pVT, manifested especially in children/teenagers¹. We present the case of a 45-year-old patient diagnosed with CPVT following its first manifestation.

To our knowledge, this is the oldest reported patient first presenting with this condition, which raised diagnostic doubts, especially considering genetic testing was negative for RYR2/CASQ2 mutations. However, the clinical picture was highly suggestive of CPVT:

- Syncope caused by pVT during acute emotion;
- Alternating 180° QRS axis on beat-to-beat basis (bidirectional VT), although irregular pVT without stable QRS vector alternans was also documented;
- Ventricular arrhythmias of progressive complexity during exercise stress testing and isoprenaline infusion;
- Absence of electrocardiographic and structural cardiac abnormalities, electrolyte imbalance or drug treatment potentially associated to pVT.

Furthermore, mutations in the RYR2 and CASQ2 genes account for 51-56% of CPVT cases only, showing significant locus heterogeneity. The presence of other as-yet unidentified/unmapped loci has been postulated².

CPVT should be considered in the differential diagnosis of adrenergically-mediated syncope in otherwise healthy individuals. Presence/absence of right ventricular structural abnormalities must be evaluated to exclude presence of a rare variant of arrhythmogenic right ventricular cardiomyopathy (ARVC) allelic to RYR2-related CPVT³. Our patient's right ventricle showed normal structure/contractility in cardiac MRI and programmed electrical stimulation could not induce ventricular arrhythmias, contrary to isoprenaline infusion, favoring catecholamine sensitive automaticity as the mechanism for this VT (contrary to the reentry mechanism of ARVC). Short-coupled VT resembles CPVT; however, it lacks an association between arrhythmic episodes and adrenergic stimuli and typical bidirectional pattern of CPVT⁴. Exercise-related syncope is also found in LQT1 variant of long-QT syndrome. These patients may have normal QT intervals and therefore resemble CPVT, but they do not usually show ventricular arrhythmias of progressive complexity during graded exercise⁵. There were no ST-T changes or QT interval prolongation preceding pVT runs, as expected in Brugada and long QT syndromes, respectively.

Rare CPVT cases have been reported in middle-aged adult patients. Severe CPVT forms usually die during childhood and people tend to become more sedentary after school graduation, hindering the diagnosis. Autosomal dominant cardiac conditions (possibly but not necessarily our case) show a wide range in severity and age of onset. Clinical presentation within a given kindred may vary widely between family members, which may be explained by genetic (earlier onset with multilocus mutations and double heterozygote) and environmental modifying factors⁶.

The lifetime risk of further episodes of IE among survivors ranges between 2-22%⁷. "Relapse" suggests an incompletely treated episode resulting in emergence of original microorganism from protected sources (prosthetic hardware/intracardiac devices), requiring a search for persistent focus of infection, longer course of treatment or surgical therapy. "Reinfection" concerns infection with a new microorganism. The need for accurate differentiation between relapse/reinfection, preferably using molecular strain-typing methodology, must be reinforced, considering its therapeutic impact. Reinfection with persistent colonizing strain of *S. aureus* could give the erroneous impression of relapse and an episode of IE may be polyclonal although involving a single species, as reported for *Staphylococcus epidermidis*⁸. As polyclonality interferes with antibiotic susceptibility, this observation has important consequences for treatment of device-related coagulase-negative *Staphylococcus* endocarditis (*S. epidermidis*) and suggests the need for exhaustive antibiotic susceptibility testing.

Our patient had both relapsed infection and reinfection. We followed ESC guidelines on IE (prolonged antibiotic treatment, device removal, reimplantation postponed to allow weeks of antibiotic treatment, reimplantation on contralateral side), but severe allergic reactions and intolerance to vancomycin/meropenem were limiting. Potentially persistent/resistant foci of infection attached to the defibrillation lead and the infection polyclonal nature may have had a role as well. Possibility of immunodeficiency and hemorrhagic diathesis (mainly of secondary hemostasis) was considered, as our patient was the offspring of consanguineous first-cousin parents. Presence of hematoma, immunodeficiency and pocket instrumentation/revision increase risk of recurrent pocket infection or device-related IE⁹.

Epicardial defibrillation system implantation was considered. However, placing the coil in the pericardial space may lead to pericarditis, adhesions/fibrosis, infection and arrhythmogenesis and long-term stability/reliability are still unknown¹⁰. Left cardiac sympathetic denervation may be performed in case of syncope recurrence. Wearable cardioverter-defibrillator vests (such as LifeVest) are not yet available in our country.

Potential Conflict of Interest

No potential conflict of interest relevant to this article was reported.

Sources of Funding

There were no external funding sources for this study.

Study Association

This study is not associated with any post-graduation program.

References

1. Leite LR, Ponzi Pereira KR, Alessi SR, de Paola AA. Catecholaminergic polymorphic ventricular tachycardia: an important diagnosis in children with syncope and normal heart. *Arq Bras Cardiol.* 2001;76(1):63-74.
2. Monteforte N, Priori SG. The long QT syndrome and catecholaminergic polymorphic ventricular tachycardia. *Pacing Clin Electrophysiol.* 2009;32(Suppl 2):S52-7.
3. Jóna I, Nánási PP. Cardiomyopathies and sudden cardiac death caused by RyR2 mutations: are the channels the beginning and the end? *Cardiovasc Res.* 2006;71(3):416-8.
4. Yeh DD, Lu JT, Kim A, Yeh RW, Scheinman MM. Calcium-triggered short-coupled polymorphous ventricular tachycardia. *Pacing Clin Electrophysiol.* 2010;33(1):117-22.
5. Schwartz PJ, Priori SG, Spazzolini C, Moss AJ, Vincent GM, Napolitano C, et al. Genotype-phenotype correlation in the long-QT syndrome: gene-specific trigger for life-threatening arrhythmias. *Circulation.* 2001;103(1):89-95.
6. Charron P. Clinical genetics in cardiology. *Heart.* 2006;92(8):1172-6.
7. Mansur AJ, Dal Bo CM, Fukushima JT, Issa VS, Grinberg M, Pomerantzeff PM. Relapses, recurrences, valve replacements, and mortality during the long-term follow-up after infective endocarditis. *Am Heart J.* 2001;141(1):78-86.
8. Van Wijngaerden E, Peetermans WE, Van Lierde S, Van Eldere J. Polyclonal staphylococcus endocarditis. *Clin Infect Dis.* 1997;25(1):69-71.
9. Le KY, Sohail MR, Friedman PA, Uslan DZ, Cha SS, Hayes DL et al. Clinical predictors of cardiovascular implantable electronic device-related infective endocarditis. *Pacing Clin Electrophysiol.* 2011;34(4):450-9.
10. Jacob S, Lieberman RA. Percutaneous epicardial defibrillation coil implantation: a viable technique to manage refractory defibrillation threshold. *Circ Arrhythm Electrophysiol.* 2010;3(2):214-7.