

Tadalafil as Treatment for Idiopathic Pulmonary Arterial Hypertension

Adriana Castro de Carvalho, André Luiz Hovnanian, Caio Julio César dos Santos Fernandes, Mônica Lapa, Carlos Jardim, Rogério Souza

Grupo de Hipertensão Pulmonar – Disciplina de Pneumologia - Instituto do Coração do Hospital das Clínicas - FMUSP - São Paulo, SP - Brazil

Phosphodiesterase inhibitors like sildenafil have already been shown to improve functional capacity and hemodynamics in the treatment of pulmonary arterial hypertension. Few studies address the effects of new phosphodiesterase inhibitors as tadalafil. We report a case of a patient with idiopathic pulmonary arterial hypertension in functional class IV (New York Heart Association - NYHA), with RVSP estimated at 77 mmHg by echocardiogram. The patient had been on espirolactone (25 mg/day), digoxin (25 mg/day) and omeprazol (20 mg/day).

Pulmonary arterial hypertension (PAH) is characterized by the proliferation and vascular remodelling that results in progressive increase of pulmonary vascular resistance with consequent right ventricular dysfunction and eventually death¹. Diagnosis for idiopathic PAH is made after exclusion of other associated factors².

The treatment for PAH has been advancing in recent years. Unfortunately, therapeutic alternatives available still face effectiveness limitations, which are associated to complications and high cost³. The use of the phosphodiesterase-5 (PDE5) inhibitor sildenafil has shown good results, with improvement in hemodynamics and functional capacity in PAH patients. However, many daily administrations are necessary, and dose level stands for high cost³⁻⁵. New PDE5 inhibitors have been approved as treatment for erectile dysfunction, such as tadalafil and vardenafil. A major characteristic of those agents is their half-life, but few studies have addressed their effectiveness and safety for PAH patients^{4,6}. This paper is a report on a PAH patient with clinical and hemodynamic improvement after treatment with tadalafil, a long lasting PDE5 inhibitor.

Case report

A 37-year-old female patient, with progressive dyspnea on exertion for 3 years, was submitted to echocardiogram in early 2003 at another service. The echocardiogram evidenced interatrial communication (IAC) and right ventricle systolic pressure (RVSP) estimated at 47 mmHg. At the time, the patient was submitted to heart surgery for correction of the IAC which was not identified intraoperatively. At the same surgical time the patient was submitted to a pulmonary biopsy which revealed the presence of arteriolar plexiform

lesions compatible with PAH. The patient had a history of alcohol abuse and clinical diagnosis for Child A alcoholic hepatopathy since 1997, without portal hypertension. There was progressive worsening of dyspnea until by September, 2003, when the patient presented functional class IV (New York Heart Association - NYHA), with RVSP estimated at 77 mmHg by echocardiogram. The patient had been on espirolactone (25 mg/day), digoxin (25 mg/day) and omeprazol (20 mg/day).

After searching on the internet for drugs to be used for pulmonary hypertension, the patient started using 10 mg of Tadalafil every 36 hours on her own. The patient came to our service 12 months after she had started empirical treatment. In that period, she reported progressive improvement of her dyspnea condition, having changed to functional class II (NYHA).

Exams were then carried out for effective investigation of pulmonary hypertension, among them: stool samples were negative for parasites; pulmonary function, rheumatogram and thyroid function: normal; abdomen ultrasound: mild hypoechogenicity of hepatic parenchyma, with no signs of portal hypertension. Thoracic CT scan showed only suggestive signs of pulmonary hypertension (Figure 1). A new echocardiogram, after one year of treatment, showed RVSP at 58 mmHg. We decided to withdraw all medication for 72 hours to carry out right heart catheterization and acute test with vasodilator, which showed no significant response to nitric oxide (NO) (Table 1).

We decided to reintroduce tadalafil, at the same dose level, with maintenance of functional class. The 6-minute walk test carried out while on medication resulted 516 meters, starting with 94 bpm heart rate and reaching 141 bpm by test end. Oxygen saturation, measured by pulse oximetry, was of 93% all along the test, without oxygen supplementation.

Discussion

From the most well known pathophysiologic pathways, three are of particular relevance for being the current targets of major therapeutic alternatives available as treatment for PAH: the prostacyclin pathway, the endothelin pathway, and the NO pathway. NO has shown to be a powerful vasodilator

Key words

Pulmonary arterial hypertension, phosphodiesterase inhibitors, sildenafil tadalafil.

Mailing Address: Rogério Souza •

Rua Afonso de Freitas, 556/12 - 04006-052 - São Paulo, SP - Brazil

E-mail: rgrsz@uol.com.br

Manuscript received September 30, 2005; revised manuscript January 3, 2006; accepted January 3, 2006.

Case Report

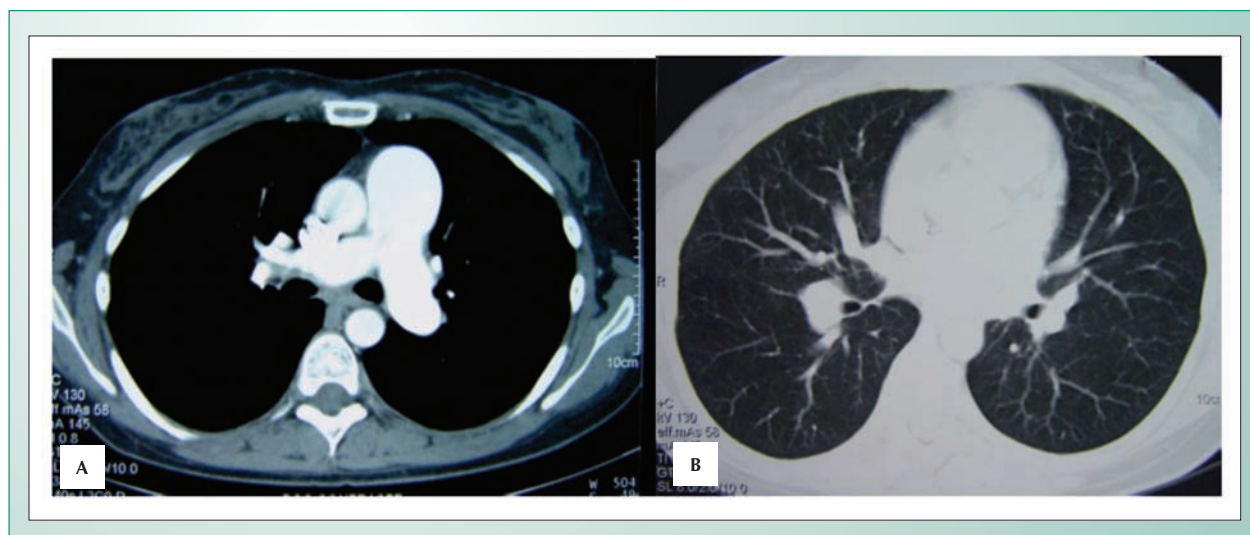


Fig. 1 - CT of thorax with suggestive signs of pulmonary hypertension: A) Mediastinal window at pulmonary artery trunk with increased diameter (>2.9 cm) and increased pulmonary artery and aorta ratio (>1); B) Parenchymal Window showing increased artery/bronchus ratio (>1).

	Baseline	Post nitric oxide
Right atrial pressure (mmHg)	5	5
Mean Pulmonary artery pressure (mmHg)	40	34
Pulmonary vascular resistance (woods)	5.27	4.35
Cardiac index (l/min)	3.61	3.91
Pulmonary wedge pressure (mmHg)	6	5

Table 1 - Hemodynamic data during acute test with vasodilator

and inhibitor of muscular proliferation. NO activates guanylate cyclase, which stimulates the production of cGMP in smooth muscle cells and promotes their relaxation. NO levels may be reduced in PAH⁷.

Phosphodiesterases are a family of enzymes that inactivate cGMP and have different tissue distribution and affinities⁶. PDE5 can be found in quite high volume in pulmonary vasculature. Therefore, its inhibition – which extends cGMP half-life, leading to vasodilation – has been investigated as treatment for PAH⁷.

Sildenafil – a PDE5 selective inhibitor – has proven to be a powerful dose-dependent vasodilator³⁻⁵. Michelakis et al have shown that it is safe to be used for 3 months, and is associated to the improvement of hemodynamics and functional capacities of PAH patients. It is probably a more affordable alternative to current treatments³. Clinical and functional improvement has been shown through the use of sildenafil both for idiopathic PAH as for conditions associated to pulmonary hypertension⁸.

New PDE5 selective inhibitors - vardenafil and tadalafil – with the same action mechanism, although with their

own pharmacokinetic properties, have been launched as treatment for erectile dysfunction, but few studies addressed their use for PAH. Ghofrani et al have compared the hemodynamic effects of vardenafil and tadalafil in the pulmonary and systemic vasculature of PAH patients for 120 minutes. All PDE5 inhibitors caused significant pulmonary vasodilation, but differed in the time for maximal effect and selectivity. Tadalafil showed maximal effect from 75 to 90 minutes (against 40 to 45 for vardenafil and 60 min for sildenafil). Tadalafil and sildenafil reported higher selectivity for pulmonary vasculature (reduction in pulmonary vascular resistance/systemic vascular resistance), and only sildenafil reported improvement of arterial oxygenation⁶.

Palmieri et al have described a PAH case treated with 20 mg of tadalafil every other day. Improvement of functional class (NYHA) and of RVSP in echocardiogram after 6 months of treatment was reported. As for our patient with diagnosis for PAH, non-responsive to NO through right heart catheterization, tadalafil was started at a lower dose (10 mg) every 36 hours on her own account after information collected on lay media. The patient also reported improvement of clinical condition and of functional class, with RVSP reduction – from 77 to 58 mmHg on echocardiogram. The patient has been on medication for over a year. As improvement was evident and no adverse effects were reported, the same dose level was kept. Furthermore, the distance of the six-minute walk test is indicative of good prognosis at long term after treatment is established¹⁰.

The use of new PDE5 inhibitors as tadalafil may be an alternative to treat PAH, and may sponsor higher compliance to treatment since half-life is longer, with one single administration everyday or every other day. Further pharmacodynamic studies are necessary specifically for PAH patients to find out whether the dose-response component is present or not, to then define the ideal dose level for such condition.

References

1. Rubin LJ. Primary pulmonary hypertension. *Chest*. 1993; 104: 236-50.
2. Simonneau G, Galiè N, Rubin LJ, Langleben D, Seeger W, Domenighetti G, et al. Clinical classification of pulmonary hypertension. *J Am Coll Cardiol*. 2004; 43: 5S- 12S.
3. Michelakis ED, Tymchak W, Noga M, Webster L, Wu XC, Lien D, et al. Long-term treatment with oral sildenafil is safe and improves functional capacity and hemodynamics in patients with pulmonary arterial hypertension. *Circulation*. 2003; 108: 2066-9.
4. Wilkens H, Guth A, König J, Forestier N, Cremers B, Hennen B, et al. Effect of inhaled iloprost plus oral sildenafil in patients with primary pulmonary hypertension. *Circulation*. 2001; 104: 1218-22.
5. Michelakis ED, Tymchak W, Lien D, Webster L, Hashimoto K, Archer S. Oral sildenafil is an effective and specific pulmonary vasodilator in patients with pulmonary arterial hypertension: comparison with inhaled nitric oxide. *Circulation*. 2002; 105: 2398-403.
6. Ghofrani HA, Voswinckel R, Reichenberger F, Olschewski H, Haredza P, Karadas B, et al. Differences in hemodynamic and oxygenation responses to three different phosphodiesterase-5 inhibitors in patients with pulmonary arterial hypertension. *J Am Coll Cardiol*. 2004; 44: 1488-96.
7. Humbert M, Sitbon O, Simonneau G. Treatment of pulmonary arterial hypertension. *N Engl Med*. 2004; 351(14): 1425-36.
8. Fernandes CJC, Jardim C, Carvalho LA, Farias AQ, Terra-Filho M, Souza R. Clinical response to sildenafil in pulmonary hypertension associated to Gaucher's disease. *J Inherit Metab Dis*. 2005; 28(4): 603-5
9. Palmieri EA, Lembo D, Affuso F, Fazio S. Tadalafil in primary pulmonary arterial hypertension. *Ann Intern Med*. 2004; 141(9): 743-4.
10. Sitbon O, Humbert M, Nunes H, Parent F, Garcia G, Herve PG, et al. Long-term intravenous epoprostenol infusion in primary pulmonary hypertension: prognostic factors and survival. *J Am Coll Cardiol*. 2002; 40(4): 780-8.