

Immunocompromised Patient with Multiple Cardiac Masses

Amelia Carro, Lourdes Pérez, Maria Mutuberría, Teresa Gonzalez-Alujas

Hospital Universitario Valle de Hebron, Barcelona - Spain

A 57-year-old-man presented with a 4-day history of general weakness, cough with blood-stained sputum, pleuritic chest pain and fever (38.5°C). His medical history revealed a left-superior pulmonary lobectomy (due to an in situ carcinoma) six years before, and a recently developed myelodysplastic syndrome during current chemotherapy. On admission, he showed bicytopenia and right-sided pneumothorax (Figure 1A). Expanded microbiological studies demonstrated *Aspergillus fumigatus* growth on tracheal aspirate and two positive determinations of serum galactomannan antigen. A computed tomography scan confirmed the diagnosis of pulmonary aspergillosis (Figure 1B); antifungal treatment was administered (voriconazole, amphotericin B). The clinical course steadily worsened, with multiple cutaneous petechiae, intense headache, visual disturbances and other signs suggestive of a neurologic process. Cerebrospinal fluid was positive for galactomannan antigen, and a cranial magnetic resonance imaging (MRI) diagnosed multiple cerebral infarcts and endophthalmitis (Figure 1C). Transthoracic (Figure 1D) and transesophageal (Figure 1E) echocardiograms were performed in search of an embolic source, revealing the presence of a large left atrial mass, as well as several smaller ones attached to other cardiac structures (Figures D, E, F; arrows), highly suggestive of vegetations. Cardiac MRI showed similar findings (Figure 1F), with no late gadolinium enhancement on conventional or phase-sensitive inversion recovery sequences. With all these imaging features, cardiac masses were interpreted as vegetations, although, without histological confirmation, there is a possibility that they

might correspond to thrombi. The patient met the criteria for invasive pulmonary aspergillosis with endocarditis and septic embolisms, an infrequent form of the disease. It is remarkable the strikingly unusual size and location of the vegetations, the absence of valvular or ventricular dysfunction, and the aggressive clinical course that finally led to the patient's death.

Author contributions

Conception and design of the research, Analysis and interpretation of the data: Carro A, Gonzalez-Alujas T; Acquisition of data: Carro A, Pérez L; Writing of the manuscript: Carro A; Critical revision of the manuscript for intellectual content: Carro A, Pérez L, Mutuberría M, Gonzalez-Alujas T.

Potential Conflict of Interest

No potential conflict of interest relevant to this article was reported.

Sources of Funding

There were no external funding sources for this study.

Study Association

This study is not associated with any post-graduation program.

Keywords

Lung Neoplasms; Pneumonectomy; *Aspergillus fumigatus*; Endocarditis, Bacterial; Embolism.

Mailing Address: Amelia Carro •

Servei de Cardiologia. Hospital Vall d'Hebron. Pº Vall d'Hebron119, Postal Code 08035, Barcelona – Spain

E-mail: achevia@gmail.com, amelia.carro@vhir.org

Manuscript received June 26, 2012, revised manuscript December 24, 2012, accepted January 02, 2013.

DOI: 10.5935/abc.20130083

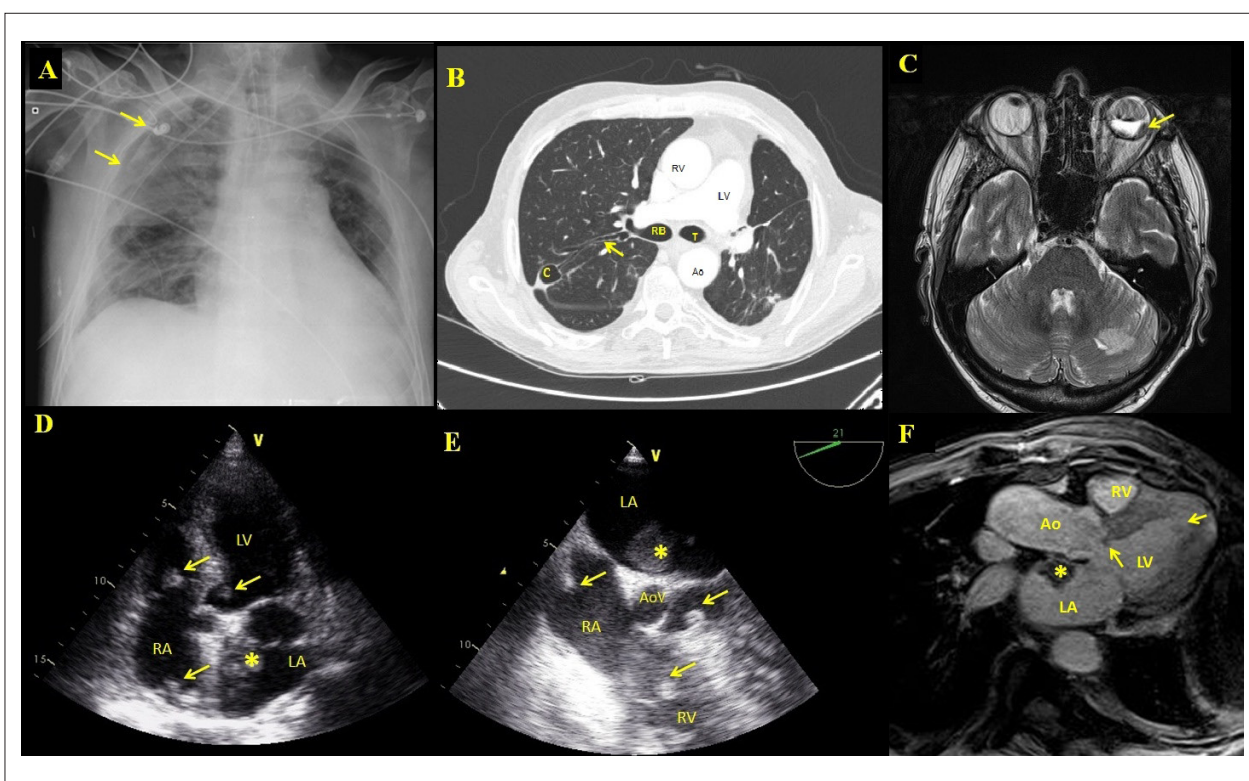


Figure 1 – A Chest radiograph on admission showed right sided pneumothorax, evidenced by the presence of the visceral pleural white line (arrows). Left pulmonary field is atelectatic due to the previous lobectomy. B: Thoracic computer tomography showing an air-filled cavity (C) (12x20mm) in the posterior segment of the right upper pulmonary lobe that communicates with the adjacent bronchus (arrow). C: Cranial magnetic resonance showing hyperintense T1 signal in the posterior part of left eyeball (arrow), indicating fatty infiltration related to inflammatory process (endophthalmitis). D: Longitudinal five-chamber view on transthoracic echocardiogram, highlighting the presence of a heterogeneous left atrial mass (*), with no clear point of attachment to the interatrial septum. Smaller masses were also found in the left ventricular outflow tract, tricuspid valve and right atrium (arrows). E: Longitudinal five-chamber view on transesophageal echocardiogram, highlighting the presence of a heterogeneous left atrial mass (*), with no clear point of attachment to the interatrial septum. Smaller masses were also found in the left ventricular outflow tract, tricuspid valve and right atrium (arrows). F: Longitudinal three-chamber view of a cine sequence of cardiac resonance, highlighting the presence of an isointense left atrial mass (*). Smaller masses were also found in the left ventricular outflow tract and left ventricle (arrows). RV: right ventricle; LV: left ventricle; RB: right bronchus; Ao: aorta; T: trachea; LA: left atrium; RA: right atrium; RV: right ventricle; AoV: aortic Valve.