

## Technical difficulty in Stenting Supralimus in Radial Artery Graft

George César Ximenes Meireles, Sergio Kreimer, Micheli Zanotti Galon, Gilberto Guilherme Ajar Marchiori  
Iamspe - Hospital do Servidor Público Estadual de São Paulo, São Paulo, SP - Brazil

Woman, 67 years old, with unstable angina and history of myocardial revascularization: left internal thoracic artery to anterior descending artery and graft with radial artery (RA) to right coronary artery branches. Coronariography showed stenosis of 90% in the RA graft, treated with conventional stent. After two months, the patient developed unstable angina related to in-stent restenosis, treated with sirolimus-eluting stent. In the follow-up, six months after implantation, the patient was asymptomatic and maintaining the outcome of the implant. This case report demonstrates the technical difficulties of percutaneous intervention in RA grafts and treatment outcome of in-stent restenosis with sirolimus stent.

### Introduction

The use of internal thoracic artery (ITA) as a graft in myocardial revascularization surgery (MRS) is associated with reduced mortality in the long term<sup>1</sup>, which led to increased interest in other arterial grafts (gastroepiploic, epigastric, and radial). Of these, the use of radial artery (RA) became more popular after the development of the technique and the prevention of spasm, which made possible the MRS with two grafts using sequential grafting with the left ITA anastomosed to anterior descending artery (ADA) and one or more RA grafts, anastomosed proximally to the left ITA and distally to the branches of the circumflex artery (CXA) or right coronary artery (RCA)<sup>2</sup>. The arterial grafts can develop stenosis and were treated by percutaneous coronary intervention (PCI). In this case report, we describe the difficulties in PCI for the treatment of stenosis in the graft of RA.

### Case report

It is a woman, 67 years old, with unstable angina and a history of hypertension and diabetes mellitus, who underwent MRS in 1996: left latero-lateral ITA anastomosis to the ADA

### Keywords

Stents/adverse effects; drug-eluting stents; graft occlusion, vascular; sirolimus.

and 1<sup>st</sup> diagonal branch (Dg1) and sequential Y-grafting with RA to the posterior ventricular branch (PVB) of RCA. Coronariography showed the ITA anastomosis with the ADA occluded; anastomosis with Dg1 without obstructions, the RA graft to the branch PVB with stenosis of 90% on the middle third (Figure 1A and B) ADA and RCA with stenoses with 70% and 100%, respectively, with collateral circulation of the ADA to the ADA 3 + / 4 +. Ventriculography showed extensive left ventricular hypertrophic aspect. Stent implant was indicated for the treatment of stenosis in the graft of RA. The approach was the right femoral artery (RFA), and mammary 6F guiding catheter was used (Medtronic-AVE, USA) and guide wire Galeo floppy 0.014" (Biotronik, Switzerland). The left ITA showed severe tortuosity in the middle third and, after passage of the guide wire, showed corkscrew-like appearance (Figure 1C). It was performed predilatation of the lesion with a balloon catheter Elect 2.5 x 10 mm (Biotronik). The control angiography showed intense spasm in the grafts of RA and the ITA (Figure 1D). Monitrato-5 of isosorbide 20 mg (MN5IS) was given by the guide catheter, with improvement of spasm, followed by stent implantation PRO-Kinetic 2.75 x 13 mm (Biotronik) with 12 atm. Angiographic control after implantation, the spasm persisted and the patient was again treated with MN5IS without success, followed by administration of 200 mcg nitroglycerin (NG), allowing visualization of the vessel. It was observed, then angiographic appearance of proximal dissection to the stent (Figure 1E), treated by implantation of another stent PRO-Kinetic 2.75x13mm, released at 12 atm. It was performed post-stent dilatation with balloon of the stent to 14 atm. The control angiography showed adequate expansion of stents, TIMI III flow (Figure 1F), with complete resolution of spasm in arterial grafts, observed only after removal of the guide wire. The patient recovered without complications.

After two months, she had chest pain at rest without ECG changes, troponin and CK-MB mass. New coronariography was performed, which revealed in-stent restenosis diffuse pattern, with stenosis of 95% in the RA graft (Figure 2A and B). New PCI was performed in the same procedure via AFD, and we used the same type of guide catheter and guide wire Extra support Choice PT 0.014" (Boston Scientific Inc., USA) introduced via the left ITA to the branch PVB, followed by catheter-balloon Elect 2.5 x 15 mm for pre-dilation. Again she presented severe spasm of the grafts being medicated with MN5IS by the guide catheter, with slight improvement, making it difficult to position the stent Supralimus 3.0 x 29 mm (Sahajanad Medical Technologies, India) (Figure 2C), aided by the image of the previously implanted stents (Figure 2D) and released with 14 atm. Only after the withdrawal of the guide wire and medication MN5IS, it was possible to

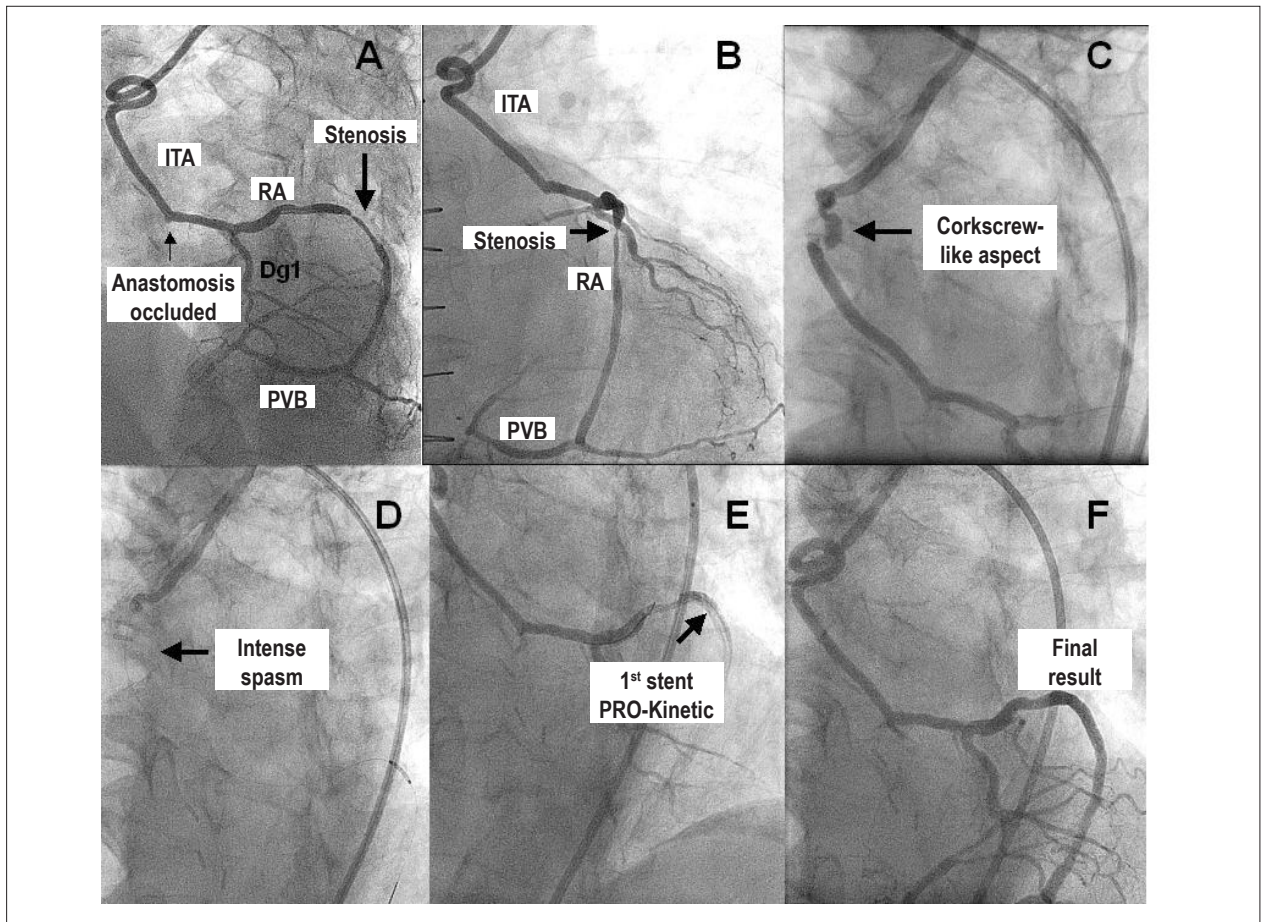
**Mailing address: George César Ximenes Meireles •**

Rua Sena Madureira, 1265/102 - Vila Clementino - 04021-051

São Paulo, SP - Brazil

E-mail: gcxm@cardiol.br, george.ximenes@terra.com.br

Manuscript received July 08, 2009; revised manuscript received March 07, 2010; accepted April 26, 2010.



**Fig. 1** - A and B - Coronariography in left and right anterior oblique view, demonstrating the stenosis in the radial artery graft and anastomosis for occluded ADA (arrows). C - Corkscrew-like aspect in internal thoracic artery (arrow). D - Intense spasm in internal thoracic artery (arrow). E - Result after the implant of the 1<sup>st</sup> stent PRO-Kinetic (arrow). F - Final result after graft of two PRO-Kinetic stents (arrow).

observe the end result, which showed the stent with adequate angiographic aspect (Figure 2E). The patient recovered without complications. Angiographic and clinical follow-up six months post-implant, she was asymptomatic and maintaining the result of drug-eluting stent implantation (Figure 2F).

## Discussion

Unlike ITA, which has a low incidence of atherosclerosis, the RA is more frequently affected by atherosclerosis, making it unusable as a vascular graft in 5% of patients undergoing MRS. In the presence of diabetes mellitus, approximately 50% of patients presented atherosclerosis RA<sup>3</sup>.

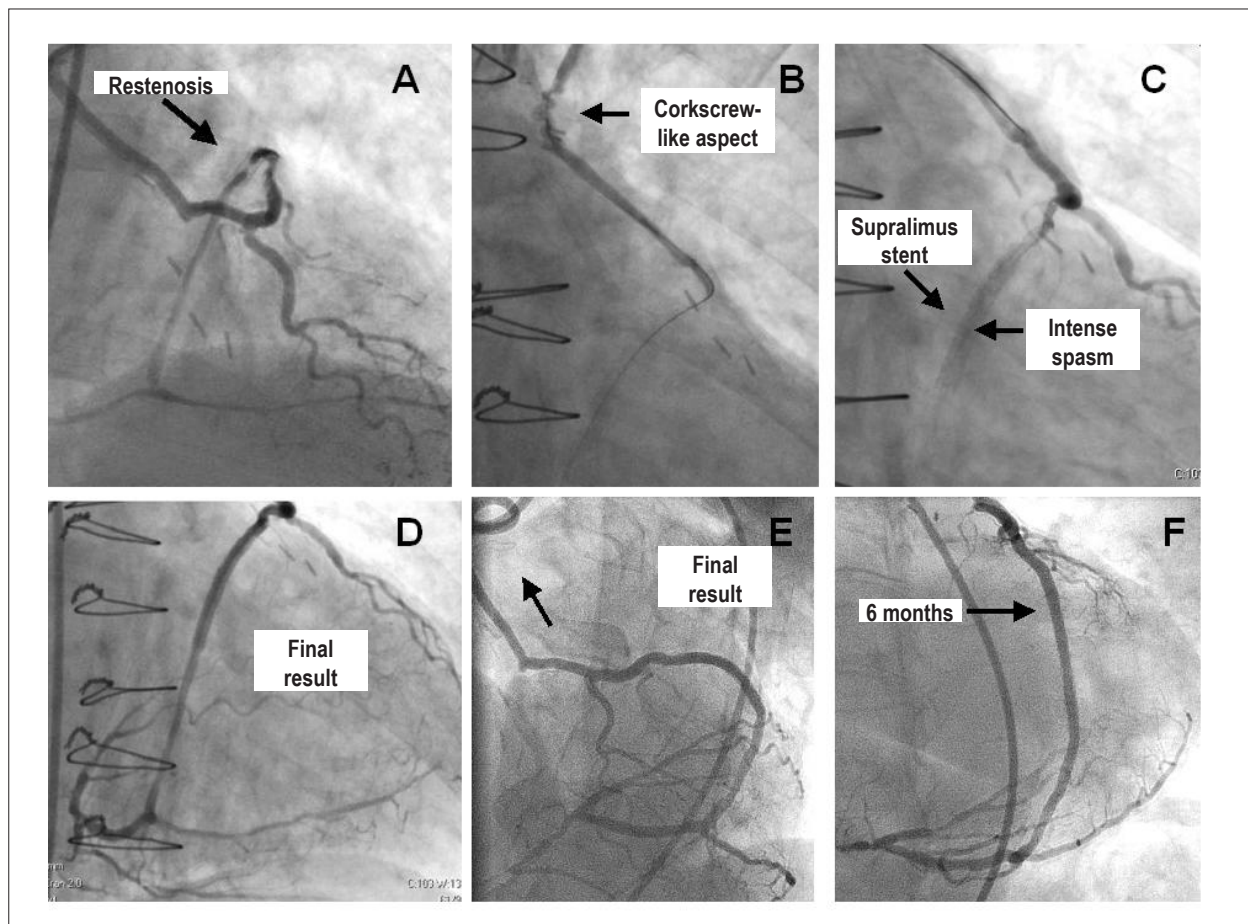
The patency rate at five years post-grafting of RA is between 83% to 91%<sup>4</sup>, and the exact mechanism for these high rates of graft failure is unknown. Many hypotheses have been proposed to explain the presence of stenosis in grafts of RA: vasospasm, competitive flow from native circulation, neointimal hyperplasia, endothelial lesion during manipulation of the graft or technical problems during surgery<sup>5</sup>. In a large series of percutaneous interventions in radial grafts, it was

found that two thirds of cases of stenosis occurred proximal or distal anastomosis, suggesting that the main cause of stenosis in these patients is related to technical difficulties<sup>6</sup>. In this case, the stenosis is probably related to neointimal hyperplasia, based on location in the middle third of the graft and the time span of 12 years between surgery and onset of symptoms.

Since the first reports of graft coronary intervention in RA graft, we found that these arteries are potentially spastic, and the procedure may be performed with the liberal use of vasodilators drugs<sup>7</sup>. Histologically, the RA differs from ITA for the greatest thickness of the medium layer, with myocytes arranged in denser layers with little connective tissue, while the ITA average has irregular organization of the myocytes with loose structure of connective tissue and elastic fibers. The density and better organization of smooth muscle cells of RA can generate more power than the ITA, increasing the propensity for spasm<sup>2</sup>.

The difficulties that occurred in this case were related to spasms of the grafts. The radial arteries of women are more sensitive to vasoconstrictors, are less sensitive to vasodilators and have a diameter smaller than the men<sup>2,8</sup>. The appearance

## Case Report



**Fig. 2** - A and B - Coronariography in left and right anterior oblique view, demonstrating the restenosis in the radial artery graft (arrows). C - Corkscrew-like aspect in the internal thoracic artery (arrow). D - Intense spasm after the Supralimus stent graft (arrow). E - Final result of post-implant in left and right anterior oblique view (arrows). F - Result of six months after graft in right anterior oblique (arrow).

of corkscrew observed in ITA, after the passage of the guide wire, was due to stretch of artery, which had severe tortuosity in the middle segment and has been described as a hallmark of coronary spasm. The second procedure was characterized by greater spasm of the grafts, probably due to the use of more rigid guide wire is necessary to support the passage of the stent over a tortuous path.

Arterial spasm may occur by mechanical stimulation, nerve stimulation and the action of vasoconstrictor substances. For the pharmacological treatment of arterial spasm, nitrates are used (NG and MN51S) and the spasms are resistant to these drugs, the calcium channel blockers (diltiazem and verapamil)<sup>7</sup>. In the current report, were used for treatment of spasm only nitrates in high doses, since we believed that the main cause of the spasm was secondary to the passage of the guide wire on ITA with severe tortuosity, reinforced by the observation that the complete resolution of spasm occurred only after withdrawal of the guide wire.

The drug-eluting stents used in this case, the Supralimus, Sirolimus-eluting, has shown efficacy in treating in-stent restenosis, with the maintenance of the outcome at six months post-implant. The only case report of drug stents to treat stenosis

in RA was related to the new aorta ostial lesions, and eluting stent of paclitaxel<sup>9</sup> was used. The Sirolimus-eluting stents compared with paclitaxel in treatment of in-stent restenosis, showed lower rate of target lesion revascularization and late loss<sup>10</sup>.

This case illustrates the first report of implantation of sirolimus-eluting stent for treatment of in-stent restenosis in the RA graft, demonstrating the technical difficulties of PCI in these grafts, related to severe spasm and excellent angiographic result immediately and six months post-implant.

### Potential Conflict of Interest

No potential conflict of interest relevant to this article was reported.

### Sources of Funding

There were no external funding sources for this study.

### Study Association

This study is not associated with any post-graduation program.

## References

1. Cameron A, Davis KB, Green G, Schaff HV. Coronary artery bypass surgery with internal-thoracic-artery grafts: effects on survival over a 15-year period. *N Engl J Med.* 1996; 334 (4): 216-9.
2. Acar C, Jebara VA, Portoghese M, Beyssen B, Pagny JY, Grare P, et al. Revival of the radial artery for coronary artery bypass grafting. *Ann Thorac Surg.* 1992; 54 (4): 652-9.
3. Nicolosi AC, Pohl LL, Parsons P, Cambria RA, Olinger GN. Increased incidence of radial artery calcification in patients with diabetes mellitus. *J Surg Res.* 2002; 102 (1): 1-5.
4. Acar C, Ramsheyi A, Pagny JY, Jebara V, Barrier P, Fabiani JN, et al. The radial artery for coronary artery bypass grafting: clinical and angiographic results at five years. *J Thorac Cardiovasc Surg.* 1998; 116 (6): 981-9.
5. Curtis JJ, Stoney WS, Alford WC Jr, Burrus GR, Thomas CS Jr. Intimal hyperplasia: a cause of radial artery aortocoronary bypass graft failure. *Ann Thorac Surg.* 1975; 20 (6): 628-35.
6. Sharma A, Ajani A, Garg N, GebreEyesus A, Varghese J, Pinnow E, et al. Percutaneous interventions in radial artery grafts: clinical and angiographic outcomes. *Catheter Cardiovasc Interv.* 2003; 59 (2): 172-5.
7. Kulkarni NM, Thomas MR. Severe spasm of a radial artery coronary bypass graft during coronary intervention. *Catheter Cardiovasc Interv.* 1999; 47 (3): 331-5.
8. Mong K, Duggan JA, Tabrizchi R. Comparative study of functional responses and morphometric state of distal arteries in male and female. *Ann Thorac Surg.* 2002; 74 (6): 2126-31.
9. McKay E, Ramsdale KA, Ramsdale DR. Drug-eluting stent implantation for radial artery graft aorta-ostial stenosis. *N Z Med J.* 2008; 121 (1273): 66-8.
10. Kastrati A, Mehilli J, von Beckerath N, Dibra A, Hausleiter J, Pache J, et al. Sirolimus-eluting stent or paclitaxel-eluting stent vs balloon angioplasty for prevention of recurrences in patients with coronary in-stent restenosis. *JAMA.* 2005; 293: 165-71.