

Coronary Spasm Induced by Dobutamine-Atropine Stress Echocardiography

Fábio A. Bogaz, Ally N. R. Saroute, Jeane Mike Tsutsui, Ingrid Kowatsch, Francisco M. O. Neto, José C. Nicolau, José A. F. Ramires, Wilson Mathias Junior

Instituto do Coração (InCor) - Hospital das Clínicas da FMUSP - São Paulo, SP, Brazil

This is the report on a 45-year-old female, with a history of systemic arterial hypertension and cigarette smoking, submitted to dobutamine-atropine stress echocardiography for the investigation of coronary artery disease. At stress peak, the patient reported sudden, highly intense precordial pain. The 12-lead electrocardiogram showed ST segment elevation in DII, DIII, aVF, V5 and V6, and depression in DI, aVL, V2 and V3. Echocardiographic imaging monitoring showed dyskinesia of inferior septum and akinesia of inferior wall. The test was interrupted immediately. The patient was medicated and improved her precordial pain condition as well as wall motion abnormalities. Coronary angiography showed irregular coronary lesions with <50% luminal diameter obstruction. It is a case of coronary spasm induced by alpha-adrenergic stimulation during dobutamine-atropine stress echocardiography.

Dobutamine stress echocardiography (DSE) is a widely used method for the evaluation of patients with known or suspected coronary artery disease. DSE safety profile has been established by studies involving large numbers of patients^{1,2}. Dobutamine is a well-tolerated catecholamine, with half-life of 2 to 3 minutes. Due to its positive inotropic and chronotropic effects, it increases myocardial oxygen consumption. The evaluation of myocardial ischemia is based on the detection of decreased myocardial systolic thickening by two-dimensional echocardiography. These wall motion abnormalities are induced by an unbalance between oxygen offer and demand during stress. The presence of ST segment elevation in 12-lead electrocardiogram (ECG), in association with transitory wall motion abnormalities, is an uncommon finding during DSE, and generally indicates severe coronary obstruction. However, it is already known that the increase in arterial shear stress during DSE may lead to coronary spasm even in patients with no significant coronary obstruction.

Case Report

This is the report on a 45-year-old female, with a history of systemic arterial hypertension and cigarette smoking, submitted to dobutamine-atropine DSE for the investigation of coronary artery disease. The patient reported one episode of unstable angina that had occurred two years before. At that time, the patient was submitted to myocardial perfusion scintigraphy which showed myocardial perfusion abnormalities in the inferior and lateral walls of the left ventricle, suggestive of ischemia. Coronary angiography showed coronary artery irregularities. Normal left ventricular systolic function was observed at ventriculography. A year after this initial episode of angina, the patient underwent a new myocardial perfusion scintigraphy that revealed normal perfusion.

Twenty days later the patient reported new episodes of chest pain irradiating to right upper limb, not associated with physical strain. Chest pain occurred in the morning, and improved after the use of sublingual nitrate. The patient went to the outpatient unit for assistance. She was administered medication for coronary artery disease (acetylsalicylic acid and betablocker) and was referred for pharmacologic stress echocardiography to investigate the angina condition. The patient was free of chest pain in the 48 hours preceding the stress test.

The baseline 12-lead ECG did not show any abnormality (Fig. 1A) and the echocardiogram at rest showed normal sized cardiac cavities, normal global systolic function and no abnormalities in segmental wall motion. Aortic valve was thickened, with mild dysfunction. Dobutamine-atropine stress echocardiography was carried out following institutional protocol. Intravenous dobutamine infusion was started at 5 $\mu\text{g}/\text{kg}/\text{min}$ dose and increased to 10, 20 and 30 $\mu\text{g}/\text{kg}/\text{min}$ every three minutes. Atropine was started at 20 $\mu\text{g}/\text{kg}/\text{min}$ (0.25 mg every minute). At 30 $\mu\text{g}/\text{kg}/\text{min}$ of dobutamine and 1.25 mg de atropine, the patient presented sudden, highly intense chest pain. At this time, heart rate reached 159 beats per minute (91% of maximum heart rate, calculated as 220

Key words

Stress echocardiography, coronary spasm, coronary artery disease, dobutamine.

Mailing Address: Jeane Mike Tsutsui •

Rua Harmonia, 539/74B 05435-000 – São Paulo, SP

E-mail: jeane.tsutsui@incor.usp.br

Manuscript received November 27, 2005; revised manuscript received December 8, 2005; accepted on December 8, 2005.

Case Report

– age in years) and blood pressure was 120 x 70 mmHg. ST segment showed elevation in DII, DIII, aVF, V5 and V6, and depression in DI, aVL, V2 and V3 (Fig. 1B). Echocardiogram showed akinesia of inferior wall and basal segment of the anterior septum; and dyskinesia of mid and basal segments of inferior septum (Fig. 2). The patient presented premature ventricular complexes, bigeminism, and periods of non-sustained ventricular tachycardia. The dobutamine infusion was interrupted. Intravenous metoprolol (15 mg) was administered slowly, as well as 5 mg of nitrate sublingually. After medication, the chest pain disappeared, but elevation of ST segment was maintained for ten minutes. There was return of ST segment to baseline levels only twenty minutes after stress interruption (Fig. 1C). Left ventricular wall motion abnormalities were kept for another thirty minutes, and the patient was transferred to the intensive care coronary unit. Cardiac troponin I dosages were 3.3 ng/ml and < 0.7 ng/ml, after eight and fourteen hours of chest pain, respectively (normal value at our institution is < 2.0 ng/ml). Creatine-kinase mB fraction (mass) values were 2.4 ng/ml and < 0.7 ng/ml, respectively (normal value < 4.0 ng/ml).

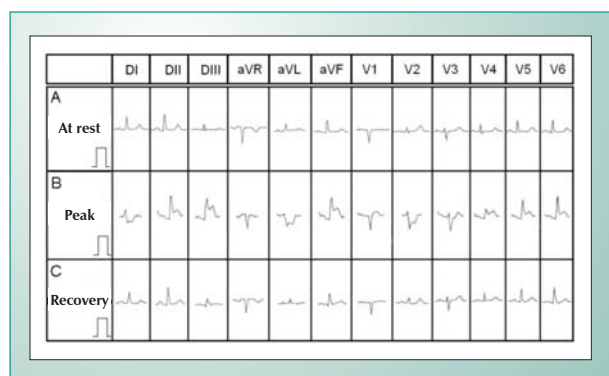


Fig. 1 - Twelve-lead electrocardiogram showing the absence of abnormalities at rest (A) and ST segment elevation during dobutamine-atropine peak stress. (B) ST segment returned to baseline levels twenty minutes after the interruption of dobutamine and administration of intravenous metoprolol and sublingual nitrate.

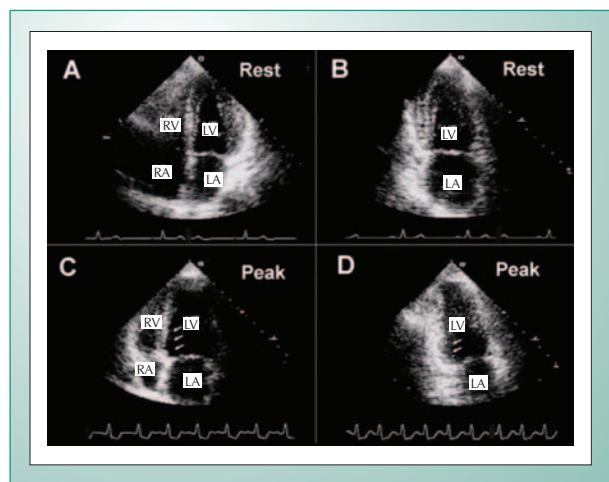


Fig. 2 - Echocardiographic images in the apical four-chamber (A) and two-chamber views (B) at rest, showing normal wall motion in all myocardial segments. At dobutamine-atropine peak stress, it was observed dyskinesia in the mid and basal segments of inferior septum (C, arrows) and akinesia of inferior wall (D, arrows).

On the following day, the patient was submitted to coronary angiography that showed irregularities in left anterior descending coronary artery, right coronary artery, and left circumflex. The first marginal branch of the left circumflex showed < 50% ostial lesion (Fig. 3). Two days after the stress test a transthoracic echocardiogram showed normal left ventricular global and segmental function. Betablocker therapy was interrupted, and calcium channel blocker and nitrate were introduced orally. The patient had satisfactory clinical course and was discharged from hospital with no other events.

Discussion

Left ventricular wall motion abnormalities during DSE may occur with no electrocardiographic abnormalities. Or rather, and more commonly, may be associated with ST segment depression. ST segment elevation during DSE is an uncommon electrocardiographic abnormality, and most times is explained by a coronary spasm phenomenon. This is a major explanation for pseudo-positive DSE results³. Test interruption, associated to the use of proper drugs, helps preventing myocardial infarction, that is a rare complication that may occur after DSE⁴.

In the conventional ergometric test, ST segment elevation may occur in patients with previous myocardial infarction, due to the dyskynetic motion of infarcted wall, or in patients with severe coronary lesions.

Cohen et al⁵ were the first to report coronary spasm induction during DSE. The authors described the case of a 48-year-old male who showed ST segment elevation in the infero-lateral leads and dyskynetic motion in the inferior wall at 40 $\mu\text{g}/\text{kg}/\text{min}$ of dobutamine and 0.25mg of atropine. Subsequent coronary angiography revealed no significant obstructive lesions. Deligonul et al⁶ have reported the case of a 35-year-old male with no previous history of infarction and mild coronary lesions at angiography. The patient presented chest pain at the end of the 40 $\mu\text{g}/\text{kg}/\text{min}$ of dobutamine, and ST segment elevation. Segmental wall motion analysis at the moment of chest pain was jeopardized by patient's unquietness.

Shaheen et al⁷ have described a similar case – a 48-year-old male with ST segment elevation at ECG, associated to chest pain, and followed by ventricular fibrillation during DSE. Dobutamine-induced coronary spasm was also confirmed by coronary angiography. Yamagishi et al⁸ have reported the case of a female patient with ST segment elevation during the stage of 20 $\mu\text{g}/\text{kg}/\text{min}$ of dobutamine infusion, associated to chest pain. Angiography confirmed the absence of obstructive lesions and documented total occlusion of distal branch of the left circumflex artery as a result of coronary spasm.

Abnormal vasoconstricting response in small and mid-sized arteries occurs in the presence of atherosclerosis and may be related to endothelial dysfunction⁹. The dobutamine pharmacodynamic action in the coronary arteries is primarily vasodilation, which occurs because of β_2 -adrenergic receptors stimulation in the presence of normofunctioning vascular endothelium.

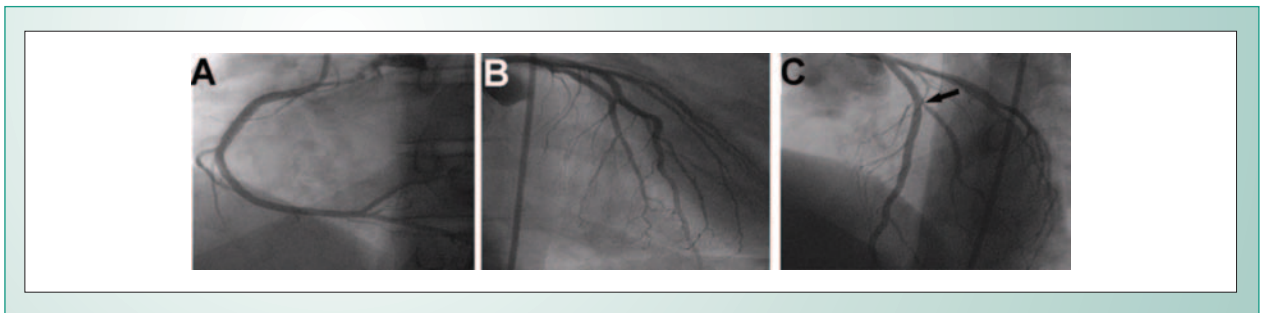


Fig. 3 - Coronary angiographic images showing coronary arteries with irregularities (A and B) and < 50% luminal obstruction lesion in the first marginal branch of the left circumflex artery (C, arrow).

Gordon et al⁹ have demonstrated that coronary artery segments with parietal irregularities respond to exercise and to acetylcholine with spasm, thus indicating local endothelium dysfunction.

The case described here is an example of a patient who had coronary arteries irregularities at coronary angiography. These abnormalities indicate atherosclerotic process which was complicated by spasm induced by the adrenergic stimulation during DSE. It is extremely relevant to point out the sudden onset of the angina, ST segment elevation, and of the wall motion abnormalities as peculiar to the spasm phenomenon. In patients with significant coronary artery disease, electrocardiographic and echocardiographic abnormalities result from reduced coronary reserve. These abnormalities arise gradually, and may even occur at low doses of dobutamine and worsen as myocardial oxygen consumption increases. In the case described the patient had no significant coronary artery stenosis; neither did she

have previous history of myocardial infarction. Therefore, the electrocardiographic event as well as left ventricular wall motion abnormalities may be explained by a coronary spasm phenomenon.

Conclusion

Although DSE is a safe method to evaluate patients with suspected or known coronary artery disease, patients with minimally obstructive lesions may present coronary spasm during DSE as a result of alpha-adrenergic stimulation, resulting in chest pain and significant electrocardiographic abnormalities.

Potential Conflict of Interest

No potential conflict of interest relevant to this article was reported.

References

- Picano E, Mathias Jr W, Pingitore A, Bigi R, Previtali M. Safety and tolerability of dobutamine-atropine stress echocardiography: a prospective, multicentre study. *Echo Dobutamine International Cooperative Study Group. Lancet.* 1994; 344: 1190-2.
- Mathias Jr W, Arruda A, Santos FC, et al. Safety of dobutamine-atropine stress echocardiography: A prospective experience of 4,033 consecutive studies. *J Am Soc Echocardiogr.* 1999; 12: 785-91.
- Varga A, Cortigiani L, Rossi PC, et al. Coronary vasospasm as a source of false positive results during dobutamine echocardiography. *Cardiologia.* 1999; 44: 907-12.
- Elhendy A, Ginete W, Shurmur S, Porter TR. Acute myocardial infarction after a negative dobutamine stress echocardiogram. *Eur J Echocardiogr.* 2004; 5: 469-71.
- Cohen A, Chauvel C, Benhalima B, Blanchard B. Complication of dobutamine stress echocardiography. *Lancet.* 1995; 345: 201-2.
- Deligonul U, Armbruster R, Hailu A. Provocation of coronary spasm by dobutamine stress echocardiography in a patient with angiographically minimal coronary artery disease. *Clin Cardiol.* 1996; 19: 755-8.
- Shaheen J, Mendzelevski B, Tzivoni D. Dobutamine-induced ST segment elevation and ventricular fibrillation with nonsignificant coronary artery disease. *Am Heart J.* 1996; 132: 1058-60.
- Yamagishi H, Watanabe H, Toda I, et al. A case of dobutamine-induced coronary arterial spasm with ST-segment elevation. *Jpn Circ J.* 1998; 62: 150-1.
- Gordon JB, Ganz P, Nabel EG, et al. Atherosclerosis influences the vasomotor response of epicardial coronary arteries to exercise. *J Clin Invest.* 1989; 83: 1946-52.