

Vascular Color Doppler Ultrasound for Assessing Renovascular Hypertension. Accuracy of the Direct Technique for Assessing the Renal Arteries

Carlos Alberto Engelhorn, Ana Luiza Engelhorn, Renata Pullig
Curitiba, PR - Brazil

Objective

To assess the accuracy of vascular color Doppler ultrasound as compared with digital subtraction arteriography for identifying hemodynamically significant renal artery stenoses.

Methods

One hundred and thirty-seven renal arteries from 69 adult patients suspected of having renovascular arterial hypertension were prospectively studied with ultrasound. The results obtained were compared in a double-blind manner with those obtained on digital subtraction arteriography, and the following parameters were calculated according to previously defined criteria: sensitivity, specificity, positive predictive value, negative predictive value, and overall accuracy.

Results

The inconclusive results (7 arteries) were excluded. The comparison of the 2 methods in regard to the 130 remaining arteries showed concordant results for 116 (89.2%) arteries and discordant results for 14 (10.8%) arteries. The sensitivity, specificity, positive predictive value, negative predictive value, and overall accuracy of vascular color Doppler ultrasound were, respectively, 95.33%, 88.14%, 89.86%, 94.55%, and 91.94%.

Conclusion

A good correlation between the 2 examinations was observed in the evaluation of the hemodynamically significant renal artery stenoses, making vascular color Doppler ultrasound a noninvasive method useful for selecting patients with suspected renovascular hypertension.

Key words:

hypertension, renal artery, ultrasound

The early diagnosis of patients suspected of having renovascular hypertension is important because of the risk of progression to renal insufficiency due to the nephropathic ischemia caused by lesions limiting the renal artery flow.

The diagnosis of arterial hypertension resulting from renal artery stenosis may be established with the following different complementary examinations: determination of selective renin in the renal vein; functional study with radioisotopes; excretory urography; determination of the peripheral renin stimulated with captopril; magnetic angioresonance; angiography; and, more recently, vascular color Doppler ultrasound.

Arteriography is the most precise method for diagnosing renal artery stenosis, but it has some limitations, such as allergic reaction and the risk of nephrotoxicity due to the contrast medium, in addition to complications inherent to the procedure and its high cost. Another important factor is that arteriography is an anatomic study, and, therefore, does not provide hemodynamic information about the renal lesions.

This study aimed at assessing the accuracy of vascular color Doppler ultrasound as compared with that of arteriography in identifying hemodynamically significant renal artery stenoses.

Methods

We carried out a prospective double-blind study at the Noninvasive Vascular Laboratory of the Hospital de Caridade of the Santa Casa de Misericórdia de Curitiba/PUCPR, to assess the accuracy of vascular color Doppler ultrasound in the diagnosis of stenotic or obstructive lesions in the renal arteries as compared with that of arteriography, which is considered the gold standard.

One hundred and thirty-seven renal arteries from 69 adult patients (30 men and 39 women) suspected of having renovascular arterial hypertension, with no distinction of complexion or biotype, and a mean age of 54 years were studied. One of the patients had undergone nephrectomy prior to the study.

The following patients with arterial hypertension of recent onset were included in the study: young individuals with no familial history of hypertension; individuals > 55 years with arterial hypertension of recent onset or abrupt lack of control; hypertensive individuals refractory to treatment; hypertensive individuals with an abdominal murmur; and individuals with predominantly diastolic arterial hypertension (> 120 mmHg). Patients with the following characteristics were excluded from the study: previous diagnosis of renal artery lesion; history of allergy to iodinated contrast me-

dium; and behavior alterations preventing patient's collaboration during the complementary examinations.

All patients accepted in the study underwent ultrasonography and arteriography, and the radiologists and ultrasonographers ignored the previous diagnosis. The ultrasound and arteriography of the same patient were interpreted in a double-blind manner according to previously defined interpretation criteria. The interval between ultrasonography and arteriography did not exceed 30 days.

The anatomical and hemodynamic assessment of the lesions in the renal arteries with vascular color Doppler ultrasound was performed according to the direct technique with the patients in the supine position with low-frequency curve transducers (2 to 3.5 MHz) to allow greater penetration (10-12 cm) of the ultrasound beam.

For flow assessment, a small color box was maintained with an appropriate depth for maximizing the number of frames per minute (frame rate) and a frequency of pulse repetition adequate for the structure to be analyzed. The gain and color filter were adjusted to allow adequate color-flow mapping.

The pulsed Doppler was positioned in the area of interest in the center of the vessel in normal arteries or in the site of the hemodynamically significant alteration, represented by the increase in flow velocities and turbulence. The volume sample was adjusted for the size of the vessel, avoiding contamination with information from other neighboring structures, mainly respiratory movements. For the abdominal aorta and major renal arteries, the angle of incidence of the pulsed Doppler was maintained close to 60°. The gain, the filter, and the scales of the velocity curves of the pulsed Doppler were adjusted to provide an adequate curve for measuring velocities.

Anatomically, the renal arteries originate perpendicularly from the proximal segment of the abdominal aorta and travel towards the kidney in an angle of approximately 60°. Therefore, the origin and the proximal segment of the renal arteries were longitudinally assessed on a transverse section of the abdominal aorta in the epigastric region (fig. 1). Based on the section in the epigastric region, depending on the anatomy and biotype of the patient, sometimes almost the entire extension of the renal arteries can be assessed. The distal segments and the hilum of the renal arteries, as well as the measurement of the renal size in the respective lumbar regions, were assessed with longitudinal and transverse sections.

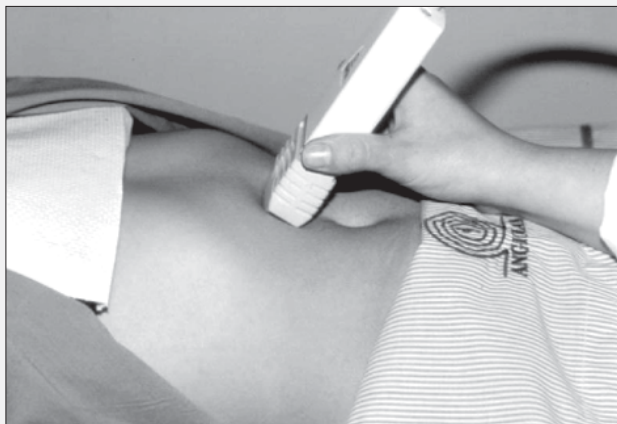

Fig. 1 - Position of the transducer in the epigastric region for assessing the origin of renal arteries.

Once the renal arteries were identified on color-flow mapping in the longitudinal section, the volume sample of pulsed Doppler was located for spectral analysis and routine measurement of the systolic and diastolic velocities in the origin or any other segment of the vessel that showed flow alterations in color-flow mapping, always with correction of the Doppler insonation angle to 60°.

The systolic velocity in the abdominal aorta was obtained in the longitudinal section in its proximal segment at the level of the origin of the superior mesenteric artery, also respecting the Doppler insonation angle of 60°, for calculating the renal-aorta index, ie, the relation between the systolic velocities of the renal arteries and the abdominal aorta.

Considering the criteria of Strandness Jr¹ (tab. I) for the absolute values of the systolic velocity in the renal arteries, the renal-aorta index, and the renal size, the renal arteries were classified as follows: normal, with moderate stenoses (< 60%), with hemodynamically significant stenoses (> 60%), and obstructed.

The examinations were performed preferably in the morning, and the patients were recommended to observe a 12-hour fasting period.

Anatomical assessment of the arterial obstructions based on the arteriographic image was performed with the digital subtraction technique, with selective arterial catheterization through femoral artery puncture, studying the renal arteries and the renal parenchyma, as well as the excretion of the contrast medium.

Measurement of the degree of renal artery stenosis was obtained through the relation between the diameter of the normal artery and the impaired segment of the vessel. The normal renal arteries appeared contrasted in their entire extension with regular walls, including the visualization of the intraparenchymatous arteries. The stenoses were quantified as moderate, when the anatomical reduction in the diameter of the arterial lumen did not exceed 60%, and significant, when the anatomical reduction in the diameter of the arterial lumen exceeded 60%, with a reduction in the renal excretion of the contrast medium. In the obstructions, the renal artery was not contrasted in its usual topography and no contrast medium was observed in the renal parenchyma.

For the arterial ultrasonographic study, the Siemes-Sonoline Elegra® image and flow device (echoDoppler) with Doppler color-flow mapping was used. For the arteriographic study, the Siemens Angioscopy® digital image subtraction device was used.

The findings of the ultrasonographic study of the stenoses and obstructions of the renal arteries were compared with the arteriographic findings. The minimum sample size was calculated for the inclusion of 50 renal arteries in the study.

The indices of quality (sensitivity, specificity, accuracy, and positive and negative predictive values) for vascular color Doppler ultrasound were calculated for differentiating hemodynamically significant stenosis (> 60%) from moderate stenoses and normal arteries, considering arteriography the gold standard.

Table I - Diagnostic criteria of vascular color Doppler ultrasound

| Condition | Systolic velocity | Renal-aorta index |
|----------------|-------------------|-------------------|
| Normal | < 180 cm/s | < 3.5 |
| Stenosis < 60% | > 180 cm/s | < 3.5 |
| Stenosis > 60% | > 180 cm/s | > 3.5 |
| Obstruction | Absente | - |

Results

Based on previously defined criteria, of the 137 renal arteries assessed on vascular color Doppler ultrasound, 43 (31.3%) were considered normal, 11 (8.1%) had moderate stenoses, 70 (51.1%) had hemodynamically significant stenoses, 7 (5.1%) were obstructed, and in 6 (4.4%) arteries the examination was inconclusive.

The arteriographic findings were as follows: 50 (36.5%) renal arteries were normal, 10 (7.3%) had moderate stenoses, 67 (48.9%) had hemodynamically significant stenoses, 9 (6.6%) were occluded, and in 1 (0.7%) the examination was inconclusive.

After excluding the inconclusive examinations (7 arteries), the comparison of the methods in the remaining 130 arteries showed 116 (89.2%) concordant results and 14 (10.8%) discordant results.

Of the 116 arteries with concordant results, 40 were considered normal, 6 were moderately stenotic, 63 were hemodynamically significantly stenotic, and 7 were obstructed (fig. 2).

Of the 14 renal arteries with discordant results, 9 were false-positive and 5 false-negative on vascular color Doppler ultrasound as compared with arteriography. For all 9 arteries whose results were considered false-positive, the systolic velocity detected was greater than 200 cm/s, and in 5 of them the renal-aorta index exceeded 4. The arteries whose results were considered false-negative had renal-aorta indices lower than 3.5 and systolic velocities close to 200 cm/s.

Considering arteriography as the gold standard and meeting the predefined criteria of vascular color Doppler ultrasound, the differentiation of the hemodynamically significant stenosis (> 60%) from the moderate stenoses and from the normal arteries showed the following values of sensitivity and specificity, positive and negative predictive values, respectively, 95.33%, 88.14%, 89.86%, and 94.55%. The overall accuracy of the procedure as compared with that of arteriography was 91.94%.

The 6 (4.4%) cases considered inconclusive on vascular color Doppler ultrasound had technical limitations in the identification and analysis of the origin and proximal segment in 4 arteries, and difficulties occurred in interpreting the elevated velocities in 2 arteries. In 1 case, the presence of an aneurysm of the juxtarenal abdominal aorta caused difficulties in the study of the renal artery on arteriography.

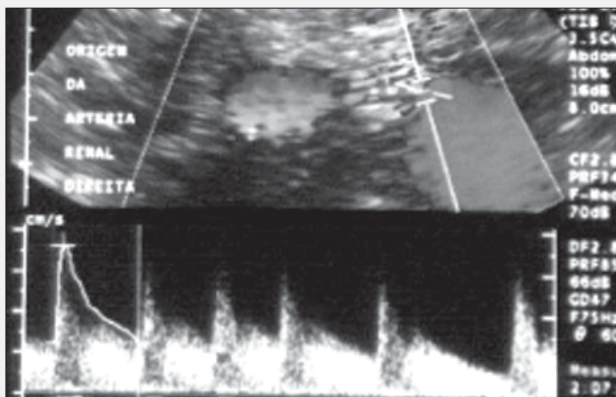


Fig. 2 - Example of hemodynamically significant stenosis of the left renal artery on vascular color Doppler ultrasound. Note the flow turbulence in the renal artery and the increase in systolic velocity (400 cm/s).

Discussion

The major objective of the complementary examinations in the investigation of patients with renovascular hypertension is to identify the anatomic lesions in the renal arteries and their branches, and to determine which of these lesions will be physiologically significant, ie, responsible for the activation of the renin-angiotensin system. Haimovici and Zincola² reported that stenoses greater than 60% of the diameter of the renal arteries of dogs caused a reduction in the renal perfusion pressure and the absence of a nephrogram on excretory urography, being, therefore, physiologically significant lesions.

Although arteriography has an interobserver variation between 79 and 87%, it is considered the examination of choice for the anatomical diagnosis of stenotic or obstructive lesions of the renal arteries. However, in addition to not providing hemodynamic information, a 1.8 to 9% risk of complications related to arteriography, both systemic and local, exists³⁻⁷. Therefore, a noninvasive method of selection that may identify the anatomic and hemodynamically significant lesions of the renal arteries is required.

The use of vascular color Doppler ultrasound for the diagnosis of vascular diseases has been extended in recent decades with improvement in the sensitivity of the equipment and use of color-flow mapping. The direct criteria of the examinations for the diagnosis of renovascular hypertension are based on measurement of the velocities in the renal arteries, on the renal-aorta index, and on renal size.

Several authors have proposed values between 100 and 200 cm/s for the peak systolic velocity. Authors, who considered a velocity > 100 cm/s as a parameter, had low accuracy indices, but a high index of inconclusive examinations, denoting individual technical limitations in the study of the renal arteries on vascular color Doppler ultrasound^{8,9}.

Authors using values of peak systolic velocity > 180 cm/s had better accuracy indices and fewer technical limitations. Hansen et al¹⁰ considered the value of 180 cm/s as the base of hemodynamic alterations in the renal arteries¹⁰. Mirales et al¹¹ considered the velocity of 198 cm/s; Ollin et al¹² and Kohler et al¹³ considered the velocity of 200 cm/s.

According to the initial studies at Washington University, a renal-aorta index ≥ 3.5 indicates hemodynamically significant renal artery stenosis¹³⁻¹⁵. Mirales et al¹¹ proposed a value > 3.3 for this criterion, but with values of sensitivity and specificity similar to those of the Washington group¹¹.

Our results of vascular color Doppler ultrasound compared with those of arteriography for identifying hemodynamically significant stenoses showed indices of quality, indicating sensitivity, specificity, positive and negative predictive values, and overall accuracy of 95.38%, 88.14%, 89.86%, 94.55%, and 91.94%, respectively, with referential criteria of velocity of 180 cm/s and renal-aorta index of 3.5. These values are similar to the following variations reported in the literature: sensitivity between 67 and 98%, specificity between 89 and 100%, positive predictive value between 85.7 and 98%, and negative predictive value between 92.5 and 98%^{3,5,6,9}.

Still in our study, the results of 14 renal arteries found on vascular color Doppler ultrasound and arteriography disagreed, 9 being false-positive and 5 false-negative. In all 9 arteries whose

results were false-positive, the systolic velocity detected exceeded 200 cm/s, and, in 5 of them, the renal-aorta index was greater than 4. These values, therefore, met the criteria required for the diagnosis of hemodynamically significant stenosis, although they were not confirmed on arteriography. The arteries whose results were false-negative had renal-aorta indices lower than 3.5 and systolic velocities close to 200 cm/s, compatible with moderate stenoses; on arteriographic interpretation, however, they were considered hemodynamically significant stenoses.

The technical limitations of color Doppler ultrasound reported in up to 15% of the cases in the literature may relate to the anatomic variations in renal vascularization, such as early ramification, accessory renal artery, and polar arteries, or may relate to difficulties in performing the examination in patients with cardiac arrhythmias, severe respiratory diseases, morbid obesity, or an excessive amount of gases. Previous gastrointestinal preparation, ability of the examiner, and time for performing the examination

are factors that contribute to reducing the percentage of inconclusive examinations¹¹. Our inconclusive cases (4.4%), compatible with the figures in the literature, relate to the previously cited factors. As the objective of the study was to assess the accuracy of the method in differentiating the hemodynamically significant stenoses, the inclusion of these cases could alter the overall accuracy of the method (although they represent only 5% of the total case series) without directly interfering with the specific study of the hemodynamically significant stenoses.

In conclusion, the experience of the vascular ultrasonographer with the direct technique for renal artery evaluation, the adequate use of diagnostic criteria and the use of sensitive equipment enable the reliable study of most patients suspected of having renovascular hypertension. Because vascular color Doppler ultrasound is a direct noninvasive diagnostic method that has good accuracy, it may be used as a routine examination for selecting patients suspected of having renovascular hypertension for undergoing arteriography.

References

1. Strandness DE Jr. Duplex scanning in diagnosis of renovascular hypertension. *Surg Clin North Am* 1990, 70: 109-17.
2. Haimovici H, Zinicola N. Experimental renal artery stenosis: diagnostic significance of arterial hemodynamics. *J Cardiovasc Surg*. 1962, 3: 259-62.
3. Jaarsveld BC, Pierterman H, Dijk LC, Seijen AJ, Krijnen P et al. Inter-observer variability in the angiographic assessment of renal artery stenosis. *J Hyperten* 1999, 17: 1731-36.
4. Sigstedt B, Lunderquist A. Complications of angiography examinations. *Am J Roentgenol* 1978, 130: 455-60.
5. Hessel SJ, Adams DF, Abrams HL. Complications of angiography. *Radiology* 1981, 138: 273-81.
6. Vaughn JR, Sacharias N. Arteriography complications in DAS era. *Radiology* 1992, 182: 243-6.
7. Egglin T, O'Moore PV, Feinstein AR, Waltman AC. Complications of peripheral arteriography: A new system to identify patients at increased risk. *J Vasc Surg* 1995, 22: 787-94.
8. Desberg A, Pausther DM, Lammert GK, Hale J, Troy RB, et al. *Radiology*, 1990, 12: 227-36.
9. Berland LL, Koslin DB, Routh WD, Keller FS. Renal artery stenosis: prospective evaluation of diagnosis with color duplex ultrasound compared with angiography. *Radiology*. 1990, 174: 421-3.
10. Hansen KJ, Tribble RW, Reavis SW, Canzanello VJ, Creaven TE, et al. Renal duplex sonography: evaluation of clinical utility. *J Vasc Surg*. 1990, 12: 250-7.
11. Mirales M, Cairois M, Cotillas J, Gimenez A, Santiso A. Value of doppler parameters in the diagnosis of renal artery stenosis. *J Vasc Surg*. 1996, 23: 428-35.
12. Ollin JW, Piedmonte MR, Yoing JR, DeAnna S, Grubb M et al. The utility of duplex ultrasound scanning of the renal arteries for diagnosing significant renal artery stenosis. *Ann Intern Med* 1995, 122: 833-8.
13. Kohler TR, Zieler, Martin RL, Nichols SC, Bergelin RO, et al. Non invasive diagnosis of renal artery by ultrasonic duplex scanning. *J Vasc Surg* 1986, 4: 450-6.
14. Hoffmann U, Edwards JM, Carter S, Goldman ML, Harley JD et al. Role of duplex scanning for the detection of atherosclerotic renal artery disease. *Kidney Int* 1991, 39: 1232-39.
15. Taylor DC, Kettler MD, Moneta GL, Kohler TR, Kazmers A et al. Follow-up of renal artery stenosis by duplex ultrasound. *J Vasc Surg*. 1988, 7: 633-9.