

Mycotic Coronary Aneurysm: Report of Two Cases

Franco Javier Vallejo García, Carlos Eusse, Carlos Tenorio, Carlos Uribe

Clinica Cardiovascular Santa Maria, Medellín - Colombia

The number of percutaneous interventions with stent implantation has increased dramatically in recent years, although the frequent use of this device in reports of infections is extremely rare. In this article we report two cases of mycotic aneurysm after implantation of stents with different clinical presentations and outcomes.

Introduction

Stents have been a major shift in interventional cardiology, deployed in over 90% of cases in which percutaneous coronary intervention is performed¹.

It is known that the insertion of foreign bodies can cause infection, so the implantation of medical devices has become one of the main risk factors for nosocomial infections. Nevertheless, reports of coronary stent infections are extremely rare².

Case 1

A 49-year-old male individual with a history of coronary disease that required two coronary interventions, the first one with implantation of sirolimus-eluting stent in the anterior descending artery and the second 20 days before admission, with non-drug-eluting stent in the circumflex artery (both procedures performed in the same catheterization laboratory with new material).

Medical examination within 3 months after completion of the interventional procedure for two weeks of progressive dyspnea, chest pain and fever.

The patient is admitted with jugular engorgement at 45th, rales up to the middle third of the lungs, no heart murmur, and hepatomegaly. The ECG was considered and revealed no disturbance, and blood count with leukocytosis.

The transthoracic echocardiogram revealed dilated cardiomyopathy with an ejection fraction of 30% and pericardial effusion in moderate quantity.

Keywords

Stents; infection; aneurysm, infected.

Over evolution, the patient presented fever peaks of 41° C and elevated acute phase reactants, getting three positive blood cultures for methicillin-sensitive *staphylococcus aureus*, starting antibiotic therapy with parenteral oxacillin. Upon these findings, we performed multislice chest computed tomography angiography with three-dimensional reconstruction, which revealed aneurysmal dilatation (27 x 19 mm), which was filled with contrast in the proximal segment to the previously implanted in the circumflex artery, and occlusion of the distal vessel and moderate hemopericardium (Figure 1A).

The patient showed clinical and radiological recovery (Figure 1B) improved after 6 weeks of antibiotic therapy.

Case 2

A male 65 year-old individual with a history of chronic renal failure (CRF) stage 5, type 2 diabetes mellitus (T2DM), hypertension and coronary disease; history of paclitaxel-releasing stent in the right coronary artery (RCA) and sirolimus-eluting stent in the anterior descending artery (ADA) 4, four months before admission (both procedures performed in the same catheterization laboratory with new material); medical examination within 5 months after completion of the interventional procedure for four days of progressive dyspnea, chest pain and fever.

Patient is pale, sweating, hypotensive, with fever and crackling rales at lung bases, hepatomegaly and 1st degree edema of lower limbs. Echocardiography with negative T wave in the high lateral wall, complete blood count with leukocytosis, neutrophilia, high C-reactive protein (CRP) and positive cardiac biomarkers.

There were 3 positive blood cultures for SAMS early in the antibiotic therapy with an unsatisfactory response, thereby worsening the condition. On the persistence of symptoms, coronary angiography and chest computed tomography angiography were performed and showed a large aneurysm (20 x 10 mm) in RCA (Figure 2). The patient was transferred to ICU where he later died.

Discussion

The incidence of infections after coronary stenting is unknown, however, the low number of published reports suggests that it is an uncommon complication of percutaneous coronary intervention (PCI). The incidence of positive blood cultures after the procedure is 7.3% after a diagnostic catheterization and 4.6% after PCI; the most commonly isolated bacteria are *staphylococcus aureus*, negative *staphylococcus coagulase*, and group B *streptococcus*¹.

Mailing address: Franco Javier Vallejo García •

cll 7 sur numero 37a-25 apto 408 torre 1 - Parque residencial salento -

El poblado - Antioquia - Medellín - CE

E-mail: homefra78@yahoo.es

Manuscript received May 26, 2010; revise manuscript received September 05, 2010; accepted November 17, 2010.

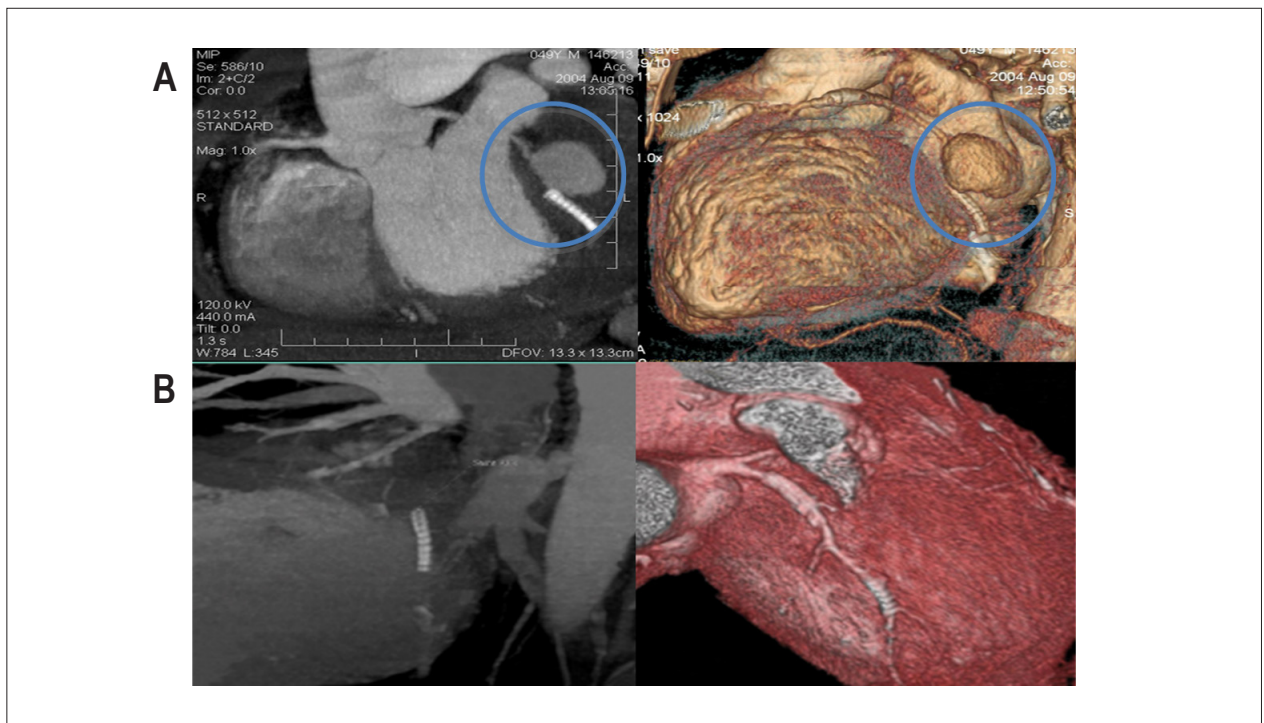


Figure 1 - A - Computed tomography angiography with large aneurysm in the proximal segment of circumflex artery before stent⁶. B - Control showing the disappearance of the aneurism⁷.

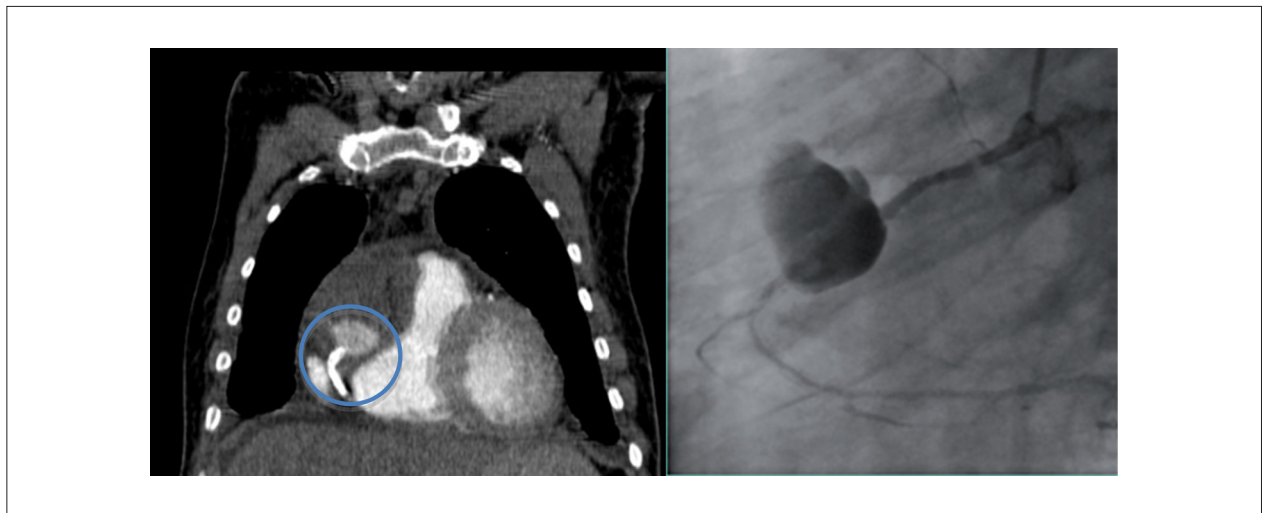


Figure 2 - Computed tomography angiography and coronary angiography aneurysm in the right coronary artery.

In both cases reported here, the infection was subacute between 20 days and 4 months; the predominant symptoms were fever, chest pain and dyspnea; blood cultures were positive in the two patients and the bacteria identified was methicillin-resistant *staphylococcus aureus*.

The identification of the infection requires specific cardiac imaging, including transthoracic echocardiography, transesophageal echocardiography, coronary angiography, computed axial tomography scan and nuclear magnetic resonance imaging (NMRI)³. Considering the limited data

available, there are no recommendations about which of the diagnostic methods mentioned above is the elected one, being used as a basis for the local experience⁴.

Therapy with intravenous antibiotics was chosen, however, considering that foreign body infections are extremely resistant to antibiotics, surgical debridement and/or stent removal could be necessary⁵. Our cases were managed with endovenous therapy, reaching a survival of 50%. Out of the 10 cases reported in the literature, six needed additional surgical procedure, with a mortality of

Case Report

50% during the intra and postoperative suggesting only a modest benefit of surgery in this population.

Potential Conflict of Interest

No potential conflict of interest relevant to this article was reported.

Sources of Funding

There were no external funding sources for this study.

Study Association

This article is part of a full professor's thesis on Franco Javier Vallejo Garcia from the Clinica Cardiovascular y la Universidad Pontificia Bolivariana.

References

1. Kaufman BA, Kaiser C, Pfisterer ME, Bonetti PO. Coronary stent infection: a rare but severe complication of percutaneous coronary intervention. *Swiss Med Wkly*. 2005;135(33-34):483-7.
2. Liu JC, Cziperle DJ, Kleinman B, Loeb H. Coronary abscess: a complication of stenting. *Catheter Cardiovasc Interv*. 2003;58(1):69-71.
3. Golubev N, Schwammenthal E, Di Segni E, Pudil R, Hay I, Feinberg MS. Echocardiographic imaging of coronary artery abscess following stent implantation. *Echocardiography*. 2004;21(1):87-8.
4. Bangher M, Liva P, Baccaro J. Coronary stent infection: case report and definition. *Rev Esp Cardiol*. 2003;56(3):325-6.
5. Singh H, Singh C, Aggarwal N, Dugal JS, Kumar A, Luthra M. Mycotic aneurysm of the left anterior descending artery after sirolimus-eluting stent implantation: a case report. *Catheter Cardiovasc Interv*. 2005;65(2):282-5.
6. Aoki J, Kirtane A, Leon M, Dangas G. Coronary artery aneurysms after drug-eluting stent implantation. *JACC Cardiovasc Interv*. 2008;1(1):14-21.
7. Virmani R, Guagliumi G, Farb A, Musumeci G, Grieco N, Motta T, et al. Localized hypersensitivity and late coronary thrombosis secondary to a sirolimus-eluting stent: should we be cautious? *Circulation*. 2004;109(6):701-5.