

## Case 2/2015 A 33-Year-Old Woman with Double Right Ventricular Chamber and Ventricular Septal Defect

Edmar Atik

Instituto do Coração, Faculdade de Medicina, Universidade de São Paulo – USP, São Paulo, SP - Brazil

**Clinical data:** non-progressive shortness of breath on moderate exertion for 1 year. A heart murmur had been heard at one month of age, and the patient had been followed up irregularly ever since. She did not report cyanosis and had recently been prescribed with hydrochlorothiazide. Laboratory tests showed H = 4,700,000/mm<sup>3</sup>; Hct = 41%; Hg = 13.4 g/dL.

**Physical examination:** normal breathing, acyanotic, normal pulses. Weight: 62 kg; height: 163 cm; blood pressure: 110/60 mmHg; heart rate: 78 bpm; oxygen saturation: 97%; aorta not palpable on the suprasternal notch.

The apical impulse was not palpable in the precordium, and there were no systolic impulses on the left sternal border. Normal heart sounds; grade 3/4 course systolic murmur on the mid-left sternal border accompanied by thrill. The liver was not palpable.

### Laboratory tests

**Electrocardiogram** showed normal sinus rhythm and signs of right ventricular (RV) overload. Low-voltage QRS complex with qR morphology in V1, RS in V6 with final conduction disturbance through the right bundle branch. QRSA: -70°, TA: + 30°.

**Chest radiograph** showed normal cardiac silhouette (cardiothoracic ratio of 0.46). The pulmonary vascular network was normal and the arch of the pulmonary artery was concave (Figure 1).

**Echocardiogram** (Figure 2) showed right ventricular inflow tract stenosis causing an intraventricular gradient of 80 mmHg, with a 13-mm diameter ventricular septal defect partially occluded by the tricuspid valve, thus resulting in an effective 4.7-mm orifice. There was RV hypertrophy with mildly enlarged right cardiac chambers. Gradient between ventricles was 82 mmHg. There was a small aneurysm formation in the ventricular septum. Measurements were as follows: left ventricle (LV) = 45 mm; left atrium (LA) = 32; Ao = 26; septum = posterior wall = 7 mm. LV ejection fraction = 66%. There

was a 3-mm foramen ovale with bidirectional predominantly left-to-right shunt. RV systolic pressure = 110 mmHg.

**Cardiac catheterization** (Figure 2) Pressure values were: RV inflow tract = 98/13; RV outflow tract = 25/7; PT = 20/7-12; LV = 124/11; Ao = 126/64; PC = 11 mmHg.

**Clinical diagnosis:** Severe RV inflow tract stenosis with perimembranous ventricular septal defect of little impact, with no hypoxemia and/or heart failure, in natural course.

**Clinical reasoning:** The clinical elements of long-standing right obstructive congenital heart defects without hypoxemia present as shortness of breath and are not accompanied by hematocrit elevation. For this reason, with preserved cardiac output, their outcome is favorable thanks to compensatory myocardial hypertrophy. The normal heart sounds suggest normal arterial position, and the preserved pulmonary flow results from an adequate compensatory mechanism. The severe systolic murmur in the mid-left sternal border suggests the presence of an obstructive lesion in the RV inflow tract and differentiates from the murmur of the ventricular septal defect for being coarser and stronger. Ventricular septal defects of little impact do not result in any functional disturbance, and their auscultatory manifestation mingles with that of the obstructive defect. RV systolic overload on the electrocardiogram suggests the diagnosis of an obstructive lesion on the right. Chest radiograph showing normal cardiac silhouette is consistent with good RV function, and the normal pulmonary vascular network results from the maintained antegrade flow.

**Differential diagnosis:** Heart diseases with RV outflow tract obstruction may have a similar presentation, except for the systolic murmur, which is more intense in the upper left sternal border, irradiating to the neck vessels, albeit mildly.

**Management:** Because of the long-standing systolic impact with severe hypertrophy and nearly systemic RV pressures, indication of operation becomes mandatory, aiming at relieving the chamber obstruction, which would imply a greater possibility of development of myocardial fibrosis, heart failure, arrhythmias and earlier death.

**Commentaries:** Obstructive congenital heart defects usually manifest early in life by means of a heart murmur. Cardiac compensation with maintained antegrade flow is achieved by myocardial hypertrophy. The consequences of this phenomenon are directly proportional to the degree of obstruction. In the present case, this obstruction, which was more intense in adulthood and whose manifestation of symptoms had been more recent, progressed throughout time, which permitted a good outcome during this period. Hence, the patient had a favorable course up to the fourth decade of life. Most of these patients are treated in childhood and very uncommonly in adulthood. These defects result

### Keywords

Double chambered right ventricle, right ventricle inflow tract stenosis, ventricular septal defect, hypertrophy of right ventricle.

Mailling Address: Edmar Atik •

Rua Dona Adma Jafet, 74, conj. 73, Bela Vista. Postal Code 01308-050. São Paulo, SP – Brazil

E-mail: eatik@cardiol.br; conatik@incor.usp.br

Manuscript received July 23, 2014; revised manuscript July 31, 2014; accepted July 31, 2014.

DOI: 10.5935/abc.20140218

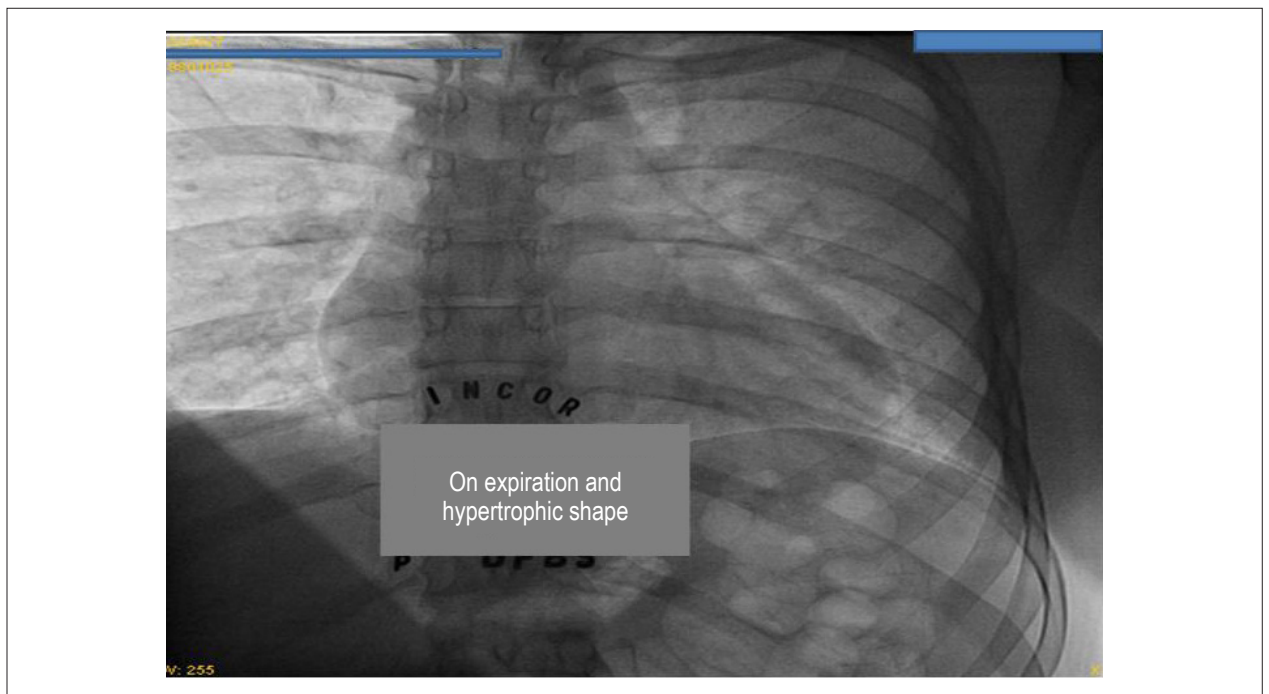


Figure 1 – Chest radiograph showing normal cardiac silhouette, with a round shape resulting from myocardial hypertrophy due to an obstructive lesion on the right side.

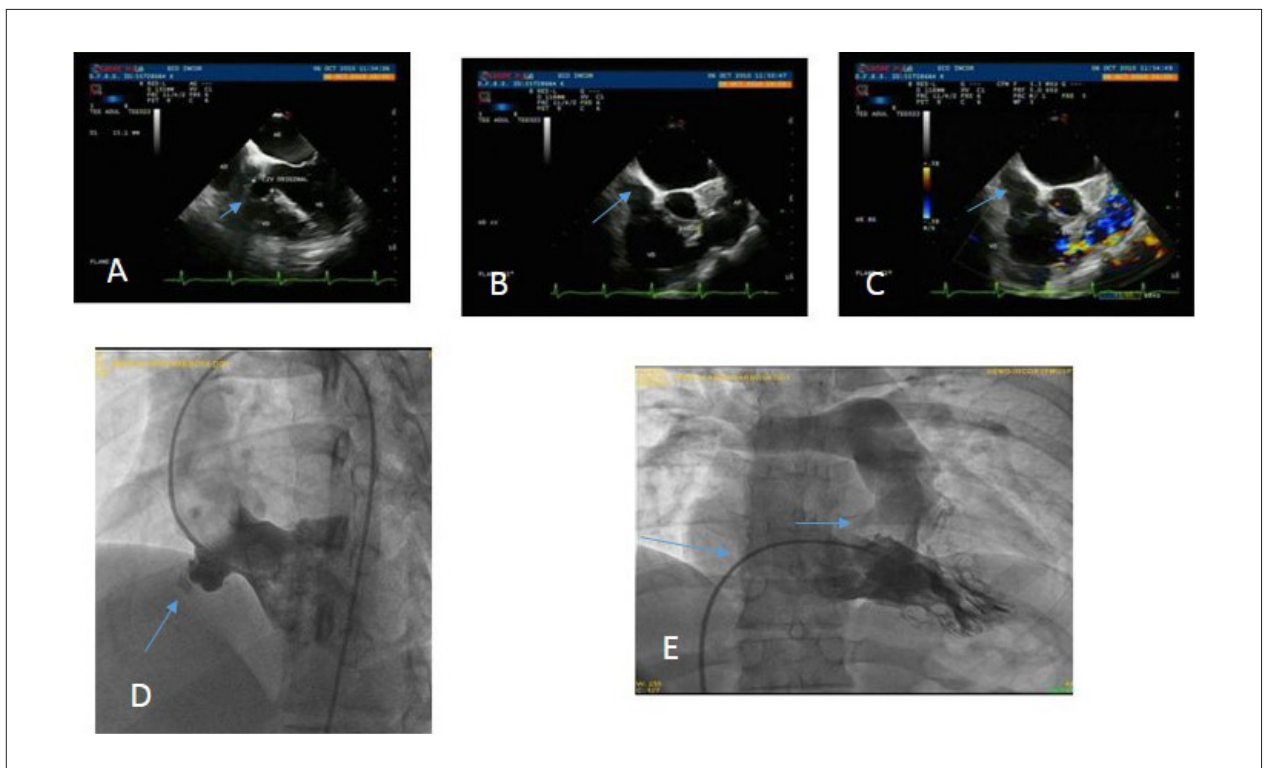


Figure 2 – (A) 4-chamber apical view echocardiogram shows ventricular septal defect with septal aneurysm (arrow); (B and C) short-axis cross-sectional view showing right ventricular inflow tract stenosis (arrows, in colors). (D) Angiography showing septal aneurysm (arrow) and (E) right ventricular inflow tract stenosis (arrow) with marked hypertrophy.

## Clinicoradiological Session

---

from an impaired growth of the trabecular myocardium during the early fetal formation, and the non-uniformity in its position, closer to the tricuspid or pulmonary valve, which causes the ventricle to divide into two parts – a proximal and a distal part. They are frequently associated

with ventricular septal defects (80% of cases)<sup>1,2</sup>. Even when their impact is minor, these obstructive anomalies should be treated earlier to prevent an unfavorable outcome in relation to the development of myocardial fibrosis, arrhythmias and heart failure.

### References

1. López-Fernández S, Molina-Lerma MJ, García-Orta R, Medina-Benítez A. Double-chambered right ventricle in adults: an 'uncommon' entity, new ways of imaging. *Eur Heart J*. 2013;34(11):801.
2. Lee WJ, Song BG, Kang GH, Park YH, Chun WJ, Oh JH. A case of asymptomatic isolated double-chambered right ventricle in an adult man. *J Clin Ultrasound*. 2013;41(9):579-81.