

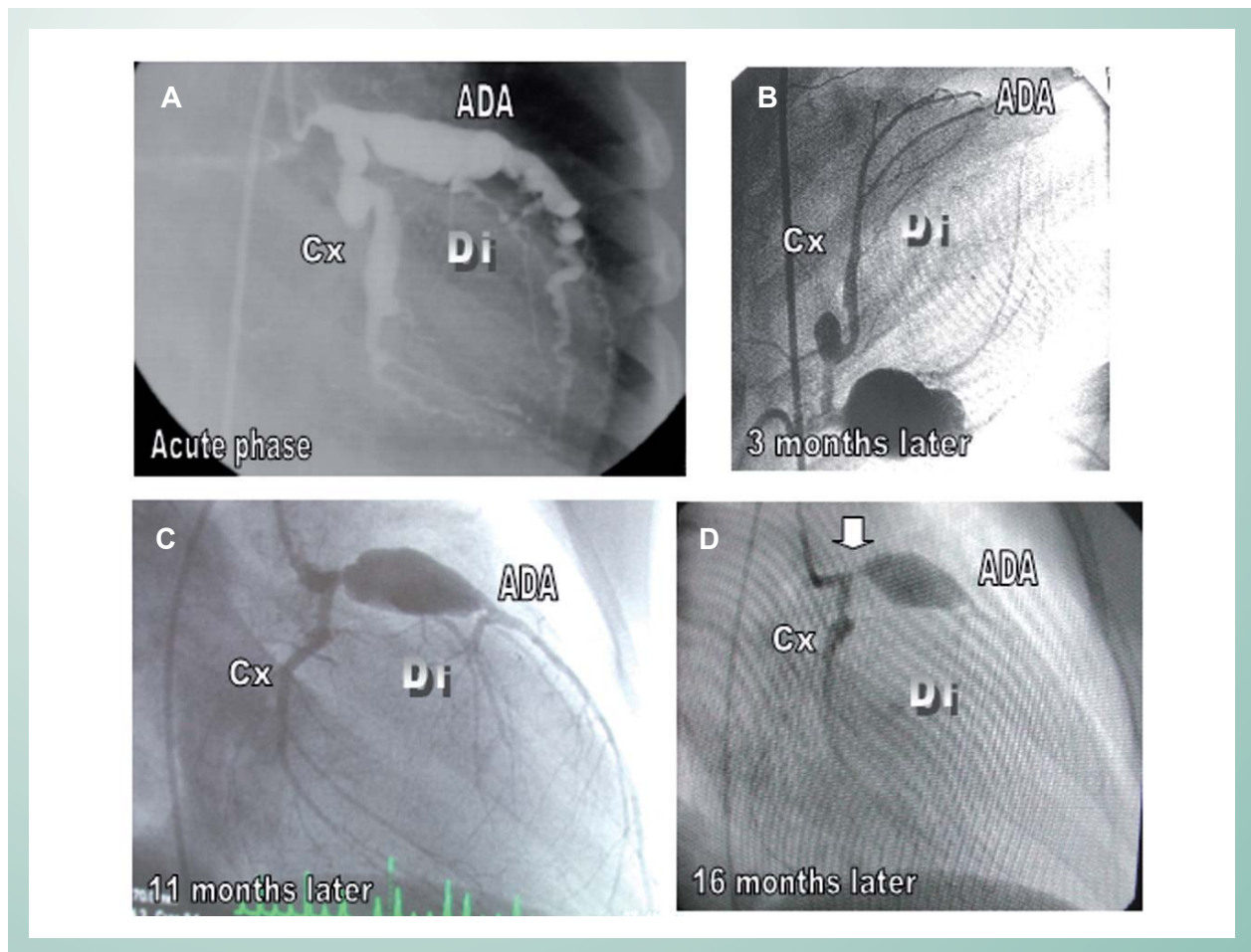
## Kawasaki Disease: Giant Coronary Arteries Aneurysms Regression and Later Stenosis

Edmar Atik

Instituto do Coração do Hospital das Clínicas da Faculdade de Medicina da Universidade de São Paulo - São Paulo, SP, Brazil

Thirty days previously, a five-year-old boy had presented a clinical picture suggestive of Kawasaki disease (fever, generalized erythema, edema and scaling of the extremities, and inflammatory markers, such as erythrocyte sedimentation

rate = 100 mm/h, CRP = 50 U, leukocytes  $12,000/\text{mm}^3$  and platelets =  $540,000/\text{mm}^3$ ). He received appropriate treatment including gamma globulin - 1g/Kg on the fifth and eighth day together with aspirin.



**Fig. 1** - Giant diffuse left coronary artery aneurysms (1A) with a clear involution some months later (1B), albeit showing a residual giant aneurysm at the anterior descending artery (1C), which decreased progressively until 16 months following the initial treatment (1D), but developed an obstructive lesion (arrow) before the remaining aneurysm. There was also total obstruction at the right coronary artery. Cx: circumflex artery, Di: diagonal artery, IVA: anterior INTERVENTRICULAR artery

### Key words

Kawasaki disease; coronary aneurysm.

Mailing Address: Edmar Atik •

Av. Enéas de Carvalho Aguiar, 44 – 05403-000 – São Paulo-SP, Brazil

E-mail: conatik@incor.usp.br

Manuscript received May 12, 2006; revised manuscript received May 18, 2006; accepted May 18, 2006.

## Image

An angiographic study on the 27<sup>th</sup> day of the disease revealed extensive diffuse left coronary artery aneurysms with a total right coronary artery obstruction (Fig.1A). Continuing high-dose aspirin for two months beyond standardized treatment, a clear aneurysm involution by repeated angiography was observed, 3 months later (Fig.1B). This aneurysm involution occurred mostly after 11 months (Fig.1C) and 16 months (Fig.1D), with normalization in caliber of the left coronary artery, except for an isolated aneurysm in the anterior descending coronary artery that diminished but did not suffer total involution.

In this last coronary angiography, an artery stenosis (arrow) before the aneurysm finally led to the indication of myocardial revascularization by saphenous vein anastomosis to the diagonal and anterior descending arteries, with great success.

This report claims our attention owing to:

1. the involution of diffuse and extensive giant coronary aneurysms in the acute period of Kawasaki disease with prolonged aspirin treatment, drawing necessary attention to a more careful clinical management in this phase because of an undoubtedly greater surgical risk at this time.
2. the slower regression of isolated giant aneurysms that require careful follow-up with suitable anticoagulation therapy and an indication to surgery at an appropriate time in order to prevent a total coronary obstruction.

### Potential Conflict of Interest

No potential conflict of interest relevant to this article was reported.

## References

1. Atik E, Foronda A, Bustamante LNP. Doença de Kawasaki. Involução de gigantes aneurismas coronarianos após tratamento anti-inflamatório prolongado. Relato de Caso. Arq. Bras. Cardiol. 2003; 81: 265-8.
2. Chantepie A, Mauran P, Lusson JR, Vaillant MC, Bozio A. Cardiovascular complications of Kawasaki syndrome: results of a French multicenter study. Arch Pediatr. 2001; 8: 713-9.
3. Yoshikawa Y, Yagihara T, Kameda Y, Taniguchi S, Tsuda E, Kawahira T, et al. Result of surgical treatments in patients with coronary-arterial obstructive disease after Kawasaki disease. Eur J Cardiovasc Surg. 2000; 17: 515-9.
4. Oki I, Tanihara S, Ojima T, Nakamura Y, Yanagawa H. A multicenter collaborative study on the risk factors of cardiac sequelae due to Kawasaki disease: a one-year follow-up study. Acta Pediatr. 2000; 89: 1435-8.