

## Case 2/2013 – 23-Year-Old Woman with Dilated Right Ventricle, with no Residual Defects after Repair of Tetralogy of Fallot

Edmar Atik

Clínica privada do Dr. Edmar Atik, São Paulo, SP – Brazil

**Clinical data:** After repair of tetralogy of Fallot with good anatomical features through resection of infundibular pulmonary stenosis, with a myectomy and expansion of the right ventricular outflow tract with pericardial patch, and pulmonary valvotomy without annulus opening and closing of perimembranous ventricular septal defect at 12 months of age, there was a good subsequent clinical outcome. The patient currently tolerates physical exercise, but since the age of 15 reports precordial palpitations and sporadic tachycardia unrelated to exertion, with variable heart rate of 110-170 bpm. A 24-hour ambulatory electrocardiogram during this period showed polymorphic ventricular extrasystoles of 33-1623 episodes, refractory to adrenergic beta-blockers and digitalis medication. The patient has maintained, since the surgery, a gradient of up to 17 mmHg in the right ventricular outflow tract, correlated with slight and persistent systolic murmur auscultation in the left upper sternal border, without any other residual heart defect.

**Physical Examination:** Good general status, eupneic, acyanotic, normal pulses. Weight: 46.5 kg. Height: 157 cm. BP: 105/70 mmHg. HR: 54 bpm. The aorta was not palpable in the suprasternal notch. The *ictus cordis* was not palpable in the precordium and there were no systolic impulses. Heart sounds were normal and slight systolic murmur was present at auscultation, of + intensity, in the pulmonary area. The liver was not palpable and lungs were clear.

### Complementary Examinations

**Electrocardiogram** showed sinus rhythm and signs of right bundle branch block, unchanged since the surgical repair. AP: +10°. AQRs: +160°. AT: +60°. QRS duration was 0.14", PR = 0.14" and QTc = 0.40".

**Chest X-ray** showed slightly enlarged cardiac silhouette at the expense of the right chambers and normal pulmonary vascular network. The patient has maintained, since the surgical repair, similar and persistent enlargement in the cardiac area, with a cardiothoracic index of approximately 0.55, as shown in the sequence of radiographic images taken 2, 4 and 21 years after the surgery (Figure 1).

### Keywords

Tetralogy of Fallot, dilated right ventricle.

**Mailing Address: Edmar Atik•**

Rua Dona Adma Jafet, 74 cj 73 Postal Code 01308-050, São Paulo, SP - Brazil  
E-mail: conatik@incor.usp.br

**DOI:** 10.5935/abc.20130071

**Echocardiogram** showed dilated right heart chambers with RA = 44, RV = 50, LA = 35, LV = 41, Ao = 30 mm, RV ejection fraction = 63% (Simpson's method), LV ejection fraction = 66%, RV/PT pressure gradient = 15 mmHg and mild tricuspid regurgitation. At 15 years, the ratio between RV = 28 and LV = 40 was 0.7, similar to that found since the surgery, but two years ago it increased to 1.2.

**Magnetic Nuclear Resonance** (Figure 2) also showed increased right chambers with preserved ventricular function. RV end-diastolic volume = 98 ml/m<sup>2</sup>, LV = 89 ml/m<sup>2</sup>, RVEF = 43% and LVEF = 72%.

**Clinical Diagnosis:** Tetralogy of Fallot with good anatomical features, showing signs of persistent right ventricular dilation at late outcome after surgical repair, even without significant residual defects.

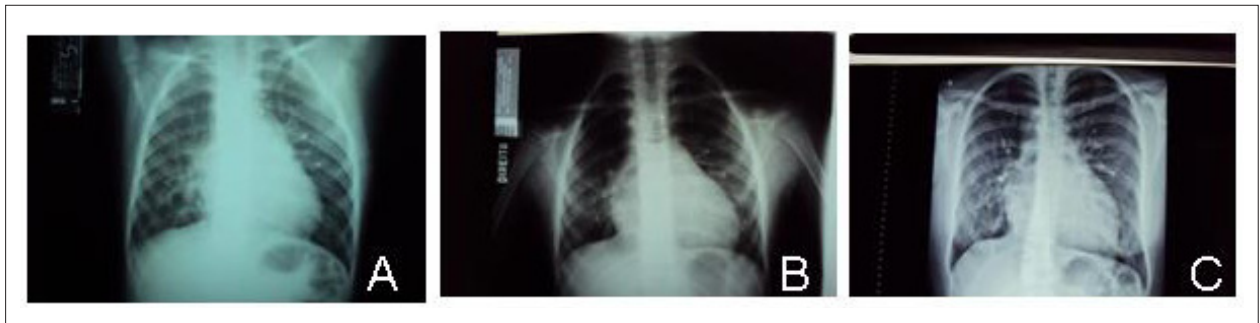**Clinical Rationale:** Clinical findings were compatible with the diagnosis of mild residual pulmonary stenosis. No symptoms, good tolerance to physical exertion and no signs of heart failure are also compatible with the favorable dynamic situation. The right ventricular dilation observed since the surgery, which increased two years ago, is not associated with any residual pathogenic anatomical aspect. This element has been responsible for the arrhythmias.

**Differential Diagnosis:** The persistent right ventricular dilation after surgical repair of tetralogy of Fallot is usually related to the pulmonary valve failure due to pulmonary annulus dilation. It may also derive from pulmonary valvotomy, even without prior expansion of the pulmonary annulus. None of these situations occurred in this case.

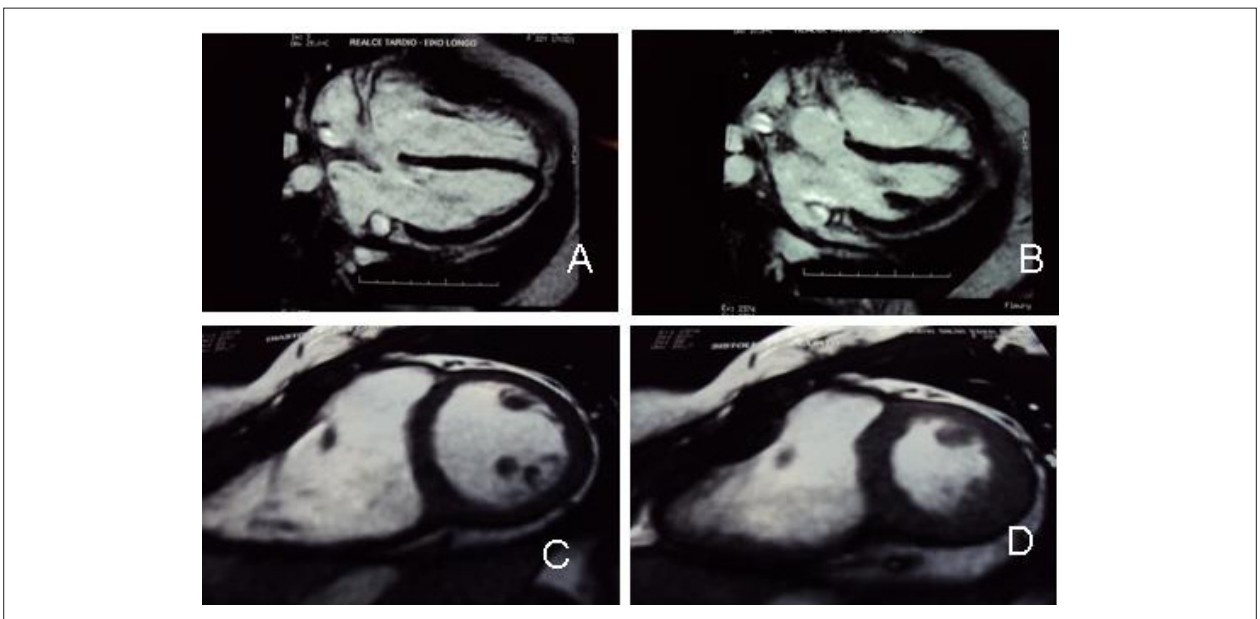
**Conduct:** Considering the good evolution and preservation of ventricular function, the expectant conduct was adopted, instructing the patient regarding recreational physical activity and prescribing vasodilator medication.

**Comments:** Patients with tetralogy of Fallot and good anatomical features, in which the expansion of the pulmonary annulus becomes unnecessary during surgical repair, have a good outcome, given the absence of residual defects that may be unfavorable. Thus, the postoperative course is similar to that of normal individuals. However, it is observed that sometimes, even without prior expansion of the pulmonary annulus, subsequent right ventricular dilation as a whole may occur, making it compulsory to question whether the simple dilation of the right ventricle outflow tract can be the cause of the evolutionary problem, probably a result of the deformity of the entire right ventricular structure.

In the literature, it is mentioned that the determinants of bigger right ventricular dilation after surgical repair of



**Figure 1** – Chest x-ray sequence showing a mildly enlarged cardiac silhouette (CTI = 0.55), 2, 4 and 21 years (A, B and C, respectively) after tetralogy of Fallot repair, even without significant residual defect. CTI: cardiothoracic index.



**Figure 2** – Nuclear magnetic resonance clearly shows, in longitudinal view, right ventricular dilation compared to the left ventricle (diastole in A), both preserving normal ventricular function (systole in B). In cross-sectional view, there is a persistent dilation of the right ventricular outflow tract in diastole in C and systole in D.

tetralogy of Fallot is related to a longer period since the repair surgery, the longer QRS duration and pulmonary valve regurgitation. The worsening in ventricular function, in turn, is related to the abnormal movement in the ventricular outflow tract, during the long period after the surgery and also the longer QRS duration. In our case, we observed as

the cause of persistent right ventricular dilation the prior expansion of the right ventricular outflow tract, which may have, over time, altered the structure of the cavity. Thus, this element becomes another surgical concern during the repair of the tetralogy of Fallot, even among those with good anatomical features.