

3D Echo Pilot Study of Geometric Left Ventricular Changes after Acute Myocardial Infarction

Marcelo Luiz Campos Vieira, Wercules Antonio Oliveira, Adriana Cordovil, Ana Clara Tude Rodrigues, Cláudia Gianini Mônico, Tânia Afonso, Edgar Bezerra Lira Filho, Marco Perin, Cláudio Henrique Fischer, Samira Saady Morhy
Hospital Israelita Albert Einstein, São Paulo, SP - Brazil

Abstract

Background: Left ventricular remodeling (LVR) after AMI characterizes a factor of poor prognosis. There is little information in the literature on the LVR analyzed with three-dimensional echocardiography (3D ECHO).

Objective: To analyze, with 3D ECHO, the geometric and volumetric modifications of the left ventricle (VE) six months after AMI in patients subjected to percutaneous primary treatment.

Methods: Prospective study with 3D ECHO of 21 subjects (16 men, 56 ± 12 years-old), affected by AMI with ST segment elevation. The morphological and functional analysis (LV) with 3D ECHO (volumes, LVEF, 3D sphericity index) was carried out up to seven days and six months after the AMI. The LVR was considered for increase $> 15\%$ of the end diastolic volume of the LV (LVEDV) six months after the AMI, compared to the LVEDV up to seven days from the event.

Results: Eight (38%) patients have presented LVR. Echocardiographic measurements ($n = 21$ patients): I- up to seven days after the AMI: 1- LVEDV: 92.3 ± 22.3 mL; 2- LVEF: 0.51 ± 0.01 ; 3- sphericity index: 0.38 ± 0.05 ; II- after six months: 1- LVEDV: 107.3 ± 26.8 mL; 2- LVEF: 0.59 ± 0.01 ; 3- sphericity index: 0.31 ± 0.05 . Correlation coefficient (r) between the sphericity index up to seven days after the AMI and the LVEDV at six months ($n = 8$) after the AMI: $r: 0.74, p = 0.0007$; (r) between the sphericity index six months after the AMI and the LVEDV at six months after the AMI: $r: 0.85, p < 0.0001$.

Conclusion: In this series, LVR has been observed in 38% of the patients six months after the AMI. The three-dimensional sphericity index has been associated to the occurrence of LVR. (Arq Bras Cardiol. 2013;101(1):43-51)

Keywords: Echocardiography, Three-Dimensional; Myocardial Infarction; Stents; Angioplasty, Balloon, Coronary; Ventricular Function, Left.

Introduction

The prognosis of the patients bearing acute myocardial infarction (AMI) with ST segment elevation is related to the cardiac mechanics, and to the geometry of the left ventricle (LV) as well¹⁻⁵. The percentage of dilatation of the LV (ventricular remodeling) and the myocardial performance mirrored by the variation of the ventricular volumes (ejection fraction) are aspects of great prognostic importance in the clinical evolution of the patients after AMI¹⁻⁵.

The analysis of the volumes, of the geometry, and of the left ventricular function has been carried out over the past decades with the use of the two-dimensional echocardiogram / echocardiography (2D ECHO). However, this method presents limitations related to the morphological

and functional analysis of the cardiac structures by virtue of the limitation of the spatial planes of observation, of the geometric inferences for the calculation of the ventricular volumes and of the possibility of shortening - "foreshortening" - of the geometric forms upon the rendering of the echocardiographic images⁶⁻¹¹. In that sense, the three-dimensional echocardiogram (3D ECHO) has been developed - which allows for the structural analysis of the heart from multiple spatial planes of observation. The three-dimensional echocardiographic analysis of the left ventricle, when compared to the two-dimensional analysis, presents a finer proximity with the measurements obtained with methods of a better spatial resolution, such as the 64-channel ultra-rapid computed tomography and the nuclear magnetic resonance^{8,12-14}.

The three-dimensional echocardiography also provides for the analysis of the geometric modification of the left ventricle through the gauging of the three-dimensional sphericity index (3D SI)^{2,15}. This new index relates the ventricular volume to the hypothetical left ventricular volume should the LV present a spherical shape. A number of studies in the literature have related this new index of ventricular geometric analysis to the left ventricular remodeling after myocardial infarction^{2,15}.

Mailing address: Marcelo Luiz Campos Vieira •

Rua Cardoso de Melo, 463, Apto 21, Vila Olímpia. Postal Code 04548-060, São Paulo, SP - Brazil

E-mail: mlvieira@cardiol.br, mluz766@terra.com.br

DOI: 10.5935/abc.20130112

Objective

The purpose of the study has been that of analyzing - with the 3D ECHO - the geometric and volumetric modifications of the LV six months after AMI in patients subjected to percutaneous primary treatment by implantation of coronary endoprosthesis (Stent).

Method

Population

Criteria of inclusion and of exclusion

The patient was eligible for the study after evaluation by the assistant doctor of the emergency services, having presented at least two of the following criteria for the diagnosis of myocardial infarction:

- 1 - clinical picture that is compatible with AMI;
- 2 - elevation of the ST segment > 1mm in at least two derivations upon ECG of 12 derivations;
- 3 - dosage of markers of myocardial necrosis compatible with AMI;

Apart from the criteria for the diagnosis of AMI, the patient should present:

- 1- Realization of primary percutaneous coronary treatment with a 'door-to-balloon' time of up to 90 minutes;
- 2- Hemodynamic stability upon realization of the percutaneous coronary intervention;
- 3- Signing of the free informed consent form for the realization of the study.

As criteria of exclusion from the study, there had been observed:

Image deemed to be inadequate upon the three-dimensional echocardiographic analysis;

Presence of great irregularity of the cardiac rhythm prior to percutaneous intervention (i. e.: atrial fibrillation, as a result of the difficulty upon the three-dimensional echocardiographic analysis).

The patients have been analyzed for the evidence of systemic arterial hypertension, diabetes mellitus, dyslipidemia, smoking, family history of coronary artery disease, in accordance with previously established criteria¹⁶⁻²⁰.

Echocardiography

The two-dimensional echocardiographic analysis - with conventional and tissue Doppler - and the real-time trans thoracic three-dimensional analysis have been performed. The two-dimensional echocardiographic exams were carried out in accordance with the recommendations of the American Society of Echocardiography^{21,22}, in commercially available equipment (Philips IE33, Philips Medical System, Andover, MA, USA), equipped with transducer of 2-5 MHz, and X3 matrix transducer for the rendering of the three-dimensional images. The software used for the analysis of the three-dimensional

echocardiographic imagery was Q-Lab, version 5.0, Philips Medical System, Andover, MA, USA. The following echocardiographic parameters have been studied:

I - Two-dimensional echocardiogram:

End diastolic volume of the left ventricle (LVEDV); 2- End systolic volume of the left ventricle (LVESV); 3- Ejection fraction of the left ventricle (LVEF), Simpson's rule method.

1 - The left ventricular diameters have been measured by using the one-dimensional mode guided by the two-dimensional echocardiography.

2 - The two-dimensional sphericity index of the left ventricle has also been calculated, taking in consideration the relation between the long and short axes of the left ventricle (apical four chamber projection, in diastole)²³, and the segmental contractility index of the left ventricle, considering the model of 17 ventricular segments.

II- Three-dimensional echocardiography:

1 - LVEDV; 2- LVESV; 3- LVEF (Picture 1); 4- index of three-dimensional left ventricular dyssynchrony % (3D DI); 5- 3D SI (Picture 2). O three-dimensional dyssynchrony index corresponds to the standard deviation % of the average of the end systolic contraction time of the segments of the left ventricle, for a mathematical model of 17 segments of the left ventricle.

2 - The three-dimensional sphericity index of the left ventricle corresponds to the ratio between the LVEDV and the volume which the left ventricle would present had its shape been spherical, in accordance with the expression below:

Three-dimensional sphericity index of the LV: $LVEDV \frac{4}{3} \pi (D/2)^3$ where, LVEDV: end diastolic volume of the left ventricle (measured with 3D ECHO);

D: diameter of the left ventricle measured in the apical four chamber projection.

The acquisition of the three-dimensional images has been carried out after the two-dimensional echocardiographic study. The three-dimensional images have been obtained with the use of a matrix transducer - the patient being in expiratory apnea - with the image attached to the electrocardiographic record. The three-dimensional echocardiographic images have been acquired from reference points of the left ventricle, whilst taking in consideration the mitral valve ring and the ventricular apex, in sagittal and coronal projections. The reference points of the mitral valve ring have observed specific points of the mitral valve ring, whilst considering the confluence of the ring with the septum, the lateral wall, the lower wall, and the anterior wall of the left ventricle. The greatest density possible of echocardiographic lines has been considered for the outlining of the volumetric elements (voxels) during the acquisition of the images. The images have been stored in the hard disc of the echocardiographic equipment and analyzed "off-line", in specific software of the very device. The analyses have been carried out by two independent observers (MLCV and WAO).

The left ventricular remodeling (LVR) has been considered upon the occurrence of increase $\geq 15\%$ of the LVEDV six months after the AMI, as compared to the LVEDV up to seven days after the event²⁴.

Original Article

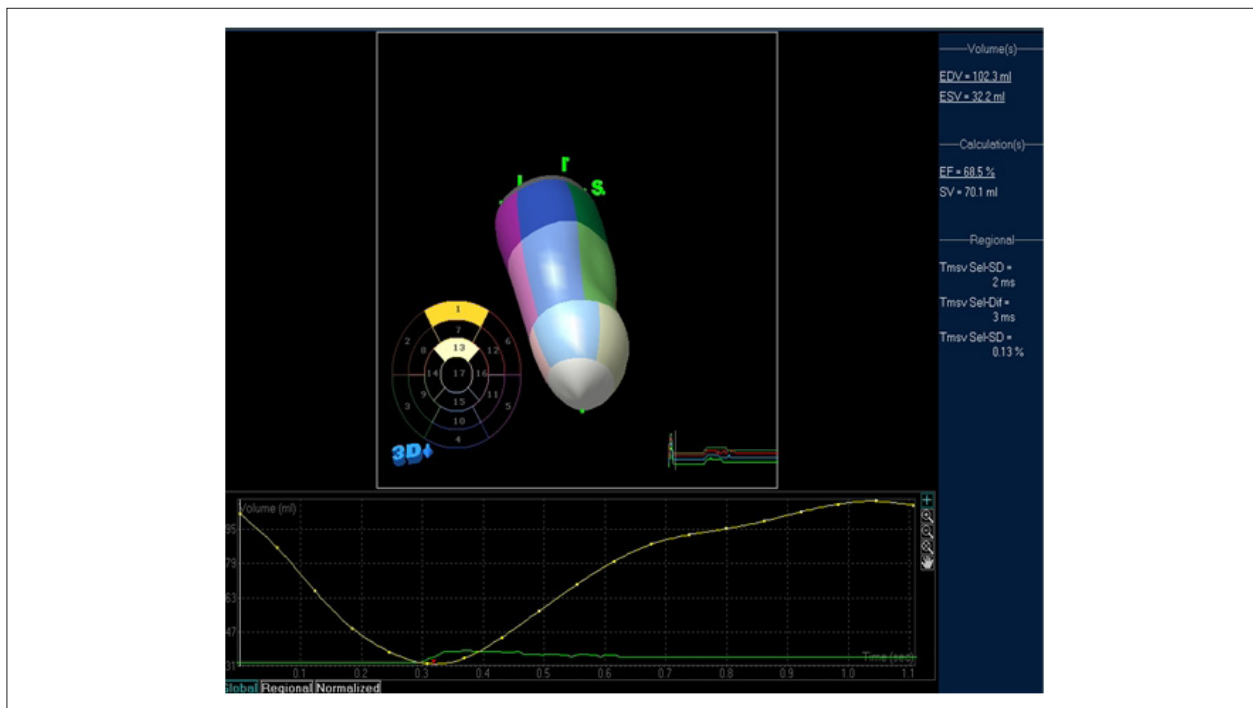


Figure 1 - Measurement of the ventricular volumes and of the ejection fraction of the left ventricle measured with the use of three-dimensional trans thoracic echocardiography; EDV (end diastolic volume): 102.3 mL; ESV (end systolic volume): 32.2 mL; EF (ejection fraction): 68.5%; SV (ejected systolic volume): 70.1 mL.

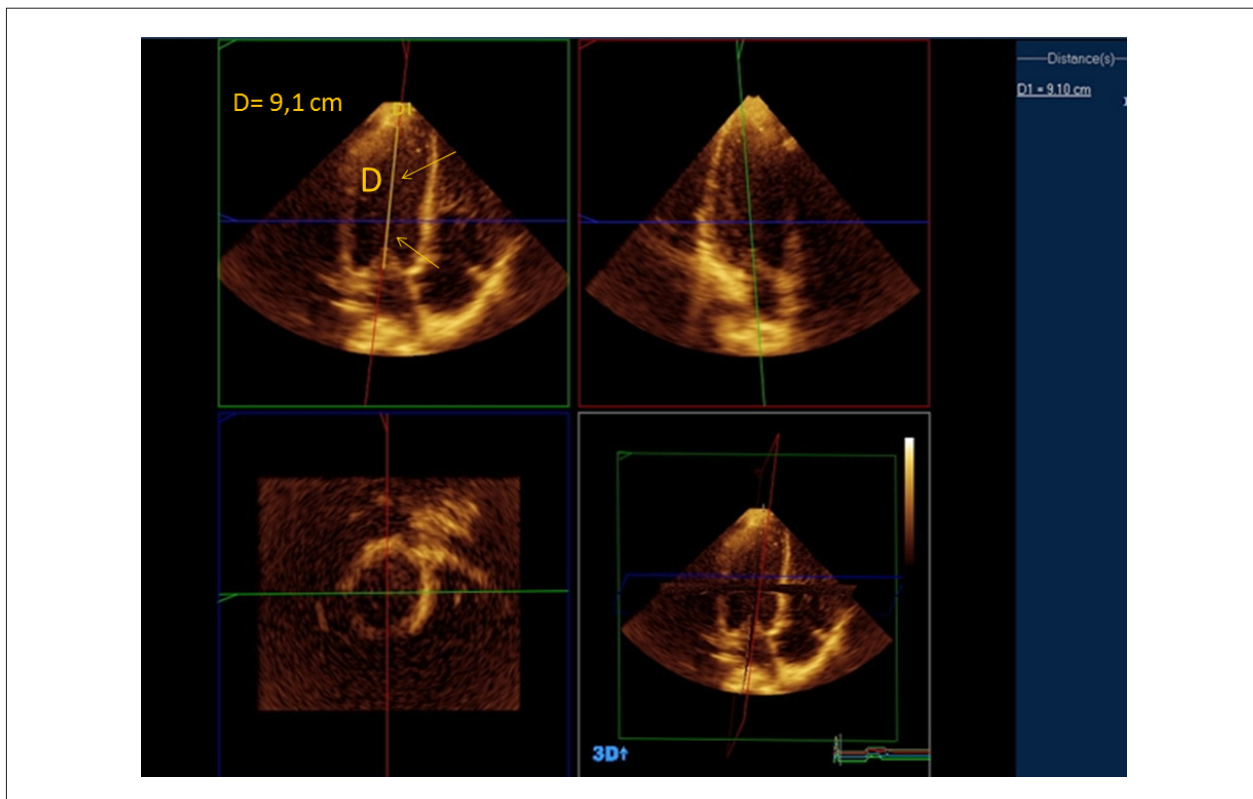


Figure 2 - Demonstration of the measurement of the three-dimensional sphericity index (3D SI): 0.26, in accordance with: $3D\ SI = LVEDV / 4/3 \pi (D/2)^3$, for LVEDV: 102.3 mL (Picture 1); (D): 9.1 cm; Arrows: demonstration of the longitudinal diameter of the ventricle in apical four chamber projection.

The first echocardiographic exam (two-dimensional and three-dimensional) has been carried out within up to seven days after the AMI and the second exam, six months after the AMI.

Laboratory analysis

Serum markers of myocardial necrosis (whilst considering their highest values during the progression of the AMI) and of the atrial natriuretic peptide (BNP) have been studied. Thus, there have been analyzed:

- 1 - Creatine kinase (CK) MB fraction and CK-MB mass;
- 2 - Myoglobin;
- 3 - Troponin I;
- 4 - BNP.

Statistical analysis

The statistical analysis of the quantitative variables has been carried out through the description of the minimum and maximum values, and of the calculation of the standard deviations and averages. In relation to the qualitative variables, the absolute and relative frequencies have been calculated. The analysis of correlation between the biochemical findings and the two-dimensional and three-dimensional echocardiographic findings has been carried out by using the Pearson's correlation method (r), 95% of confidence interval. The intra- and the inter-observer variations have been calculated for the three-dimensional parameters measured, $p < 0.05$. The data have been processed with the MedCalc system of statistical analysis, Mariakerke, Belgium.

This study has been approved by the Research Ethics Committee of the *Hospital Israelita Albert Einstein*, São Paulo, Brazil, and registered in the *Instituto Israelita de Ensino e Pesquisa Albert Einstein - IIEPAE* [The Albert Einstein Israeli Institute of Education and Research], under the number 293-07.

Results

Within the period between March, 2007 and December, 2008, 23 patients have been studied in a prospective fashion, with the later exclusion of 2/23 (8.7%) patients from the initial series as a result of image deemed as inadequate upon the echocardiographic analysis. Thus, out of the 21 patients considered for the study, 16 (76%) men, with a mean age range of 56 ± 12 (41-87) years, which have been affected by Acute Myocardial Infarction with elevation of the ST segment, have received treatment by primary percutaneous coronary intervention (implantation of coronary endoprosthesis - *Stent*).

The demographic and clinical characteristics, the hemodynamic findings - before and after the primary percutaneous treatment - of the population studied are demonstrated in the Table 1. The majority of the patients of the study presented a previous history of systemic arterial hypertension (52%), and close to $\frac{1}{4}$ of them presented diabetes mellitus, or a history of dyslipidemia

or of smoking. The occurrence of a family history of atherosclerotic disease has also been expressive (43%). The patients have presented clinical evolution in group I of Killip and Kimball: 18/21 (86%); or in group II: 3/21 (14%), during the period of hospitalization.

The two-dimensional and three-dimensional echocardiographic measurements, and the serum dosages of enzymatic markers and of BNP from the group of patients who has presented reverse remodeling of the left ventricle ($n = 8$ patients) and from the group of patients who has not presented reverse remodeling ($n = 13$) are demonstrated in the Table 2. The progression of the LVEDV of the total population of the study ($n = 21$) six months after the AMI is demonstrated in the Chart 1. In the group of patients with remodeling of the left ventricle, we have observed an increase of 15.7%, $p < 0.05$, of the LVEDV (analysis with 3D ECHO), and of 9.5% of the LVEDV with a two-dimensional echocardiographic analysis, six months after the myocardial infarction. In the group of patients with no remodeling of the left ventricle, we have observed an increase of 6.1% in the LVEDV (analysis with 3D ECHO), and of 9.6% in the LVEDV with a two-dimensional echocardiographic analysis, six months after the myocardial infarction. The patients ($n = 21$) have presented a diastolic standard of alteration of the ventricular relaxation ($n = 7$) and pseudonormal flow ($n = 4$) up to seven days after the AMI, and diastolic standard of alteration of the ventricular relaxation ($n = 8$) and pseudonormal flow ($n = 2$) six months after the AMI. No association between the diastolic dysfunction and the LVR has been made evident. Likewise, no association has been observed between the sphericity index 2D, the segmental contractility index of the left ventricle, and the ventricular remodeling 6 months after the AMI. The average time for realization of the first echocardiographic exam (two-dimensional and three-dimensional) after the AMI has been 2 ± 0.4 days.

The variation of the three-dimensional sphericity index (3D) of the left ventricle up to seven days and six months (6M) after the myocardial infarction for the total population of the study ($n = 21$) is demonstrated in the Chart 2. The analysis of correlation (Pearson: r) between the three-dimensional sphericity index (3D) and the end diastolic volumes of the left ventricle (LVEDV), up to seven days and six months (6M) after the myocardial infarction (AMI), in the total population of the study ($n = 21$), is demonstrated in the Table 3. Remodeling of the left ventricle has been observed in 38% of the patients affected by AMI. The correlation between the 3D sphericity index measured up to seven days after the AMI and the LVEDV within six months has been 0.69, $p = 0.007$. For the group of patients with reverse remodeling of the LV, the correlation between the 3D sphericity index measured up to seven days after the AMI and the LVEDV within six months has been 0.74, $p = 0.001$. For the group of patients with reverse remodeling of the LV, the correlation between the 3D sphericity index measured within six months after the AMI and the LVEDV within six months has been 0.85, $p = 0.001$. For the group of patients with no reverse remodeling of the LV, the

Table 1 - Demographic, clinical, and angiographic characteristics before and after percutaneous coronary procedure, and factors of risk for coronary artery disease of the total population from the study (n = 21), of the patients who have presented remodeling of the left ventricle (n = 8), and of the patients who have not presented remodeling of the left ventricle (n = 13) after myocardial infarction

| Characteristics | Group Total (n = 21) | Patients with Remodeling (n = 8) | Patients with no Remodeling (n = 13) |
|---|--|---|--|
| Age (years) | 56 ± 12 (41 - 87) | 55 ± 12 (41 - 83) | 54 ± 12 (42 - 87) |
| Gender (M/F) | 16/5 | 5/3 | 11/2 |
| Smoking | 6 (28.5%) | 2 (25%) | 4 (31%) |
| Diabetes Mellitus | 5 (24%) | 2 (25%) | 3 (23%) |
| SAH | 11 (52%) | 4 (50%) | 7 (53%) |
| previous CAD | 4 (19%) | 2 (25%) | 2 (15%)* |
| Dyslipidemia | 6 (28.6 %) | 3 (37%) | 3 (23%)* |
| Family history - CAD | 9 (43%) | 3 (37%) | 6 (46%) |
| Involved Coronary Artery (%) | DA: 11 cases (52%) CX: 6 cases(28%) RC: 4 cases (19%) | DA: 4 cases (50%) CX: 2 cases (25%) RC: 2 cases (25%) | DA: 7 cases (53%) CX: 3 cases (23%) RC: 3 cases (23%) |
| Secondary Coronary Lesion | DA: 6 cases (29%) Diagonal: 3 cases (14 %) CX: 2 cases(9.5%) | DA: 2 cases (25%) CX: 2 cases (25%) - | DA: 3 cases (23%) CX: 3 cases (23%) - |
| AMI - | | | |
| Anterior Localization | 11 cases (52%) | 4 cases (50%) | 7 cases (53%) |
| Anterolateral | 1 case (4.7%) | - | 1 case (7.7%) |
| Inferior | 4 cases (19%) | 2 cases (25%) | 2 cases (15.4%) |
| Inferolateral | 3 cases (14%) | 2 cases (25%) | 1 case (7.7%) |
| Lateral | 2 cases (9.5%) | - | 2 cases (15.4 %) |
| % of Obstruction of the involved coronary artery Pre-procedure | 100%: 17 cases (81%) 95%: 3 cases (14%) 99%: 1 case (4.7%) | 100%: 6 cases (75%) 95%: 1 case (25%) 99%: 1 case (25%) | 100%: 10 cases (77%) 95%: 1 case (7.7%) 99%: 2 cases (15.4%) |
| % of Obstruction of the involved coronary artery Post-procedure | 0% : 16 cases (76%) 10%: 4 cases (19%) 20%: 1 case (4.7%) | 0%: 6 cases (75%) 10%: 2 cases (25%) - | 0%: 10 cases (77%) 10%: 3 cases (23%) |
| TIMI flow of the involved coronary artery Pre-procedure | TIMI 0: 18 cases (86%) TIMI 2: 3 cases (14%) | TIMI 0: 7 cases (87.25%) TIMI 2: 1 case (13%) | TIMI 0: 11 cases (85%) TIMI 2: 2 cases (15.4%) |
| TIMI flow of the treated coronary artery Post-procedure | TIMI 3: 21 cases (100%) | 8 cases (100%) | 13 cases (100%) |

M: male; SAH: Systemic Arterial Hypertension; F: female; CAD: coronary artery disease; N: normal; DA: anterior descending artery (anterior interventricular); CX: circumflex artery; RC: right coronary artery; AMI: Acute Myocardial Infarction. *p < 0.05 (difference between the patients who have presented remodeling and between the patients who have not presented remodeling after myocardial infarction).

correlation between the 3D sphericity index measured up to seven days after the AMI and the LVEDV within six months has been 0.54, p = 0.001. There has been no association between the serum markers of myocardial necrosis and the occurrence of left ventricular remodeling. No association has been observed between the index of three-dimensional ventricular dyssynchrony and the left ventricular remodeling.

The coefficient of intra-observer variation for the measuring of the LVEDV with 3D ECHO has been 0.94 (CI 95%: 0.81-0.97); the coefficient of inter-observer variation for the measuring of the LVEDV with 3D ECHO has been 0.92 (CI 95%: 0.80-0.96). The coefficient of intra-observer variation for the measuring of the 3D SI has been 0.93 (CI 95%: 0.80-0.95), and

the coefficient of inter-observer variation for the measuring of the 3D SI has been 0.91(CI 95%: 0.77-0.94).

Discussion

The left ventricular remodeling after the occurrence of AMI reflects the mechanical modifications of adaptation of the LV in the face of the ischemic event, being a factor of important prognosis in the clinical evolution of the patients¹⁻⁵. The left ventricular dilatation, as well as the reduction in the ejection fraction of the LV, the serum levels of BNP and the functional class represent important factors of poor prognosis related to the heart failure after AMI.

Table 2 - Echocardiographic measurements and serum dosages of enzymatic markers and of BNP of the patients who have presented remodeling of the left ventricle (n = 8), and of the patients who have not presented remodeling of the left ventricle (n = 13), 6 months after myocardial infarction

| Parameters | 1 st ECHO up to 7 days after AMI Ventricular remodeling group (n = 8) | 2 nd ECHO 6M after AMI Ventricular remodeling group (n = 8) | 1 st ECHO up to 7 days after AMI Group With no Ventricular remodeling (n = 13) | 2 nd ECHO 6M after AMI Group With no Ventricular remodeling (n = 13) |
|-----------------------------------|--|--|---|---|
| 3D ECHO LVEF | 0.49 ± 0.02 (0.35 - 0.65) | 0.57 ± 0.01 (0.37 - 0.71) | 0.52 ± 0.01 (0.36 - 0.69) | 0.60 ± 0.01 (0.41 - 0.71) |
| 3D ECHO LVESV (mL) | 44.5 ± 8.4 (31.2 - 58.3) | 46.4 ± 8.3 (32.8 - 58.3) | 42.5 ± 7.7 (29.6 - 57.3) | 44.7 ± 6.3 (30.8 - 56.3) |
| 3D ECHO LVEDV (mL) | 94.3 ± 23.6 (74.5 - 103.7) | 109.1 ± 23.2* (75.3 - 120.1) | 91.3 ± 21.6 (72.5 - 111.1) | 97.4 ± 18.8 (75.3 - 116.3) |
| 3D ECHO 17 ID % NV (< 5%) | 6.71 ± 4.32 (0.59 - 14.6) | 4.11 ± 1.31 (0.55 - 6.2) | 3.31 ± 0.95 (0.51 - 6.2) | 3.01 ± 0.76 (0.53 - 4.2) |
| 3D sphericity index | 0.40 ± 0.05* (0.28 - 0.43) | 0.35 ± 0.05* (0.25 - 0.37) | 0.30 ± 0.05 (0.26 - 0.30) | 0.27 ± 0.05 (0.22 - 0.29) |
| 2D ECHO LVDD (cm) | 5.0 ± 0.2 (4.5 - 6) | 5.2 ± 0.1 (4.8 - 6.2) | 4.7 ± 0.1 (4.5 - 5.3) | 5.0 ± 0.1 (4.7 - 6.0) |
| 2D ECHO LVEF (Simpson) | 0.51 ± 0.05 (0.40 - 0.64) | 0.59 ± 0.06 (0.41 - 0.65) | 0.54 ± 0.04 (0.41 - 0.70) | 0.62 ± 0.03 (0.41 - 0.72) |
| 2D ECHO LVESV (mL) | 49.1 ± 16.2 (19.6 - 42.2) | 49.8 ± 18.3 (22.6 - 44.6) | 47.6 ± 18.45 (19.6 - 39.3) | 47.5 ± 17.4 (21.6 - 42.9) |
| 2D ECHO LVEDV (mL) | 105.7 ± 21.3 (58.9 - 104.6) | 115.8 ± 20.9 (58.7 - 129.1) | 102.4 ± 21.7 (57.6 - 103.2) | 112.3 ± 23.1 (56.4 - 123.8) |
| Sphericity index - 2D | 1.77 ± 0.13 | 1.83 ± 0.11 | 1.78 ± 0.12 | 1.86 ± 0.10 |
| Contractility score - LV (NV = 1) | 1.30 ± 0.12 | 1.24 ± 0.11 | 1.26 ± 0.15 | 1.20 ± 0.13 |
| Troponin I (ng/mL) NV (0 - 0.04) | 12.3 ± 8.61 (2.70 - 33.3) | - | 11.7 ± 9.56 (2.30 - 31.8) | - |
| CKMB (ng/mL) NV (0 - 3.40) | 92.1 ± 77.8 (5.9 - 256) | - | 90.6 ± 76.4 (5.5 - 256) | - |
| Myoglobin (ng/mL) NV (0 - 62.5) | 583.5 ± 227.6 (109 - 880) | - | 569.8 ± 219.6 (104 - 880) | - |
| BNP (pg/mL) NV (5 - 100) | 269.8 ± 121 (29 - 1054) | - | 263.9 ± 120 (23 - 1054) | - |

ECHO: Echocardiogram; LVEF: ejection fraction of the left ventricle; LVESV: end systolic volume of the left ventricle; LVEDV: end diastolic volume of the left ventricle; ID: index of dyssynchrony; LVDD: diastolic diameter of the left ventricle; NV: normal value; ID: index of dyssynchrony of 17 segments of the left ventricle; 3D sphericity index: Three-dimensional sphericity index. *p < 0.05 (difference between the patients who have presented remodeling and between the patients who have not presented remodeling after myocardial infarction).

In the present study, 38% of the patients have presented pieces of echocardiographic evidence of ventricular remodeling, in spite of their presenting a small reduction of the LVEF within the hospitalization period (0.49 ± 0.02 upon 3D ECHO, 0.51 ± 0.05 upon 2D ECHO), of the evidence of discrete elevation of the BNP (269 ± 121 pg / mL), and of their all being within a class I or II of Killip and Kimball. This percentage of left ventricular remodeling has been similar to the findings of a study with 33 patients in which the three-dimensional echocardiographic analysis has identified LVR in 13 (39%) of the patients studied².

It has also been verified that the LVR would not have been diagnosed should the volumetric analysis had been carried out with the use of the two-dimensional echocardiography (we have observed an average increase of 9.5% in the LVEDV with the two-dimensional echocardiographic analysis). The possibility of an early detection of the left ventricular remodeling

takes on importance in the sense of a more aggressive pharmacological treatment for the prevention of the progression of the ventricular dilatation. In the intra-hospital analysis of 23 patients affected by AMI (the 21 patients of the current study were a part of this series), we have also observed a greater association between the serum release of BNP and the ejection fraction of the left ventricle measured with the 3D ECHO when compared to the two-dimensional echocardiography (r: - 0.7427, p < 0.0001; - 0.5478, p = 0.001, respectively)²⁵. Then, it is observed a greater association between the three-dimensional echocardiographic analysis and the cellular events (mirrored by the serum release of BNP) and the morphological and functional effect of the infarction in the left ventricle (demonstrated by the LVEF and by the ventricular remodeling), when compared to the two-dimensional echocardiographic analysis.

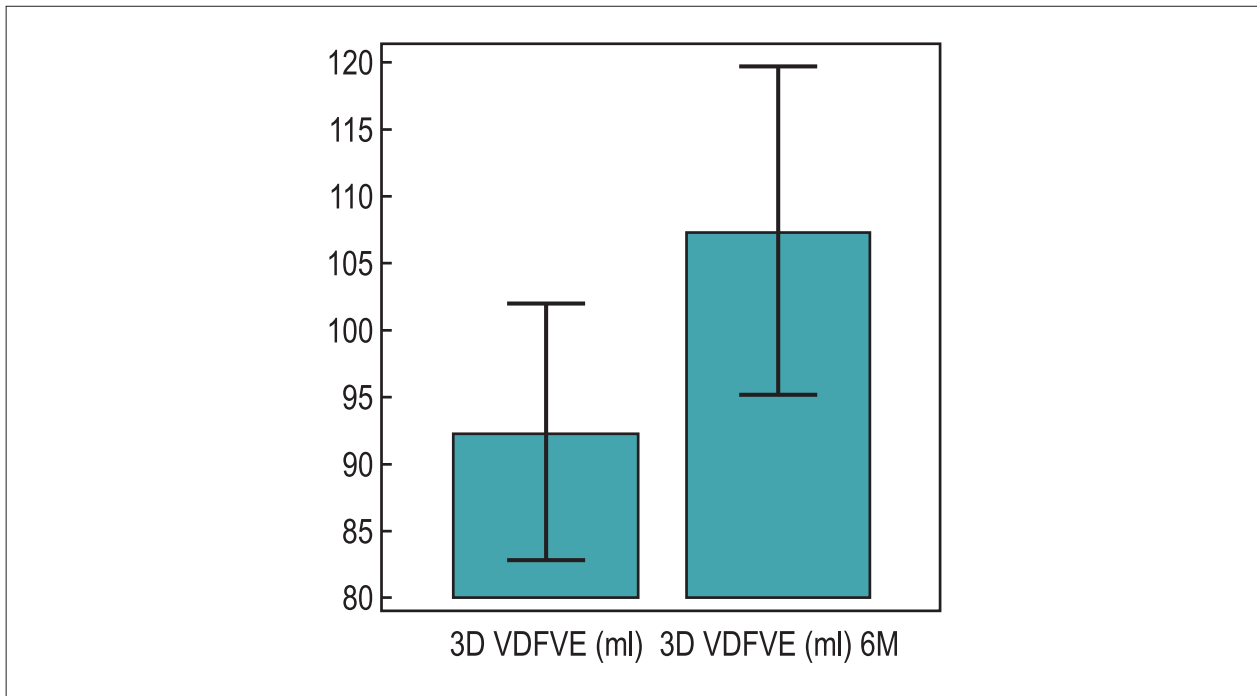


Chart 1 - Histogram for the demonstration of the end diastolic volumes of the left ventricle measured with three-dimensional echocardiography (LVEDV) up to seven days and six months (6M) after the myocardial infarction of the total population of the study (n = 21); 3D LVEDV: 92.3 ± 22.3 mL; 3D LVEDV 6M: 107.3 ± 26.8 mL.

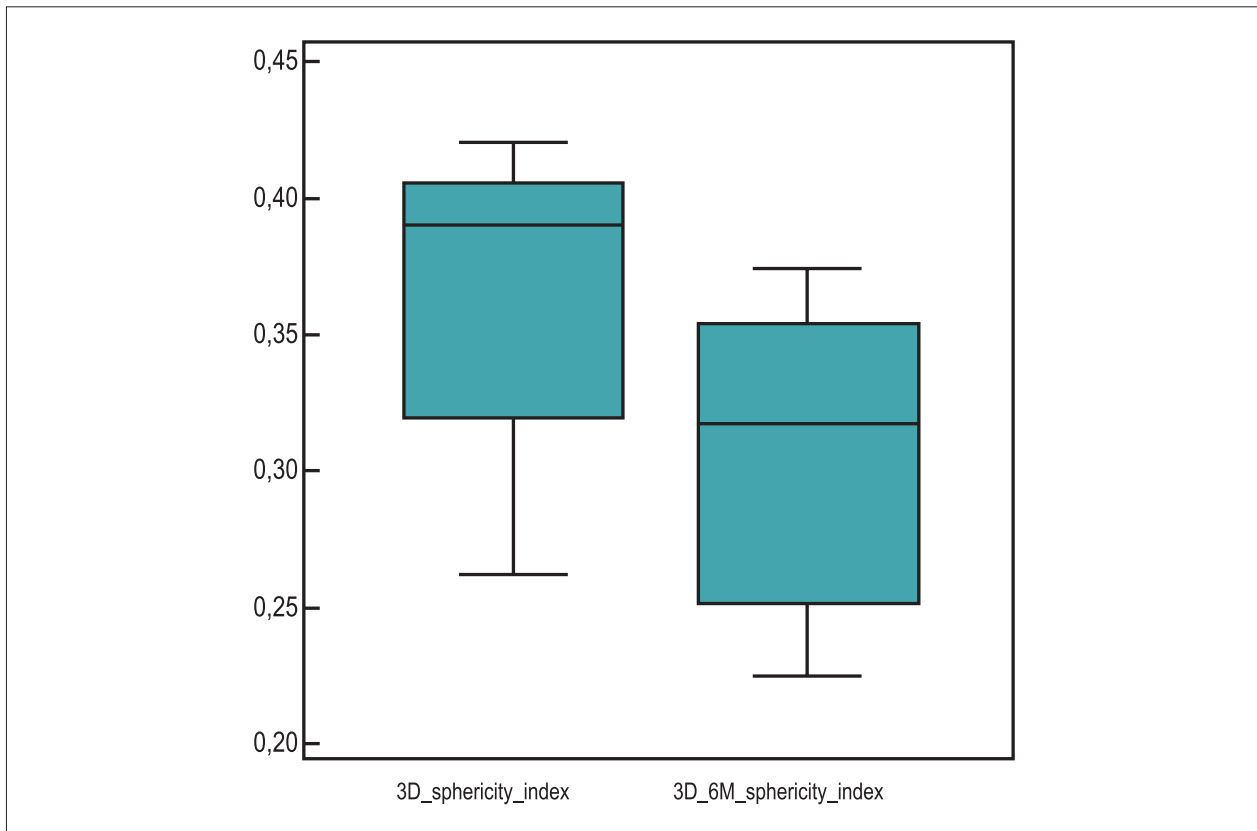


Chart 2 - Demonstration in Box-Plot of the three-dimensional sphericity index (3D) of the left ventricle up to seven days and six months (6M) after the myocardial infarction of the total population of the study (n = 21); 3D sphericity index: 0.38 ± 0.05; 3D sphericity index: 0.31 ± 0.05.

Table 3 - Correlation (Pearson: r), Confidence interval (CI) 95%, between the three-dimensional sphericity index (3D) and the end diastolic volumes of the left ventricle (LVEDV), up to seven days and six months (6M) after the myocardial infarction (AMI) in the total population of the study (n = 21)

| Parameter | 3D ECHO LVEDV | 3D ECHO LVEDV 6M |
|--|-------------------------------|-------------------------------|
| 3D sphericity index up to 7 days after the AMI | r: 0.79 | r: 0.69 |
| CI | 0.5539 - 0.9134 p < 0.0001 | 0.3611 - 0.8690 p = 0.0007 |
| 3D sphericity index 6M | - | - |
| | - | r: 0.83 |
| | - | 0.6147 - 0.9312 |
| | - | p < 0.0001 |

3D sphericity index: Three-dimensional sphericity index up to seven days after the myocardial infarction; 3D sphericity index 6M: Three-dimensional sphericity index six months after the myocardial infarction; 3D ECHO LVEDV: end diastolic volume of the left ventricle up to seven days after the myocardial infarction; 3D ECHO LVEDV 6M: end diastolic volume of the left ventricle six months after the myocardial infarction.

In relation to the new three-dimensional echocardiographic indices meant for the study of the function and of the geometry of the left ventricle (index of three-dimensional synchrony and three-dimensional sphericity index), a diverse behavior has been observed in relation to the left ventricular remodeling within six months after the AMI. No association has been detected between the index of ventricular dyssynchrony (which could represent the left intraventricular electromechanical decoupling) and the left ventricular remodeling. However, it has been verified the association between the three-dimensional sphericity index and the LVR, in a similar fashion in two previous studies with 19 and 33 patients affected by AMI^{2,15}. In the study with 33 patients, it has been demonstrated that values above 0.25 for the three-dimensional sphericity index would present a sensibility of 100%, a specificity of 90%, a positive predictive value of 87%, and a negative predictive value of 100%, for the forecast of RVE². In the present study, in the group of patients with remodeling of the LV, the correlation (r) between the 3D sphericity index measured up to seven days after the AMI and the LVEDV in six months has been 0.74, p = 0.001. The time difference between the two studies is related to the observation period after the AMI – in the study with 33 patients, the analysis has been carried out 12 months after the event and, in our study, the analysis has been made after six months.

Thus, with the progression of the development and of a more uneventful use of the three-dimensional echocardiographic analysis, it is believed that this technique of imagery might replace the two-dimensional echocardiographic investigation in the clinical follow-up of the patients affected by myocardial infarction.

Limitation of the study

The number of patients studied has been small, thus calling for other analyses with a larger number of patients. There is still a need for the presence of echocardiographic imagery deemed to be good in order for the three-dimensional echocardiographic analysis to be carried out (two patients, 8.7% of the initial series, have been excluded from the study). Patients affected

by myocardial infarction in different ventricular segments have been studied (involvement of different vascular beds), which may have provoked the heterogeneity and non uniformity in the data obtained for the analysis. The temporal aspect is important for the morphological and functional alterations of the left ventricle. The study shall be repeated in a longer period (12 and 24 months) after the ischemic event.

Conclusion

In this series of patients affected by Acute Myocardial Infarction with ST segment elevation, treated by percutaneous approach, the remodeling of the left ventricle has been observed in 38% of the patients affected by AMI. The three-dimensional sphericity index has been associated to the occurrence of remodeling of the left ventricle.

Author contributions

Conception and design of the research: Vieira MLC, Oliveira WA, Rodrigues ACT, Mônico CG, Afonso T; Acquisition of data: Vieira MLC, Oliveira WA, Cordovil A, Rodrigues ACT, Mônico CG, Lira Filho EB, Perin M, Fischer CH, Morhy SS; Analysis and interpretation of the data: Vieira MLC, Oliveira WA, Cordovil A, Rodrigues ACT, Mônico CG, Afonso T, Lira Filho EB, Perin M, Fischer CH, Morhy SS; Statistical analysis: Vieira MLC; Writing of the manuscript: Vieira MLC, Oliveira WA, Rodrigues ACT, Mônico CG; Critical revision of the manuscript for intellectual content: Vieira MLC, Oliveira WA, Cordovil A, Afonso T.

Potential Conflict of Interest

No potential conflict of interest relevant to this article was reported.

Sources of Funding

There were no external funding sources for this study.

Study Association

This study is not associated with any post-graduation program.

References

1. Kapetanakis S, Kearney MT, Siva A, Gall N, Cooklin M, Monaghan MJ. Real-time three-dimensional echocardiography: a novel technique to quantify global left ventricular mechanical dyssynchrony. *Circulation*. 2005;112(7):992-1000.
2. Mannaerts HF, van der Heide JA, Kamp O, Stoel MG, Twisk J, Visser CA. Early identification of left ventricular remodelling after myocardial infarction, assessed by transthoracic 3D echocardiography. *Eur Heart J*. 2004;25(8):680-7.
3. Korup E, Dalsgaard D, Nyvad O, Jensen TM, Toft E, Berning J. Comparison of degrees of left ventricular dilation within three hours and up to six days after onset of first acute myocardial infarction. *Am J Cardiol*. 1997;80(4):449-53.
4. Erlebacher JA, Weiss JL, Eaton LW, Kallman C, Weisfeldt ML, Bulkley BH. Late effects of acute infarct dilation on heart size: a two dimensional echocardiographic study. *Am J Cardiol*. 1982;49(5):1120-6.
5. Sharpe N, Smith H, Murphy J, Greaves S, Hart H, Gamble G. Early prevention of left ventricular dysfunction after myocardial infarction with angiotensin-converting-enzyme inhibition. *Lancet*. 1991;337(8746):872-6.
6. Ahmad M. Real-time three-dimensional echocardiography in assessment of heart disease. *Echocardiography*. 2001;18(1):73-7.
7. Hotta VT, Martinelli Filho M, Mady C, Mathias W Jr, Vieira ML. Comparison between 2D and 3D echocardiography in the evaluation of reverse remodeling after CRT. *Arq Bras Cardiol*. 2011;97(2):111-21.
8. Vieira ML, Nomura CH, Tranchesi B Jr, de Oliveira WA, Naccarato G, Serpa BS, et al. Real-time three-dimensional echocardiographic left ventricular systolic assessment: side-by-side comparison with 64-slice multi-detector cardiac computed tomography. *Eur J Echocardiogr*. 2010;11(3):257-63.
9. Gimenes VM, Vieira ML, Andrade MM, Pinheiro J Jr, Hotta VT, Mathias W Jr. Standard values for real-time transthoracic three-dimensional echocardiographic dyssynchrony indexes in a normal population. *J Am Soc Echocardiogr*. 2008;21(11):1229-35.
10. Endo Y, Maddukuri PV, Vieira ML, Pandian NG, Patel AR. Quantification of right ventricular volumes and function by real time three-dimensional echocardiographic longitudinal axial plane method: validation in the clinical setting. *Echocardiography*. 2006;23(10):853-9.
11. Oliveira W, Campos O, Cintra F, Matos L, Vieira ML, Rollim B, et al. Impact of continuous positive airway pressure treatment on left atrial volume and function in patients with obstructive sleep apnoea assessed by real-time three-dimensional echocardiography. *Heart*. 2009;95(22):1872-8.
12. Mannaerts HF, Van Der Heide JA, Kamp O, Papavassiliu T, Marcus JT, Beek A, et al. Quantification of left ventricular volumes and ejection fraction using freehand transthoracic three-dimensional echocardiography: comparison with magnetic resonance imaging. *J Am Soc Echocardiogr*. 2003;16(2):101-9.
13. Qi X, Cogar B, Hsiung MC, Nanda NC, Miller AP, Yelamanchili P, et al. Live/real time three-dimensional transthoracic echocardiographic assessment of left ventricular volumes, ejection fraction, and mass compared with magnetic resonance imaging. *Echocardiography*. 2007;24(2):166-73.
14. Ferencik M, Gregory SA, Butler J, Achenbach S, Yeh RW, Hoffmann U, et al. Analysis of cardiac dimensions, mass and function in heart transplant recipients using 64-slice multi-detector computed tomography. *J Heart Lung Transplant*. 2007;26(5):478-84.
15. Yang NI, Hung MJ, Cherng WJ, Wang CH, Cheng CW, Kuo LT. Analysis of left ventricular changes after acute myocardial infarction using transthoracic real-time three-dimensional echocardiography. *Angiology*. 2009;59(6):688-94.
16. Sociedade Brasileira de Cardiologia / Sociedade Brasileira de Hipertensão / Sociedade Brasileira de Nefrologia. VI Diretrizes brasileiras de hipertensão. *Arq Bras Cardiol*. 2010;95(1 supl.1):1-51.
17. Sposito AC, Caramelli B, Fonseca FA, Bertolami MC, Afiune Neto A, Souza AD, et al.; Sociedade Brasileira de Cardiologia. IV Diretriz brasileira sobre dislipidemias e prevenção da aterosclerose. *Arq Bras Cardiol*. 2007;88(supl 1):1-18.
18. Brandão AP, Brandão AA, Nogueira AR, Suplicy H, Guimarães JJ, Oliveira JEP, et al.; Sociedade Brasileira de Cardiologia. I Diretriz brasileira de diagnóstico e tratamento da síndrome metabólica. *Arq Bras Cardiol*. 2005;84(supl 1):1-28.
19. Reichert J, Araújo AJ, Gonçalves CM, Godoy I, Chatkin JM, Sales MP, et al. Diretrizes para cessação do tabagismo. *J Bras Pneumol*. 2008;34(10):845-80.
20. Kannel WB, McGee D, Gordon TA. General cardiovascular risk profile: the Framingham Study. *Am J Cardiol*. 1976;38(1):46-51.
21. Henry WL, de Maria A, Gramiak R, King DL, Kisslo JA, Popp RL. Report of the American Society of Echocardiography Committee on Nomenclature and Standards in Two-Dimensional Echocardiography. *Circulation*. 1980;62(2):212-7.
22. Lang RM, Bierig M, Devereux RB, Flachskampf FA, Foster E, Pellikka PA, et al. Recommendations for chamber quantification: a report from the American Society of Echocardiography's Guidelines and Standards Committee and the Chamber Quantification Writing Group, developed in conjunction with the European Association of Echocardiography, a branch of the European Society of Cardiology. *J Am Soc Echocardiogr*. 2005;18(12):1440-63.
23. Lowes BD, Gill EA, Abraham WT, Larrain JR, Robertson AD, Bristow MR, et al. Effects of carvedilol on left ventricular mass, chamber geometry, and mitral regurgitation in chronic heart failure. *Am J Cardiol*. 1999;83(8):1201-5.
24. Yu CM, Gorcsan J 3rd, Bleeker GB, Zhang Q, Schalij MJ, Suffoletto MS, et al. Usefulness of tissue Doppler velocity and strain dyssynchrony for predicting left ventricular reverse remodeling response after cardiac resynchronization therapy. *Am J Cardiol*. 2007;100(8):1263-70.
25. Vieira ML, Oliveira WA, Cury AF, Cordovil A, Rodrigues ACT, Naccarato G, et al. Relação entre a análise bioquímica e ecocardiográfica tridimensional e bidimensional em pacientes com infarto do miocárdio com supradesnívelamento do segmento ST tratados por via percutânea. *Einstein*. 2010;8(1):53-61.