

---

## Penetrating Atherosclerotic Ulcer Involving the Ascending Aorta

*Delicia I. Gentile-Lorente<sup>1</sup> e Daniel Ortiz-Berbel<sup>2</sup>*

*Hospital de Tortosa "Verge de la Cinta" IISPV<sup>1</sup>, Tarragona; Hospital Universitario de Bellvitge<sup>2</sup>, Barcelona - Spain*

A 61-year-old Caucasian male, current smoker, with chronic ischemic heart disease, was admitted to the hospital due to angina. Coronary angiography showed an obstructive lesion in the circumflex coronary artery and a percutaneous intervention was performed. He later presented fever and anemia and was submitted to a transesophageal echocardiography and

a computed tomographic scan (Panel A), which showed the existence of a dilated ascending aorta (45 mm), a solitary penetrating atherosclerotic ulcer (10 x 10 mm) surrounded by a type A intramural hematoma (top of arrow) and pericardial effusion (\*). During the emergency surgery, the diagnosis was confirmed (Panel B, top of arrow and arrow).

### Keywords

Aorta/injuries; coronary vessels/injuries; aortitis; pericardial effusion.

---

**Mailing address: Delicia I. Gentile-Lorente •**

Esplanetes 14 - Tortosa - 43500 - Tarragona - Spain

E-mail: [dgentille.ebre.ics@gencat.cat](mailto:dgentille.ebre.ics@gencat.cat)

Manuscript received November 29, 2010; revised manuscript received November 29, 2010; accepted December 08, 2010.

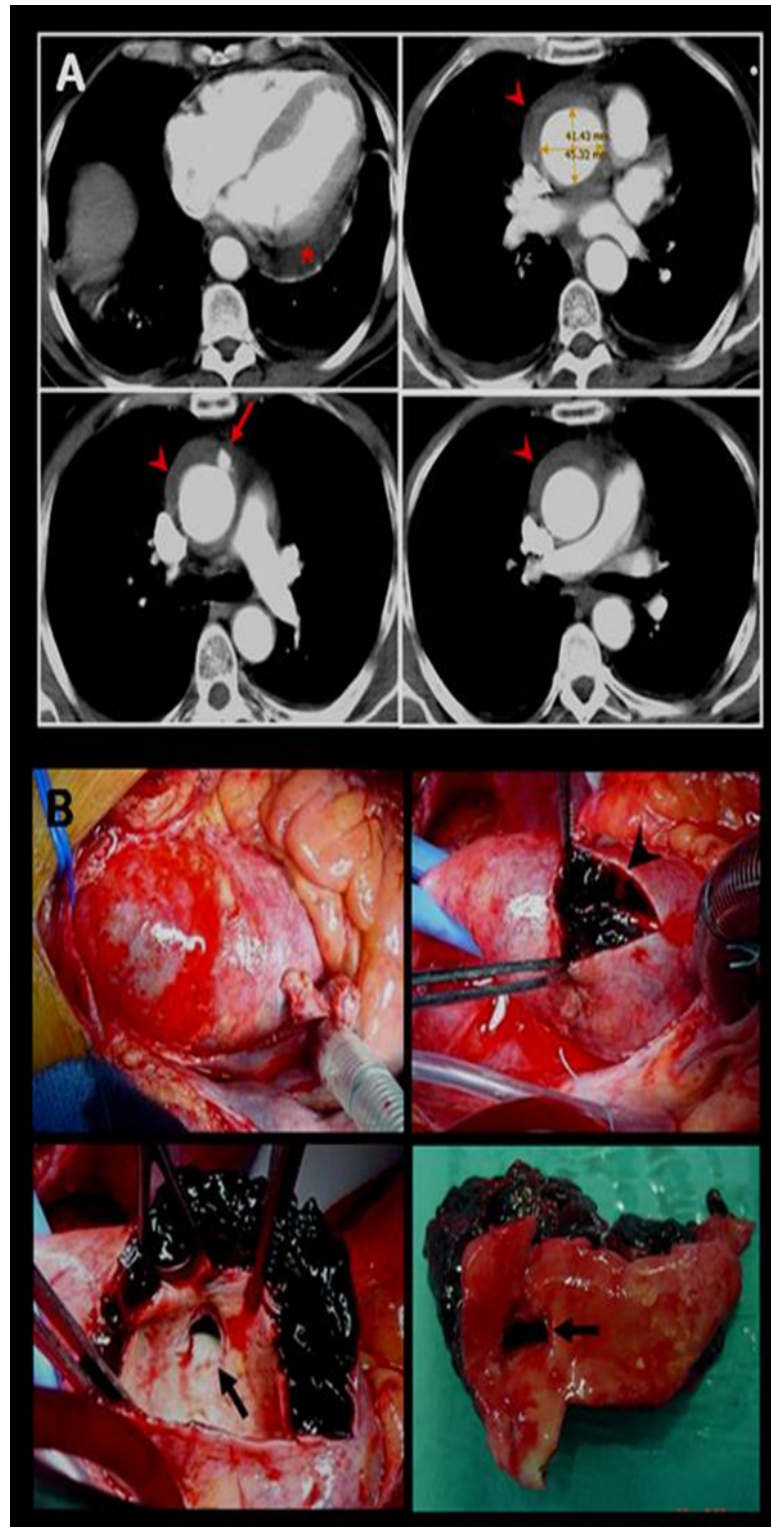


Figure 1 - Panels A and B.