

Takayasu Arteritis: Stenosis after Bare-Metal and Drug-Eluting Stent Implantation

Alexandre de Matos Soeiro², Ana Luiza Pinto², Bruna Bernardes Henares², Henrique Barbosa Ribeiro¹, Felipe Gallego Lima¹, Carlos Vicente Serrano Jr.¹

Unidade Clínica de Coronariopatia Aguda (UCCA) - Instituto do Coração (InCor) - HCFMUSP¹; Unidade Clínica de Emergência - Instituto do Coração (InCor) - HCFMUSP², São Paulo, SP – Brazil

Introduction

Takayasu arteritis (TA) is a chronic inflammatory arteritis of unknown etiology that affects large vessels, especially the aorta and its main branches, pulmonary vessels and coronaries¹. Due to the scarcity of cases, the monitoring of disease activity and best treatment regimen remain a challenge for all professional who treat these patients. Specifically in cases of acute coronary syndrome (ACS), the best interventional treatment remains undefined. Some case series have shown their experience with percutaneous transluminal coronary angioplasty (PTCA) and/or coronary artery bypass grafting (CABG), but with little consistence¹. In this context, the story of a single patient's evolution submitted to conventional coronary stenting and subsequently, consecutive drug-eluting stent implants, associated with in-stent coronary stenosis at the two procedures in the absence of inflammation, with subsequent implementation of CABG, is unique and reinforces the difficulty of managing ACS in the presence of this disease.

Case Report

This was a 33-year-old Caucasian female patient, born and raised in São Paulo, with a previous diagnosis of TA, treated at the emergency department after complaining of precordial gripping pain of moderate intensity, radiating to the left arm at rest, associated with mild dyspnea and sweating for one day. She reported a previous picture of unstable angina twelve months before, when a 5.0 x 12.0 mm bare-metal stent was implanted in left main coronary artery, and again six months before, when, due to in-stent restenosis (Figure 1) a new PTCA was performed with a 3.5 x 18 mm Cypher DES (sirolimus coated) in the same coronary segment.

After the procedure, intracoronary ultrasound was performed, which showed good stent apposition and expansion and minimal luminal area of 11.6 mm². She denied other comorbidities and

risk factors. She took methotrexate 25 mg / week, prednisone 10 mg/day, clopidogrel 75 mg/day, ASA 100 mg/day, atenolol 100 mg/day and ranitidine 300 mg/day.

At physical examination on admission, she was in good general status, eupneic (respiratory rate = 16 breaths per minute), with a heart rate of 70 beats per minute, peripheral arterial oxygen saturation of 96%, blood pressure of 118 mmHg x 56 in the right arm and 130 x 60 mm Hg in the left arm, ictus not visible but palpable with fingertip in the normal position at the fourth intercostal space under the left midclavicular line, rhythmic heart sounds with aortic systolic ejection murmur +2 / +6 and bilateral breath sounds on auscultation with no adventitious sounds. There was no murmur at heart palpation. Pulses were bilateral, wide and symmetrical. Jugular stasis was absent bilaterally at 45 degrees. At this time, ACS was diagnosed.

The electrocardiogram showed sinus rhythm with no acute ischemic alterations. The chest radiography showed no obvious alterations in heart size and normal lungs. The transthoracic echocardiogram showed a left atrium of 38 mm, left ventricular ejection fraction of 62% with no segmental dysfunction, and no other alterations. The angiography showed bilateral carotid stenosis > 50% and absence of subclavian stenosis. Laboratory tests showed C-reactive protein levels of 2.34 mg/L, erythrocyte sedimentation rate of 16 mm and negative markers of myocardial necrosis (CK-MB and troponin). A coronary angiography (Figure 2) was performed, which showed in-stent restenosis with 90% obstruction in the left main coronary artery and we chose to perform another CABG.

The patient underwent the CABG with cardiopulmonary bypass and *in situ* left internal mammary artery implant to the anterior descending artery and saphenous vein graft to the diagonal artery. After eight days, the patient was discharged, asymptomatic, while on prednisone 10 mg / day, mycophenolate mofetil 1500 mg/day, chloroquine 250 mg / day, atenolol 50 mg/day, simvastatin 20 mg/day, aspirin 100 mg/day and ranitidine 300 mg/day.

After a six-month follow up, the patient was asymptomatic. On that occasion, a coronary artery angiotomography was performed for graft assessment and their patency was verified, with no new points of arterial occlusion.

Keywords

Takayasu Arteritis; Stents; Drug-Eluting Stents; Myocardial Revascularization.

Mailing Address: Alexandre de Matos Soeiro •

Rua Maranhão, 680 / 81 - Santa Paula – Postal Code 09530-440 - São Caetano do Sul, SP, Brazil

E-mail: alexandre.soeiro@bol.com.br

Manuscript received May 02, 2012; revised manuscript August 12, 2012; accepted September 26, 2012.

Discussion

The diagnosis of TA was carried out based on the criteria of the American College of Rheumatology of 1990, and thus

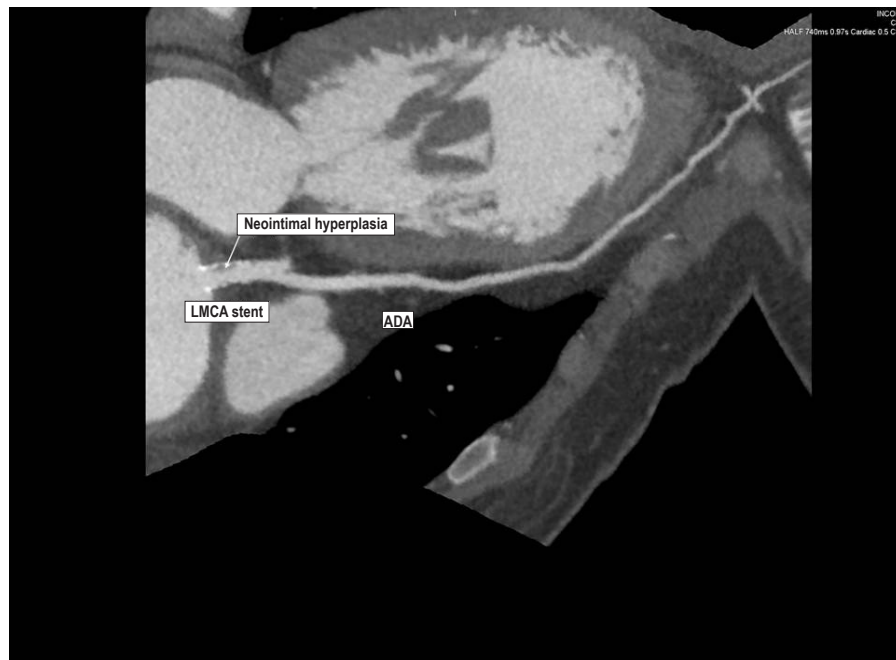

Figure 1 - Coronary CT angiography showing bare-metal stent restenosis in the left main coronary artery (70% obstruction). LMCA : left main coronary artery; ADA : anterior descending artery.

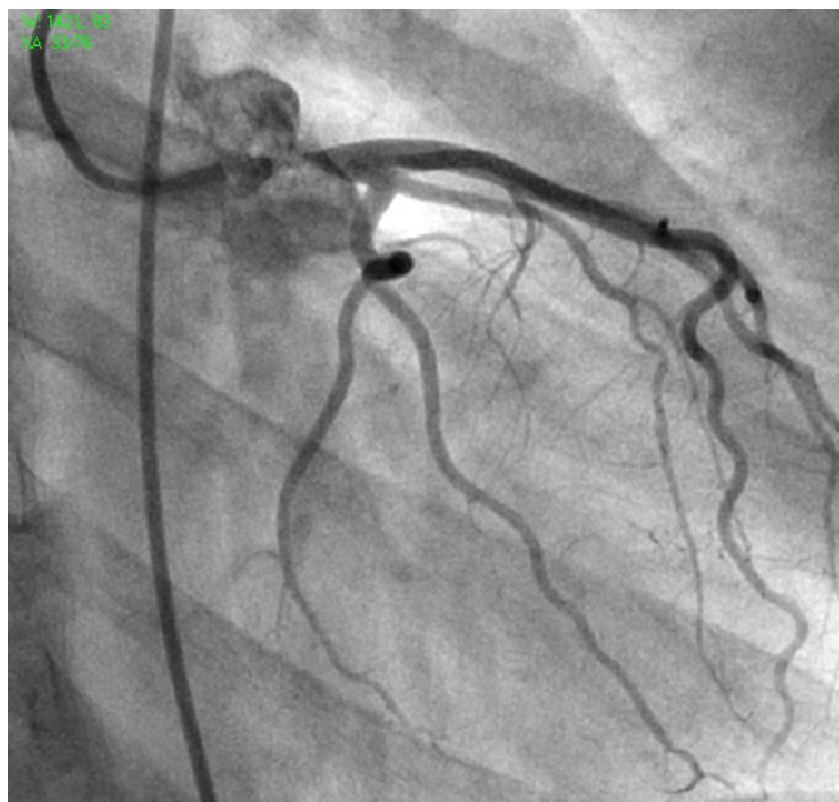


Figure 2 - Coronary angiography showing drug-eluting stent restenosis in the left main coronary artery.

Case Report

established by the presence of age < 40 years, difference of blood pressure > 10 mmHg between limbs, aortic murmur and arteriogram alteration¹.

TA affects mainly women (90% of cases) aged 10 to 40 years. In the literature, the presence of some type of coronary disease is described in 6% to 30% of patients with TA¹⁻⁴. Its pathogenesis is not yet completely understood and is currently considered the result of chronic autoimmune inflammation of large arteries, in addition to being associated with other factors, such as infectious agents and genetic predisposition. Disease development appears to occur in two phases: the first phase, in which there is elevation of inflammatory markers, followed by a chronic phase, with the development of vascular failure³.

The precise timing of coronary lesions is not known. Most studies say there is a correlation between pictures of ACS and elevated inflammatory markers with C-reactive protein and/or erythrocyte sedimentation rate¹. However, as in our case, some case reports refer no direct association between active inflammation and coronary symptom⁵.

Injury caused by the disease can vary from stable angina to acute myocardial infarction and should be quickly recognized, so adequate immunosuppression therapy can be initiated together with specific cardiac therapy, which may change prognosis⁴. There are few case descriptions in the literature, but myocardial ischemia is a leading cause of death by the disease, with 50% of mortality in five years of follow-up³.

As reported in our case, the involvement of left and right coronary artery ostia are the most common findings, found in 87.5% of cases of TA with coronary involvement. In such cases, luminal obstruction is caused by the extension of intimal proliferation and fibrotic contraction of medial and adventitial layers of the ascending aorta. However, coronary lesions can also occur in more distal segments, as chronic inflammation in TA may contribute to the development of premature atherosclerosis⁴. The diagnosis is usually made through the clinical presentation associated with coronary angiography, but recent studies have demonstrated excellent accuracy with coronary angiography in cases of TA⁴.

Conventional stenting in patients with TA may lead to restenosis in up to 78% of the cases, as the one described here. Descriptions of drug-eluting stent use in this group of patients are rare; however, the results also show high rates of restenosis in the short and long term, which raises questions about the safety of its use in patients with TA. Some authors suggest that this type of stent could be used only as a bridge to reach better patient immunosuppression and that CABG should be performed at the appropriate time^{2,4,6,7}.

Yokota et al⁴ reported the case of a 52-year-old woman submitted to four coronary angioplasties of the ADA, the first with a bare-metal stent and the other

three with drug-eluting stents. Restenosis was observed three times, and only on the last attempt the patient developed no new obstructions. According to the authors, in this latter procedure, the combination of higher doses of corticosteroids may have been responsible for vessel patency^{4,8}. However, in our case, we showed the occurrence of in-stent restenosis even with the presence of discrete inflammatory activity, confirming the controversy over the implantation of DES in these patients.

With respect to CABG, the ideal coronary artery bypass method has yet to be established. The presence of ostial lesion with aortic involvement and possible involvement of the subclavian arteries makes the decision a complex one. In contrast with most CABG surgeries performed in patients with TA, the main graft used is the saphenous vein, except when there is a lot of calcification in the aorta. The survival reported with this type of implant anastomosed to the left anterior descending artery reaches 80% in 10 years, with event-free survival of 77%. The use of *in situ* internal thoracic artery is not proscribed, but should be avoided and, when performed, the subclavian artery patency must be assessed by imaging examinations prior to CABG^{1,9}. In the case described, regardless of *in situ* use of the left internal thoracic artery, the patient had no symptoms and adequate graft patency after six months of follow up.

Conclusion

The present case shows that in TA patients with ACS, rapid diagnosis and early treatment can greatly contribute to the change in prognosis. The measurement of inflammatory markers may have no direct correlation with the ACS, with most coronary lesions being ostial ones, which poses a greater risk to the patient. Although controversial due to the lack of studies, performing TCA in patients with conventional and drug-eluting stents showed to be ineffective and was followed by restenosis at six months in the absence of significant inflammation. Even though it is rarely reported in the literature, CABG with *in situ* internal thoracic artery graft was safe, provided that the patency of the subclavian artery is evaluated in the preoperative period and adequate immunosuppression is maintained at long-term.

Potential Conflict of Interest

No potential conflict of interest relevant to this article was reported.

Sources of Funding

There were no external funding sources for this study.

Study Association

This study is not associated with any post-graduation program.

References

1. Rav-Acha M, Plot L, Peled N, Amital H. Coronary involvement in Takayasu's arteritis. *Autoimmun Rev*. 2007;6(8):566-71.
2. Gelape CL, Alvarenga FC, Figueroa CC, Ribeiro AL. Tratamento de estenose de tronco de coronária esquerda na arterite de Takayasu. *Rev Bras Reumatol*. 2007;47(5):390-3.
3. Soto ME, Espinola-Zavaleta N, Ramirez-Quito O, Reyes PA. Echocardiographic follow-up of patients with Takayasu's arteritis: five-year survival. *Echocardiography*. 2006;23(5):353-9.
4. Yokota K, Shimpo M, Iwata T, Hirose M, Ikemoto T, Ohya K, et al. A case of Takayasu arteritis with repeated coronary artery restenosis after drug-eluting stent implantation successfully treated with a combination of steroids. *Intern Med*. 2012;51(7):739-43.
5. Johnston SL, Lock RJ, Gompels MM. Takayasu arteritis: a review. *J Clin Pathol*. 2002;55(7):481-6.
6. Lee HK, Namgung J, Choi WH, Choe H, Kwon SU, Doh JH, et al. Stenting of the left main artery in a patient with Takayasu's Arteritis. *Korean Circ J*. 2011;41(1):34-7.
7. Hall S, Barr W, Lie JT, Stanson AW, Kazmier FJ, Hunder GG. Takayasu arteritis: a study of 32 North American patients. *Medicine (Baltimore)*. 1985;64(2):89-99.
8. Sakai H, Oyama N, Kishimoto N, Takahashi M, Urasawa K, Tsutsui H. Revascularization of malignant coronary in-stent restenosis resulting from Takayasu's arteritis using sirolimus-eluting stents. *Int Heart J*. 2006;47(5):795-801.
9. Endo M, Tomizawa Y, Nishida H, Aomi S, Nakazawa M, Tsurumi Y, et al. Angiographic findings and surgical treatments of coronary artery involvement in Takayasu arteritis. *J Thorac Cardiovasc Surg*. 2003;125(3):570-7.