

Case 3/2009 - Six-Month-Old Infant with Large Interventricular Communication and Enlarged Thymus, which Simulated the Characteristic Image of Total Anomalous Drainage of the Pulmonary Veins at the Chest X-Ray

Edmar Atik

Hospital Sírio-Libanês de São Paulo, São Paulo - Brazil

Clinical data

Progressive tiredness since birth, mainly up to 4 months of age, despite the use of anti-congestive medication. Low weight gain.

At the physical examination the infant was dyspneic, acyanotic and pulses were normal. Weight was 6,800g; the respiratory frequency was 70 breaths/min and the heart rate was 120 bpm. The aorta could not be palpated at the suprasternal notch. The infant presented precordial bulging and slight impulses at the left sternal border. The *ictus cordis* was palpated at the 4th left intercostal space in the hemiclavicular line, by a digital pulp. The heart sounds were hyperphonic and a systolic murmur ++, rough, was audible on the lower left sternal border, irradiating to the right, not accompanied by thrill. The liver was at 3 cm of the right costal border.

The electrocardiogram showed signs of biventricular overload with RS complexes from V1 to V6. $\hat{A}QRS$ was at $+120^\circ$, $\hat{A}P$ at $+50^\circ$ and $\hat{A}T$ at $+70^\circ$.

Radiographic image

Shows enlarged cardiac area at the expense of the right cavities with protrusion of the lower arches and increased pulmonary vascular net by larger-caliber arterial vessels. Additionally, the upper structures to the right and to the left are dilated, which seemed like dilated *venae cavae* (Figure 1).

Key Words

Ventricular septal defect, total anomalous pulmonary venous drainage, thymus.

Diagnostic impression

The radiographic image in the shape of a “snowman” or “number eight” suggests, preliminarily, the diagnosis of total anomalous pulmonary venous drainage (TAPVD) in a left vertical vein, along with increased pulmonary vascular net.

Differential diagnosis

Acyanogenic cardiopathies with pulmonary hyperflow of interventricular or even interatrial communication type, associated to an enlarged thymus, also simulate this same image, usually found in TAPVD.

Diagnostic Confirmation

The clinical data lead to the diagnosis of acyanogenic cardiopathy with heart failure of the interventricular communication type. The radiographic image in the suspected TAPVD did not give rise to diagnostic doubts, but increased the curiosity about its exact cause.

Conduct

During a surgical intervention, a large 10-mm perimembranous interventricular communication was closed and the enlarged thymus was resected, thus confirming the origin of the dubious radiographic image. The patient presented good evolution and the anatomofunctional picture was resolved.

Comment

Any congenital cardiopathy, when presenting in the first months of life along with an enlarged thymus, can eventually simulate TADVP. Therefore, in such situation, it becomes mandatory to analyze other clinical and echocardiographic elements, in order to achieve a correct diagnosis.

Mailing address: Edmar Atik •

InCor - Av. Dr. Enéas Carvalho de Aguiar, 44 - 05403-000 - São Paulo, SP - Brazil

E-mail: conatik@incor.usp.br

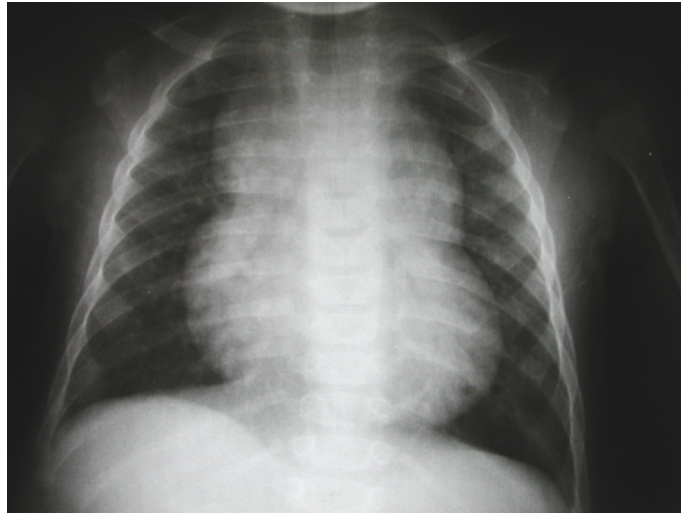

Figure 1 - Radiographic image showing cardiomegaly due to enlarged right cavities and increased pulmonary arterial net, in addition to the "snowman" morphology, usually observed in cases with total anomalous drainage of the pulmonary veins.

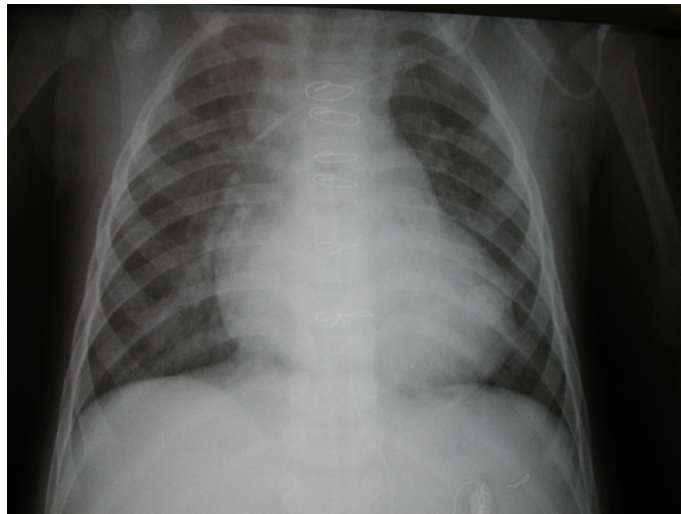


Figure 2 - Radiographic image, six days after the surgical repair, still depicts the cardiomegaly, but without the upper dilations, after the thymus resection.