

## Interventricular Septal Defect Percutaneous Occlusion. Initial Experiment

Francisco José Araújo Chamié de Queiróz, Raul Ivo Rossi Filho, Sérgio Ramos, César Esteves, Daniel Silva Chamié de Queiróz, Paulo Renato Machado, João Carlos Tress, Stella Suzana Horowitz, Helder Paupério, Rosaura Victer  
*Cardiologia Pediátrica e Fetal do Rio de Janeiro - CARPE e Instituto de Cardiologia do Rio Grande do Sul (IC/FUC) - Rio de Janeiro, RJ - Porto Alegre, RS - Brazil*

### OBJECTIVE

To assess the initial experiment with percutaneous closure of interventricular septal defect (IVSD), especially perimembranous IVSD (PMIVSD) with the new Amplatzer prosthesis.

### METHODS

Eleven patients were submitted to the procedure. Six of them had perimembranous IVSD (PMIVSD) and five with muscular IVSD (MIVSD). Two showed repeated respiratory tract infections and had low ponderal gain. One of them showed a previous history of infectious endocarditis. The others were asymptomatic and were selected through transthoracic echocardiography (TTE).

### RESULTS

In MIVC group (n=5), a patient had apical IVC, two had medioseptal defects and two patients showed multiple defects. In this group, an interarterial septal defect (IASD) (Amplatzer Septal Occluder®) and five prostheses for MIVSD (Amplatzer VSD-MUSC Occluder®), and one patient received two devices. All implants were well-succeeded and went by without complications. In PMIVSD group (n=6), two patients had membranous septal aneurysms. In five, we identified two orifices with selective angiography. We used arterial canal Amplatzer prostheses (ACP) (Amplatzer Duct Occluder®) in 1 patient and specific prostheses for PMIVSD in the others (Amplatzer VSD-MEMB Occluder®). A perimembranous occluder migrated immediately after released, being removed from the descending aorta. Another patient showed total atrioventricular block (TAVB), which reversed after corticotherapy.

### CONCLUSION

The procedure is technically complex and must be performed only in specialized centers. Despite of that, it showed safe and efficient in the selected cases, and it can be provided as an alternative to traditional surgical treatment.

### KEY WORDS

interventricular septal defect, percutaneous occlusion, congenital cardiopathy, Amplatzer

Interventricular septal defects (IVSD) have high prevalence, with an incidence of 1.35 to 2.94 per 1,000 born-alive infants<sup>1</sup>. They correspond from 20 to 30% of congenital cardiac defects<sup>2,3</sup>. The most commonly found IVSD are those that afterwards extend towards the *crux cordis*, reaching its membranous septum, called perimembranous, which occurs in 66.7 to 75% of the cases, followed by muscular ones, in 16%, and sub-arterial IVC, in 14%<sup>3,4</sup>.

The small (restrictive) IVSDs can close spontaneously and are generally innocuous, without the need for treatment. Both assertions are questioned today, in view of recent articles.

It is known that spontaneous closure really takes place in approximately 48% of defects, within the first nineteen months of life<sup>4</sup>. From that date, the closure rate falls drastically, reaching near zero at 7 years of age.

Functionally small (restrictive) IVSDs, which were imagined having benign evolution, may show some severe complications along adult life, especially infectious endocarditis (10%), aortic regurgitation (19%) and need for surgery (12%)<sup>5-7</sup>. Such data justify taking closure into consideration, even those of small IVSDs.

IVSD surgical closure is safe. However, there are risks of complications that include atrioventricular block, other early or tardive arrhythmias, post-pericardiotomy, pulmonary and mediastinal infections, and even death<sup>8</sup>, not mentioning maintenance of residual IVSD, which is much more frequent in our milieu. That made the creation of a safer and less risky alternative for the closure of those defects become extremely desirable.

The first catheter closure IVSD attempts dated from 1987, with the first works by James Lock<sup>9</sup>, using Rashkind's double "umbrella." Many others have followed, using many devices, from which Redington, in 1993, is distinguished. He was the first to report perimembranous interventricular communication closure (PMIVSD)<sup>10,11</sup>.

## METHODS

We selected 11 patients for percutaneous occlusion of ventricular septal defect (table I). Patients without associated defects, demanding surgical correction were included in the present study. Two showed signs of pulmonary congestion and made use of anti-congestive drugs. The others were asymptomatic and had regular cardiological follow-up, without specific medication. All of them were requested to submit to prophylaxis for infectious endocarditis, whenever necessary. Patients were elected after an analysis of their transthoracic echocardiograms, with color flow mapping.

The procedure was similar in all patients<sup>12-14</sup>. The transesophageal probe was inserted under general anesthesia. Then, venous and arterial punctures were performed, and 100 U/kg de Heparin was administrated

**Table I - Relationship of patients and types of IVSDs with symptoms shown**

ID	Sex	Age (months)	Weight (kg)	Type of IVSD	Symptoms
IBSG	M	36	22	Perimembranous	Asymptomatic
TBP	F	60	26	Perimembranous	Asymptomatic
TMBC	F	156	46	Perimembranous	Asymptomatic
STBBN	M	96	40	Muscular apical	Asymptomatic
VEM	F	108	32	Perimembranous	Asymptomatic
EFB	F	228	62	Muscular apical + Outlet way muscular	Asymptomatic
DSM	M	192	69	Perimembranous	Asymptomatic
CASM	M	48	21	Perimembranous	Asymptomatic
TBL	F	113	27	Mediotrabecular muscular	SAH + previous infectious endocarditis
RMMS	M	16	8.8	Mediotrabecular muscular	Pneumopathies + low weight + CHF
ACBS	F	8	9.7	Multiple muscular	Pneumopathies + low weight + CHF

in arterial sheath. In case the procedure exceeded one hour, we would administrate half of a dose every 30 minutes until the end of the procedure. When the exam was initiated, a dose of endovenous cephalothin was injected, in a total of 100 mg/kg/24 h, which was replaced for oral cephalexin after the patient woke up and kept for three days.

Then, we performed the standard hemodynamic study, with left and right chamber catheterization for pressure record and sample collection for oxymetry. Angiographies in LV were obtained, at the incidence that would best describe the defect, and make possible the measurement of the orifice to be occluded (fig. 1). Panoramic aortography was carried out in PMIVSDs to define the presence of aortic regurgitation.

In apical muscular interventricular communications (MIVSD), we punctured the right jugular vein and, in upper defects, the femoral vein. IVSD was crossed by the left ventricle, with the help from hydrophilic guide, positioning right coronary Judkins catheter (JR) or Cobra catheter in RV. Inside it a rope wire was advanced and exteriorized up to left pulmonary ramus or right atrium, in cases the jugular vein puncture was performed. The rope was tied with a proper device ("Amplatzer Goose Neck Snare") inside a right coronary Judkins guide-catheter (JR) 6F and removed through the corresponding vein, which created an arteriovenous snare to provide support to the insertion of a long sheath. The sheath, of a suitable caliber to prosthesis' size, was inserted through the vein and advanced over the guide, to left ventricle (fig. 2A).

In perimembranous IVSD (PMIVSD), the arterial catheter was positioned through IVSD, at inferior caval vein. The sheath and expander were advanced through the vein, in opposite direction, until they find the tip of arterial catheter ("kissing catheter technique"). The arteriovenous snare was pulled at both ends and the catheter and sheath were kept fixed in position for surgical clamps placement, clamping the guide at the ends of catheter and sheath. The long sheath was pushed to

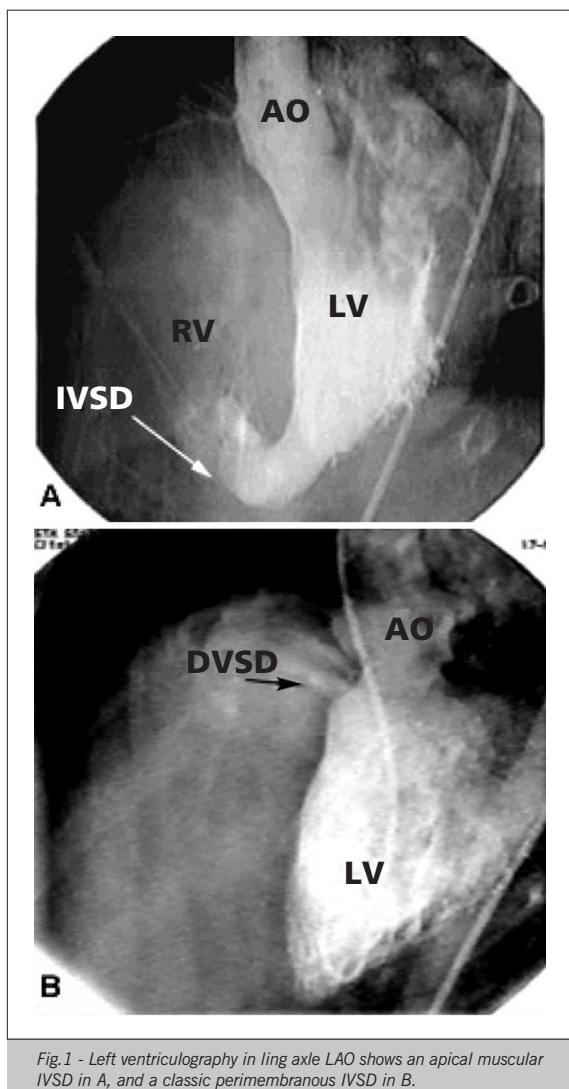


Fig.1 - Left ventriculography in ling axle LAO shows an apical muscular IVSD in A, and a classic perimembranous IVSD in B.

ascending aorta, by pulling simultaneously the arterial catheter. When reaching aorta, the clamps were released, the expander was pulled few centimeters inside the long sheath and the arterial catheter was retreated, which created a "slack" in the guide. That was, then, advanced through arterial side, forming a bend in ascending aorta, crossing the aortic valve and reaching LV cavity. With that maneuver, the sheath was then pushed towards LV, immediately under aortic valve. The expander was removed and the prosthesis loaded for release.

We chose the prosthesis with central portion prosthesis at least 2 to 4 mm larger than the diameter of the orifice to be occluded. The prosthesis, entangled around the release wire, was inserted in its own loader and then transferred to the long sheath and advanced to LV, in which the distal disk was exteriorized. The prosthesis was pulled towards the septum, with its position checked through fluoroscopy, by means of little injections of contrast through arterial catheter inside LV, and through echotransesophageal (ETE). Then, it was positioned inside

IVSD, retreating the sheath and exteriorizing the remaining of the device. If the position was considered as satisfactory, the prosthesis was released, by untangling it from the wire. A control ventriculography was performed and the procedure was finished (fig. 2B).

We used 5 "Amplatzer Muscular VSD Occluder" (fig. 3A) prostheses in four patients. Such device consists of two disks, of same diameter, made of a nickel and titanium alloy ("Nitinol<sup>®</sup>") self-expansive, connected by a central part, which corresponds to IVSD size. In order to enhance occlusion capacity, the prosthesis has polyester bits inside it. In another case, we used an IASD (Amplatzer Septal Occluder<sup>®</sup>, AGA) prosthesis.

Perimembranous IVSD (Amplatzer VSD MEMB Occluder<sup>®</sup>) prosthesis (fig. 3B) consists of two low-profile "Nitinol<sup>®</sup>" asymmetric disks, connected by a short (1.5 mm) central portion. The left disk is 0.5 mm wider than the central portion, at the upper side, to avoid aortic leaflets, and 5.5 mm in the lower part. The lower part of the disk shows a radio-opaque mark pointing at LV apex during implant. The right disk is round and 4 mm larger than the central portion. Polyester bits are stuck inside prosthesis to increase thrombogenicity. The prosthesis is connected to the release wire through a thread, located at the central portion of right disk, which has its upper aspect flat, opposed to the lower mark in the left disk. In addition to the release wire, the system features a special catheter ("pusher catheter") with a metallic capsule at its end, upper flattened to fit perfectly with the thread, keeping the prosthesis always with the left disk mark directed downwards. When loading the system, the release wire must be manually adjusted and pulled in a way to allow for the fitting of the thread in the metallic capsule, until a little click is heard or felt. That prosthesis was used in five cases and, in the other we used arterial canal occlusion prosthesis (Amplatzer Duct Occluder<sup>®</sup>).

## RESULTS

A group consisted of 5 patients, 2 of male sex and three of female sex. The ages ranged from 8 to 228 months ( $92.20 \pm 89.14$  months) and the weights between 8.8 and 62 kg ( $29.5 \pm 22.32$  kg) (tab. II). Three patients had single defects, with one apical and two at the middle portion of trabecular muscular septum. Two patients had more than one defect: one of them showed defects in the outlet way septum and at the apical region, and both were occluded, and the other was of "Swiss cheese" type, with the larger orifice located at inlet way, another apical and four punctiform ones at the trabecular septum lower, with the greater defect being occluded. The measurement of closure-submitted orifices varied from 4.5 to 12 mm ( $7.01 \pm 2.69$  mm). Six prostheses were used in the five patients. In four of them, we used Amplatzer prostheses for IVSD Muscular, with two devices in the same patient (fig. 4A). The case with the largest defect (12 mm) was

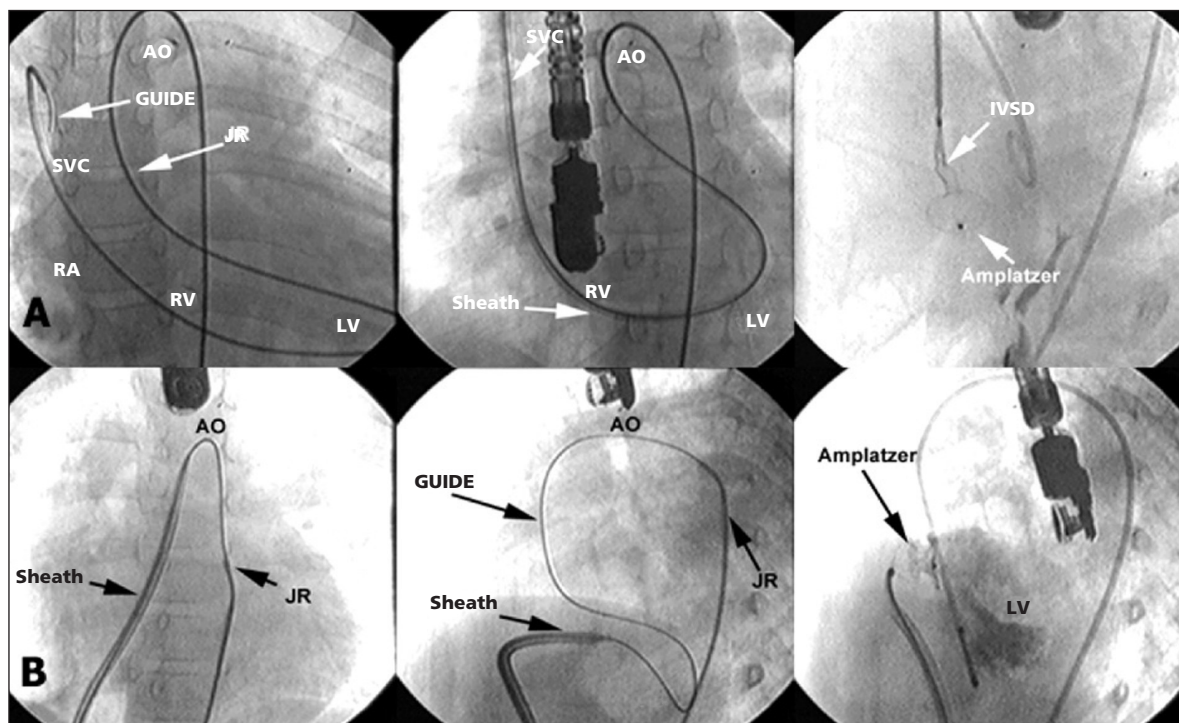


Fig. 2 - In A, the closure sequence of a muscular IVSD. In B, the necessary steps for the closure of a perimembranous IVSD.

a symptomatic infant, weighing 8.8 kg, in whom an IASD was used for not having another available. The implant went by without interurrences and with good results.

All procedures succeeded. In the case of the patient with Swiss cheese-type defect, during the formation of arteriovenous snare, there was an important tricuspid regurgitation, with total AVB due to tension of the guide against the valva, a situation that was promptly reverted with the removal of the guide. A new attempt was made, approaching the defect through RV, successfully and without complications.

Another group consisted of six patients, being three of male sex and three of female sex. Ages varied from 36 to 192 months ( $100.0 \pm 63.34$  months) and the weights from 16 to 69 kg ( $34.33 \pm 20.04$  kg). Two of them showed membranous septum aneurysm, whose measurements of the collum were of 9 and 16 mm (tab. III). In the two patients with aneurysms and in other three patients we identified two orifices through selective angiography. The only patient with single orifice did not have aneurysm. The measurement of occluded orifices varied between 4.6 and 8 mm ( $6.26 \pm 1.45$  mm).

In the first case of the series, the prosthesis for PMIVC was not available yet and we used one for APC (Amplatzer Ductal Occluder®) after angiographic analysis of the defect. We approached the orifice through RV and released the prosthesis, with no difficulty and with success. In all other patients five prostheses for Perimembranous IVSD (Amplatzer VSD MEMB Occluder®) (fig. 4B) were used.

Only one patient showed previous aortic regurgitation,

of 1/4+, with right coronary cuspid prolapse, which worsened a little, after occlusion.

The first patient in the series showed 3<sup>rd</sup> degree LBBB in the first appointment after implant, which has stayed until today, although completely asymptomatic.

The last patient of the series showed complete atrioventricular block (TAVB) at the moment of prosthesis




Fig. 3 - A) Amplatzer prosthesis for muscular IVSD. B) perimembranous IVC prosthesis (Amplatzer VSD MEMB Occluder®).

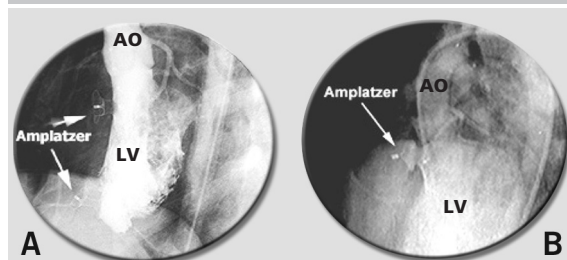


Fig. 4 - A) Left ventriculography showing two occluded IVSDs with Amplatzer prostheses for muscular IVC. B) Left ventriculography showing perimembranous IVSD occluded with Amplatzer prosthesis for perimembranous IVSD.

**Table II - Relationship of types of muscular IVSD with orifice diameters, prostheses used and the result**

ID	Muscular IVSD (mm)	Orifices	Prostheses	Result
STBBN	Apical	12	MUSC 14	Complete closure
EFB	Apical + outlet way	8+6	MUSC 10+12	Complete closure
TBL	Mediotrabecular	5,6	MUSC 8	Complete closure
RMMS	Mediotrabecular	12	ASO 12	Complete closure
ACBS	Swiss cheese 1.5+?	4.5+	MUSC 6	Little shunt

**Table III - Relationship of perimembranous IVSDs with morphology, diameters of orifices, prostheses used and results**

ID	Morphology	Orifices (mm)	Prostheses	Result
IBSG	Without aneurysm	6+1	ADO 10-8	Complete closure
TBP	Without aneurysm	5+2	MEMB 10	Complete closure
TMBC	Aortic prolapse	8	MEMB 12	Complete closure +IAo 1/4+
VEN	Aneurysm 9mm	6+2	MEMB 8	Complete closure
DSM	Aneurysm 16mm	8+5.4	MEMB 12	Embolization for descending Ao
CASM	Without aneurysm	4.6+3.3	MEMB 8	Complete closure +TAVB

implant, reversing some hours later, with venous corticotherapy. He was discharged in sinus rhythm, and was admitted again three days after under TAVB, again reversed with corticotherapy and he is still hospitalized for observation.

The implant was not successful in only one of the patients. In him, the prosthesis embolized to descending aorta, immediately after released from delivery system. It was rescued with proper lasso and removed, causing a lesion at iliac artery, corrected with right aortofemoral by-pass.

## DISCUSSION

In MIVSDs, the procedures were less difficult and with fewer complications, despite including the patients with lower weights and more symptomatic.

The PMIVSD closure procedure is much more difficult and delicate. For being relatively new in our milieu, some difficulties still persist. The suitable choice of prosthesis, leaves sometimes some doubts, especially in cases of PMIVSD with aneurysm or more than one orifice (in most cases). The choice of which orifice must be approached is based on the diameter, and the largest orifice is generally the one chosen for the passage of the sheath. When there is aneurysm formation, it may have questions on the size of the prosthesis, whether it is large enough to occlude the aneurysm collum, or small enough to close the orifice completely. That decision is absolutely individual and made at the time of the procedure. When the prosthesis is chosen for the orifice diameter, it can stay completely inside the aneurysm and, then, stay far from the aortic

valve, which may be advantageous, since it is able to occlude all orifices.

Regarding the size of the prosthesis, we tried to choose sizes at least 2 mm larger than the orifice to be occluded. Especially in PMIVSD cases, we think that today the prosthesis should be chosen with the smallest possible diameter, so it does not cause compression in the conduction system, which leads to bundle branch blocks or even TAVB. The patient who showed TAVB had it during the positioning of the prosthesis inside IVSD. As if he was hemodynamically stable, with heart rate at 90 bpm, we opted for carry on and released the prosthesis. We started venous corticotherapy, with block reversion about 20 to 30 minutes after the end of implantation. The patient was discharged on the day after under sinus rhythm. He was admitted three days after discharge, showing a sudden and transitory hypertonia records at home. At admission, he showed a high level AVB, which gave way again after prolonged corticotherapy. In that case, analyzing post-procedure angiography, it seems clear that the prosthesis was oversized (8 mm for a 4.6 mm orifice). Maybe the use of a 6mm device would be more suitable, although, in at least one more case, the prosthesis showed the same mushroom aspect, without any complication arising from it.

The lack of availability of specific devices made us use different prostheses from those of IVSDs in two situations. In the first case of the series there was not availability of IVSD prostheses in Brazil yet, and based in IVSD angiographic image, we opted for an ACP prosthesis. In other situation, we used a device for IASD in a symptomatic infant. Both were well-succeeded. Those cases exemplify the usefulness of Amplatzer prostheses, which can adapt to many different defects, increasing the scope of its use. Despite of that, we believe that we should only make use of such artifice in exception situations and special circumstances.

We approached PMIVSD through LV, as the most recent technique requires, and we found difficulties in the correct positioning of sheath in some of them. An alternative to overcome such difficulty can be the careful release of part of left disk at descending aorta, with a slow retreat of the sheath to LV. We had already used that technique at the closure of a Valsalva breast fistula for RA and we reused it in one of the cases.

The approach of IVSD through RV is also possible and can be an option in selected cases. We used that way in the first case of PMIVSD series, thus releasing an APC prosthesis with no difficulty and with good results.

The excessive length of the orifice to be occluded, in PMIVSDs, can be a big problem and bring about the embolization of prosthesis, as occurred in one of our cases. In that patient, IVSD was complex, with the presence of aneurysm and two very long tunnel-shape orifices (fig. 5). In those cases, an attempt with Muscular IVSD prosthesis should be made, which shows a longer length

of central portion, since it does not interfere with aortic leaflets moving.

The performance of aortography to determine the presence of aortic regurgitation is usual in PMIVSDs. When surgery is the procedure performed, regurgitation may be a reason for the anticipation of correction, presuming that IVSD closure stops Venturi effect, which worsens or even causes valve insufficiency. By drawing a parallel to that situation, a mild regurgitation should not be a contraindication for the procedure. The prosthesis, when properly positioned, besides stopping left-right shunt, eliminating Venturi effect, could also better withstand the weakened aortic cuspid, preventing from the evolution of the process. In fact, in our case, the result from the procedure was positive, with IVSD closure and the minimum worsening of regurgitation at the first moment, keeping stable during follow-up, after 8 months, similar to the case performed at Instituto Dante Pazzanese<sup>15</sup>. Naturally, greater studies will be necessary to either confirm or contradict those hypotheses. While more experience has not been accrued, the performance of percutaneous closure of an IVSD with aortic cuspid prolapse must be recommended after a careful assessment of procedure's risk-benefit rate.

## ACKNOWLEDGEMENTS

To Drs. Márcia Magda, Rodrigo Siqueira, Robledo Dias, Lísia França, José Breno de Souza Filho, Lúcia Maria Salerno, Simone Pedra and Carlos Pedra for their cooperation.

## REFERENCES

- Hoffman JIE, Rudolph AM. The natural history of ventricular septal defects in infancy. *Am J Cardiol* 1965; 16: 634-53.
- Van Hare GF, Soffer LJ, Sivakoff MC, Liebman J. Twenty-five-year experience with ventricular septal defect in infants and children. *Am Heart J* 1987; 114: 606-14.
- Anderson RH. Ventricular septal defects In: Anderson RH, Macartney FJ, Shinebourne EA, Tynan M, eds. *Pediatric Cardiology*. Vol 1. Edinburgh. Churchill Livingstone: 1<sup>st</sup> edition, 1987: 615-42.
- Miyake T, Shinohara T, Nakamura Y et al. Spontaneous closure of ventricular septal defects followed up from <3 months of age. *Ped Intern* 2004; 46: 135-40.
- Otterstad JE, Erikssen J, Michelsen S, Nitter-Hauge S. Long-term follow-up in isolated ventricular septal defect considered too small to warrant operation. *J Intern Med* 1990; 228: 305-9.
- Neumayer U, Stone S, Somerville J. Small ventricular septal defects in adults. *Eur Heart J* 1999; 19: 1573-82.
- Gabriel HM, Heger M, Innerhofer P et al. Long-term outcome of patients with ventricular septal defect considered not to require surgical closure during childhood. *J Am Coll Cardiol* 2002; 39: 1066-71.
- Backer CL, Winters RC, Zales VR et al. The restrictive ventricular septal defect: how small is too small to close? *Ann Thorac Surg* 1993; 56: 1014.
- Lock JE, Block PC, McKay RG, Baim DS, Keane JF. Transcatheter closure of ventricular septal defects. *Circulation* 1988; 8: 361-8.
- Redington AN, Rigby ML. Novel uses of the Rashkind ductal umbrella in adults and children with congenital heart disease. *Br Heart J* 1993; 69: 47-51.
- Fernandez AI, Díez-Tomás JJ, Daviña JB, Suarez JR, Hernandez MC. Seguimiento de las comunicaciones interventriculares de larga evolución. *An Pediatr (Barc)* 2004; 60: 148-52.
- Hijazi ZM, Hakim F, Al-Fadley F, Abdelhamid J, Cao Q-L. Transcatheter closure of single muscular ventricular septal defects using the Amplatzer Muscular VSD Occluder: initial results and technical considerations. *Cathet Cardiovasc Interv* 2000;49:167-72.
- Hijazi ZM, Hakim F, Hawelwh AA et al. Catheter closure of perimembranous ventricular septal defects using the new Amplatzer Membranous VSD Occluder: initial clinical experience. *Cathet Cardiovasc Intervent* 2002; 56: 508-15.
- Pedra CAC, Pedra SRF, Esteves CA, Chamié F, Christiani LA, Fontes VF. Transcatheter closure of perimembranous ventricular septal defects. *Expert Review Cardiovasc Therapy* 2004; 2: 89-100.
- Pedra CAC, Pedra SRF, Esteves CA et al. Percutaneous closure of perimembranous ventricular septal defects with the Amplatzer device: technical and morphologic considerations. *Cathet Cardiovasc Interv* 2004;61:403-10.

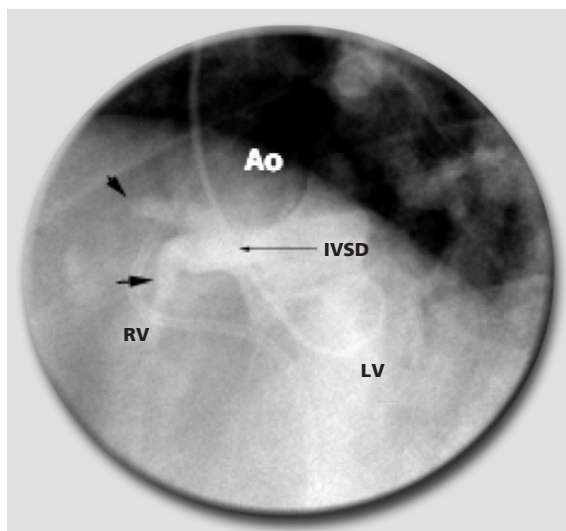


Fig. 5 - Selective ventriculography showing a complex IVSD with presence of aneurysm formation and two long orifices.