

## Giant Left Atrium

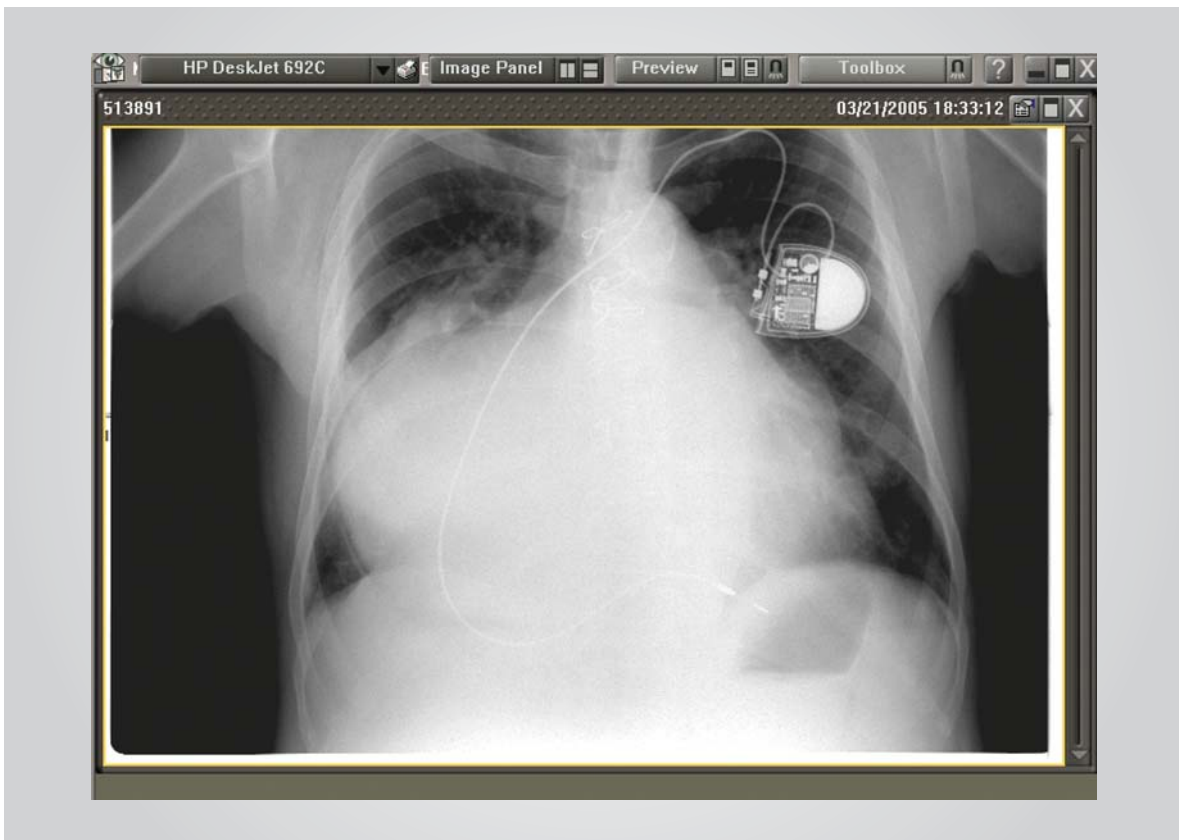
Flávio Justo Maciel, Lucas de Lima Carvalho, Mário Osvaldo Vrandecic  
*Biocor Instituto de Doenças Cardiovasculares - Belo Horizonte, MG - Brazil*

Male, 57 years old was submitted to mitral bioprosthesis implantation 10 years ago. Hospitalization in March, 2005, reporting Class IV congestive heart failure (CHF) and advanced (atrioventricular) AV blocking (which required the implantation of a pacemaker). Auscultation was compatible with severe mitral failure.

*Echocardiogram* - Left ventricle reporting normal dimensions (VDF-141ml; VSF-44ml). Ejection fraction -0.69. Thickened mitral bioprosthesis, allowing important regurgitation. Left atrium dimensions very

enlarged (diameter = 159mm). Two masses suggestive of thrombus adherent to the atrial wall (54x70mm and 49x73mm).

*Comment* - The relevance of the present case is left atrium unusual volume. Beloved author Charles K. Friedberg<sup>1</sup>, in his *Diseases of the Heart*, reported the largest atrium he had ever seen (in an autopsy), with 1 liter volume capacity. In our case, roughly calculating the atrium as a sphere, we reached the extravagant volume of 2.1 liters.



### REFERENCE

1. Friedberg CK. *Enfermedades del Corazón*. México: Ed. Interamericana; 1968.

**Mailing Address:** Flávio Justo Maciel • Rua Maranhão, 904/302 – 30150-330 – Belo Horizonte, MG - Brazil  
 E-mail: fjmaciell@cardiol.br

*Received on 06/03/05 • Accepted on 06/08/05*