

Stent Dislodgement in the Treatment of Left Main Coronary Artery Dissection

Gilberto Guilherme Ajjar Marchiori^{1,2}, George César Ximenes Meireles¹, Sérgio Kreimer¹, Micheli Zanoti Galon^{1,2}
Hospital do Servidor Público Estadual – IAMSPE¹; Instituto do Coração da FMUSP², São Paulo, SP – Brazil

Introduction

Accidental dissection of the left main coronary artery (LMCA) is one of the most feared complications of intervention cardiologists. If not promptly diagnosed and treated with myocardial revascularization, it can have severe consequences. The incidence of dissection occurring during catheter-based procedures is lower than 0.1%, but can reach 1.05% in patients with LMCA obstructive lesions¹⁻⁴.

Immediate percutaneous intervention with stent implantation seems to be the appropriate management of moderate to large accidental LMCA dissection, as shown in the present case.

Case report

The patient is a 72-year-old female, who sought the emergency department reporting fatigue on moderate exertion for one week and oppressive non-radiating chest pain at rest for 10 minutes. Her arterial blood pressure was 110/70 mmHg, her heart rate, 90 bpm, and oxygen saturation, 91%. Her cardiopulmonary auscultation was normal. She had dyslipidemia, a risk factor for coronary artery disease. She reported previous surgery for melanoma and using sertraline (50 mg per day) for depression.

Her resting electrocardiogram revealed sinus rhythm and T-wave inversion in V4-V6. The transthoracic echocardiogram showed left ventricular (LV) relaxation abnormality and ejection fraction of 68%. The submaximal treadmill test performed three months before hospitalization suggested myocardial ischemia, coronary angiography being, then, indicated.

Radial coronary angiography (introducer sheath and 6F catheters) was performed, and, on the first contrast medium injection, no obstructive lesion was observed (Figure 1A). On the second contrast medium injection, dissection of the initial

and middle portion of the LMCA was evidenced (Figure 1B). The patient had no complaints. She received 600 mg of clopidogrel, and, because of the aspect of the dissection, a 4.0x12 mm Driver® stent (Medtronic-AVE, Santa Rosa, CA, USA) was implanted and deployed at 20 atm. Then, postdilatation with a 4.5x12 mm noncompliant balloon (Quantum, Boston Scientific Inc, Natick, USA) was performed at 20 atm (Figures 1 C, D, and E). On angiographic control immediately after implantation, migration of the expanded stent into the guiding catheter was observed (Figure 1F). Another Driver® stent (Medtronic-AVE), 4.0x18 mm, was implanted in the LMCA at 20 atm, being followed by postdilatation with a 5.0x12 mm semi-compliant balloon (Quantum, Boston Scientific Inc, Natick, USA) at 12 atm. The final angiographic control showed optimal stent implantation in the LMCA (Figures 2 A, B and C).

The expanded stent inside the guiding catheter migrated until the right brachial artery, where it was successfully implanted with a 5.0x12 mm balloon at 8 atm (Figures 2 D and E). On post-implantation right brachial arteriography, the aspect of the stent implanted was excellent, with no sign of dissection and TIMI 3 flow (Figure 2 F). After the end of the procedure, right coronary angiographies were performed, showing no arterial obstruction. Left ventriculography showed a normal left ventricle.

The patient was transferred to the Coronary Unit (CoU) and medicated as follows: acetylsalicylic acid, 100 mg / day; clopidogrel, 75 mg/day; atorvastatin, 20 mg/day; atenolol, 50 mg/day; and subcutaneous enoxaparin, 60 mg every 12 hours. The patient progressed uneventfully, being discharged from the CoU on the fourth day. She showed neither elevation of necrosis markers nor electrocardiographic abnormalities. She was sent to the ward, where she remained asymptomatic, being discharged from the hospital after three days.

The patient was clinically reassessed two months after LMCA stent implantation, and remained asymptomatic.

Keywords

Coronary Vessels; Dissection; Angioplasty; Balloon, Coronary; Stents.

Mailing Address: George César Ximenes Meireles •
Rua Sena Madureira, 1265/102, Vila Clementino, Postal Code 04021-051, São Paulo, SP – Brazil
E-mail: gcxm@cardiol.br, george.ximenes@terra.com.br
Manuscript received September 17, 2012, revised manuscript December 21, 2012, accepted January 08, 2013.

DOI: 10.5935/abc.20130119

Discussion

The present case differs from those of LMCA dissection reported in the medical literature because of the migration of the LMCA stent into the guiding catheter after dilatation, and also because of the solution of implanting the migrated stent in the right brachial artery.

Arterial hypertension, extensive atherosclerosis, Marfan's syndrome, bicuspid or unicuspid aortic valve, and cystic medial necrosis are clinical conditions that predispose to

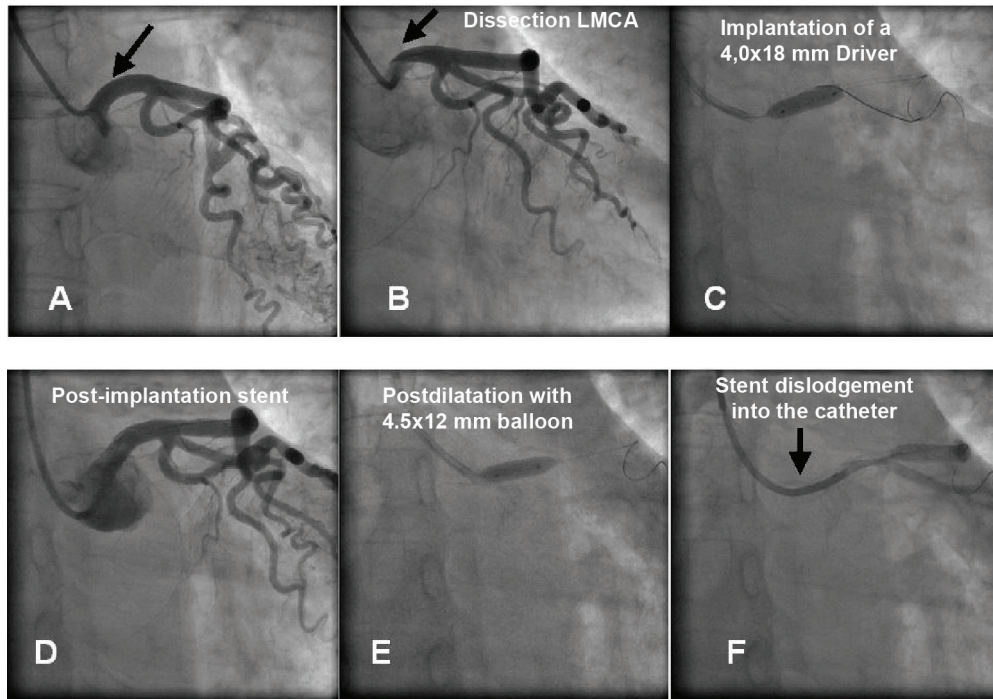


Figure 1 – A: LMCA without dissection (arrow); B: LMCA with dissection (arrow); C: Implantation of a 4,0x12 mm Driver® stent in the LMCA; D: Immediate post-implantation; E: Postdilatation with 4.5x12 mm balloon; F: Stent dislodgement.

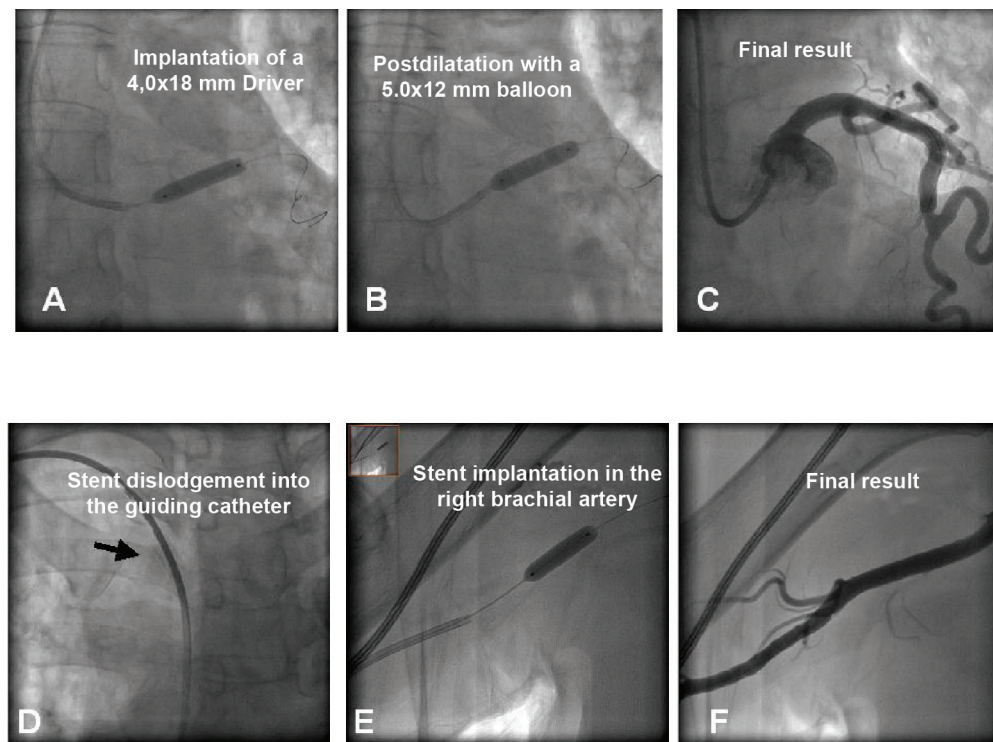


Figure 2 – A: Implantation of a 4,0x18 mm Driver® stent in the LMCA; B: Postdilatation with a 5.0x12 mm balloon; C: Final result; D: Stent dislodgement into the guiding catheter; E: Stent implantation in the right brachial artery; F: Final result.

Case Report

LMCA dissection. Ulceration of the atherosclerotic plaque might serve as an entry point for the pulsatile blood flow⁵.

Accidental LMCA dissection results from damage to the arterial wall during the following: excessive and careless manipulation of the catheter; changing catheters to others with greater curvature or of different forms (Amplatz), to overcome difficulties found in LMCA catheterization due to its unusual location at the aortic root; vigorous contrast medium injection with the catheter in a noncoaxial alignment; use of hard-tip catheters; and deep intubation of the catheter^{1,4}.

The present case was managed by an experienced interventional cardiologist, through the radial route, with a 6F soft-tip diagnostic catheter (Merit Medical Systems, South Jordan, Utah, USA). He experienced no difficulty to catheterize the left coronary artery, which had no apparent atherosclerosis. The probable mechanism of dissection was the noncoaxial alignment of the catheter tip during contrast medium injection.

During the postdilatation with non-compliant short balloon (12 mm), the stent implanted in the LMCA migrated into the guiding catheter. Stent dislodgement can be secondary to marked coronary angulation, coronary calcification, underestimation of stent size, inadequate coronary predilation, and direct stent. In the case reported, stent dislodgement might have resulted from the small size of the stent as compared to the vessel diameter (stent diameter/vessel diameter < 1), since a larger stent was not available. Thus, total apposition of the stent to the vessel wall was not obtained, with subsequent stent dislodgement to the guiding catheter during postdilatation. Implantation of the dislodged stent in the right brachial artery prevented the need for surgical withdrawal of the stent, because, as it was expanded, its withdrawal through the radial introducer would not be possible.

In accidental LMCA dissection, the clinical findings can vary, depending on the antegrade flow, from asymptomatic hemodynamically stable patients with TIMI 3 flow to cardiogenic shock with total occlusion of the left coronary artery. The treatment can be conservative, with percutaneous coronary intervention or coronary artery bypass graft surgery, according to clinical findings⁵. In hemodynamically stable patients with small dissection and no coronary flow impairment, expectant management can be adopted⁵. Conversely, to hemodynamically unstable patients with involvement of the aorta 40 mm or more from the coronary ostium, intervention is indicated^{5,6,7}. However, even in hemodynamically stable asymptomatic patients with TIMI 3 flow, the clinical findings might deteriorate rapidly due to the progression of the dissection with flow impairment or local thrombus formation, a situation

that requires rapid revascularization by use of percutaneous or surgical intervention. The intraaortic balloon can be used to stabilize the patient in shock, but is clearly contraindicated in the presence of concomitant aortic dissection⁸.

The immediate percutaneous coronary intervention with stent implantation seems to be an appropriate alternative to coronary artery bypass graft surgery in case of iatrogenic LMCA dissection, because it is a rapid and effective treatment^{3,9}. The medical literature lacks data allowing us to infer the advantage of the pharmacological stent over the conventional one in that situation, mainly in cases whose coronary arteries are normal on coronary angiography.

Small series of patients with iatrogenic LMCA dissection have shown, in the long run (12 to 30 months), survival rates of approximately 90% and restenosis rates at six months ranging from 0% to 30%^{3,9,10}. It is worth emphasizing the importance of strict clinical control and angiographic control six months after conventional stent implantation, because LMCA restenosis might manifest as sudden death.

Conclusion

Coronary stent implantation is an appropriate alternative to treat accidental LMCA dissection; the underestimation of stent size regarding the LMCA diameter might lead to stent dislodgement after dilatation.

Author contributions

Conception and design of the research: Marchiori GGA; Acquisition of data: Marchiori GGA, Galon MZ; Writing of the manuscript: Meireles GCX; Critical revision of the manuscript for intellectual content: Meireles GCX, Galon MZ, Kreimer S; Image: Kreimer S.

Potential Conflict of Interest

No potential conflict of interest relevant to this article was reported.

Sources of Funding

There were no external funding sources for this study.

Study Association

This study is not associated with any post-graduation program.

References

1. Kovac JD, de Bono DP. Cardiac catheter complications related to left main stem disease. *Heart*. 1996;76(1):76-8.
2. Dunning DW, Kahn JK, Hawkins ET, O'Neil WW. Iatrogenic coronary artery dissections extending into and involving the aortic root. *Catheter Cardiovasc Interv*. 2000;51(4):387-93.
3. Cheng CI, Wu CJ, Hsieh YK, Chen CJ, Chen SM, Yang CH, et al. Percutaneous coronary intervention for iatrogenic left main coronary artery dissection. *Int J Cardiol*. 2008;126(2):177-82.
4. Ertas G, Ural E, Van Der Giessen WJ. Successful stenting of catheter-induced unprotected left main coronary artery dissection. *Cardiovasc J Afr*. 2012;23(4):e6-7.
5. Awadalla H, Sabet S, Sebale A, Rosales O, Smalling R. Catheter-induced left main dissection incidence, predisposition and therapeutic strategies experience from two sides of the hemisphere. *J Invasive Cardiol*. 2005;17(4):233-6.

6. Ahmar W, Malaiapan Y, Meredith IA. Transradial retrieval of a dislodged stent from the left main coronary artery. *J. Invasive Cardiol.* 2008;20(10):545-7.
7. Al-Saif SM, Liu MW, Al-Mubarak N, Agrawal S, Dean LS. Percutaneous treatment of catheter-induced dissection of the left main coronary artery and adjacent aortic wall: a case report. *Catheter Cardiovasc Interv.* 2000;49(1):86-9.
8. Ochi M, Yamauchi S, Yajima T, Kutsukata N, Bessho R, Tanaka S. Aortic dissection extending from the left coronary artery during percutaneous coronary angioplasty. *Ann Thorac Surg.* 1996;62(4):1180-2.
9. Onsea K, Kayaert P, Desmet W, Dubois CL. Iatrogenic left main coronary artery dissection. *Neth Heart J.* 2011;19(4):192-5.
10. Lee SW, Hong MK, Kim YH, Park JH, Rhee K, Lee CW, et al. Bail-out stenting for left main coronary artery dissection during catheter-based procedure: acute and long-term results. *Clin Cardiol.* 2004;27(7):393-5.