

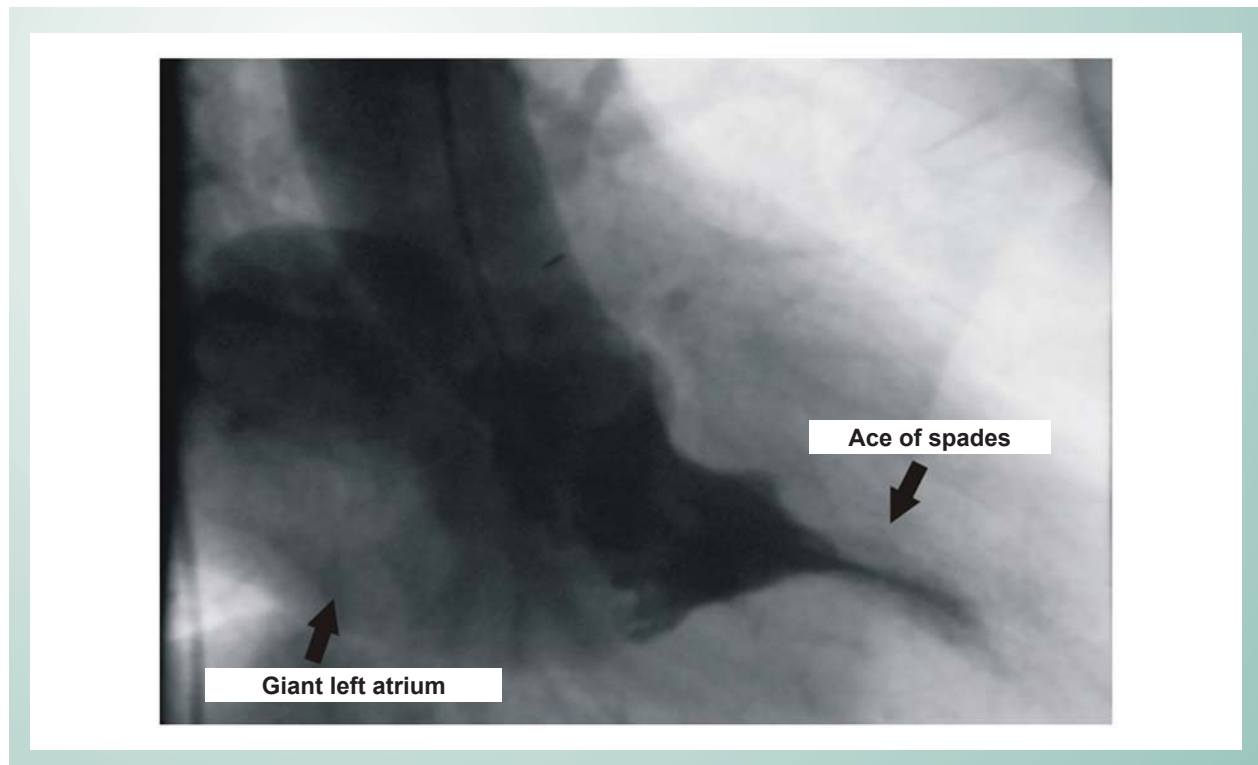
## Apical Hypertrophic Cardiomyopathy with Giant Left Atrium

Uygar Cagdas Yuksel, Hurkan Kursaklioglu, Turgay Celik

Departamento de Cardiologia – Faculdade de Medicina – Academia Militar de Medicina Gulhane – Ankara, Turquia

A 69 year old female patient with apical hypertrophic cardiomyopathy and rheumatic mitral valve disease was scheduled for mitral valve replacement, and underwent a coronary angiography for preoperative evaluation of the coronary arteries. The left ventriculogram revealed a spade deformity (ace of spades) which is typical for apical hypertrophic cardiomyopathy (Fig. 1). No intraventricular

or subaortic pressure gradient was present. A giant left atrium due to severe mitral regurgitation was also observed. The mediolateral diameter of the left atrium was 12cm, according to the measurement taken during the transthoracic echocardiography. A giant left atrium is defined as an atrium greater than 8cm and is a typical finding in patients with rheumatic mitral valve disease and severe regurgitation<sup>1</sup>.



**Fig. 1** - Left ventriculogram through a right anterior oblique projection showing the ace of spades configuration, typical of apical hypertrophic cardiomyopathy and a giant left atrium due to severe mitral regurgitation.

### Key words

Cardiomyopathy, hypertrophic; heart atria; mitral insufficiency.

### Reference

1. Fasseas P, Lee-Dorn R, Sokil AB, VanDecker W. Giant left atrium. *Tex Heart Inst J.* 2001;28:158-9.

---

#### Mailing Address: Uygar Cagdas Yuksel •

Department of Cardiology – Gulhane School of Medicine – 06018 – Etlik – Ankara, Turkey

E-mail: ucyuksel@yahoo.co.uk

Manuscript received September 6, 2006; revised manuscript received September 6, 2006; accepted September 14, 2006.