

## Double Valve Replacement Due to Dysfunction Secondary to Carcinoid Tumor

Paulo Manuel Pêgo-Fernandes, André Micheletto Laurino, Danilo de Souza Ferronato, Frederico Perego Costa, Ramez Anbar, Fabio Biscegli Jatene

Hospital Sírio-Libânes, São Paulo, SP – Brazil

### Introduction

Neuroendocrine tumors are rare malignancies capable of secreting endocrine substances such as serotonin<sup>1,2</sup>. The gastrointestinal tract is the preferred site for the primary tumor<sup>2,3</sup>.

The symptoms of carcinoid syndrome (clinical manifestation of disseminated disease), such as flushing (facial erythema), diarrhea, hypotension and bronchospasm are related to the vasoactive activity of compounds secreted by the tumor and are often its first presentation<sup>3</sup>.

During the disease progression, 50% of patients have carcinoid heart disease<sup>4</sup>, which affects the right heart valves, leading to valvular dysfunction and right heart failure<sup>3</sup>. The left side of the heart is seldom affected, due to the filtration of tumor products in the lung<sup>5</sup>.

Treatment evolution has increased the survival of patients with carcinoid syndrome and, therefore, carcinoid heart disease has become a determining factor for prognosis. The patient with the disease has a survival rate of 31% in a three-year period, when compared to the 68% of individuals with no echocardiographic evidence of cardiac involvement<sup>5</sup>.

The therapeutic approach to heart disease is complex. The surgical risk, though declining, is still significant due to the patient's health status. The heart valve replacement or its "repair" has been increasingly accepted for carcinoid heart disease. Reports in the literature show an increase in mean survival and considerable decrease or elimination of symptoms<sup>6,7</sup>.

At the echocardiography, the typical image is leaflet thickening caused by carcinoid plaque deposition in the endocardium of the tricuspid and pulmonary valves, coaptation failure, valve insufficiency and/or stenosis, the enlarged right chambers, leading to right heart failure<sup>8</sup>.

Evora et al<sup>9</sup> observed that there is no national publication about the surgical treatment of carcinoid heart disease. This

finding suggests a low prevalence of the disease, or that it is underdiagnosed. As it is a rare disease, there is scarce literature on it. As there are no reported cases, we believe our case report may help in the recognition of certain patterns of the disease, contributing to a better prognosis of these patients.

### Case Report

Patient GN, male, diagnosed with carcinoid syndrome in 2002, when he was 48 years old. At the time, the diagnosis was confirmed by laparoscopy and liver biopsy, which showed the presence of a primary neuroendocrine undefined tumor of intestine and liver metastasis. The patient was submitted to treatment with MIBG I131 (metaiodo-benzylguanidine iodine-131, a radioisotope used for the treatment of carcinoid tumors) therapeutic cycles.

In 2008, when he was 54 years, a right hepatic artery embolization was performed and treatment with Sandostatin® was initiated. At 55 years, he was submitted to surgery for resection of the primary tumor and liver metastasis. Immunohistochemistry analysis revealed enteric lesions and hepatic nodules consistent with neuroendocrine carcinoma.

In 2010, in addition to symptoms of carcinoid syndrome, he presented with dyspnea on mild exertion; at physical examination, lower-limb edema was observed, as well as systolic murmur 5 +/ 6 + at the base of the heart, more accentuated in the tricuspid area.

An echocardiogram was requested and it showed mild right ventricular dilation and moderate dilation of the right atrium, thickened tricuspid valve with reduced leaflet mobility, leading to leaflet coaptation failure and significant regurgitation; the pulmonary valve had a reduced opening and moderate regurgitation, RV-PA systolic gradient up to 40 mmHg. The diagnosis of right heart failure due to carcinoid heart disease was confirmed.

The choice of therapy for cardiac disease was double valve replacement, aortic bioprosthesis number 21 in the pulmonary position and mitral number 33 in the tricuspid position. A transesophageal echocardiography performed on the seventh postoperative day showed that the bioprostheses, tricuspid and pulmonary, had normal function. The patient progressed satisfactorily and was discharged on the 13<sup>th</sup> postoperative day.

The anatomopathological analysis, stained with hematoxylin and eosin, showed fibrous thickening of the tricuspid and pulmonary valves with areas of hyalinization, myxoid degeneration and proliferation of newly formed vessels focally, absence of thrombi or vegetations and no malignancy (Figures 1 and 2).

### Keywords:

Carcinoid Tumor; Carcinoid Heart Disease; Surgery; Heart Valve Diseases.

**Mailing Address: Paulo Manuel Pêgo Fernandes •**

Av. Dr. Enéas de Carvalho Aguiar, 44 Bl. 2, 2 andar, sala 9, Cerqueira César, Postal Code 05403-000, São Paulo, SP – Brazil

E-mail: paulo.fernandes@incor.usp.br

Manuscript received May 14, 2012; revised manuscript October 17, 2012; accepted October 19, 2012.

DOI: 10.5935/abc.20130072

The echocardiogram performed two years after the surgery, in 2012, showed a slightly enlarged right atrium and a normal right ventricle. The tricuspid valve prosthesis showed no regurgitation, with peak diastolic gradients of 11 mmHg and mean of 4 mmHg. The pulmonary valve prosthesis showed peak systolic gradient of 26 mmHg and a mean of 17 mmHg; native valves with normal texture and mobility and normal ventricular function.

The patient had mild lower-limb edema and diarrhea associated with fluid intake, symptoms related to carcinoid disease.

## Discussion

In a previous study of the Mayo Clinic, 26 patients with carcinoid heart disease underwent surgical treatment of cardiac valves. Although mortality was higher, late survival (8 of 26 patients) resulted in a considerable decrease (2 patients) or elimination (6 patients) of symptoms<sup>7</sup>. The largest study was

published by Møller et al<sup>6</sup>, in which the author assessed 200 patients with carcinoid heart disease during two decades (1980-2000). In this retrospective analysis, 87 patients with carcinoid heart disease underwent surgery. Perioperative mortality was reduced from 25% to 9% in the last five years of this study.

During the same period, the percentage of patients with carcinoid heart disease that underwent the surgery increased from 18% to 64%. Thus, surgery showed an increase in mean survival of 1.5 years to 4.4 years over the past decades. The surgery, which in the 80s was performed in severely symptomatic patients only, is currently proposed for those that are only mildly symptomatic, as it is clear that the heart failure progression further increases mortality<sup>6</sup>.

We report a case in which the patient, who had a neuroendocrine tumor diagnosed in 2002, developed the carcinoid syndrome and thus underwent the available clinical and pharmacological treatment for the tumor and its recurrences. In 2010, at age 56, he was diagnosed with carcinoid heart disease

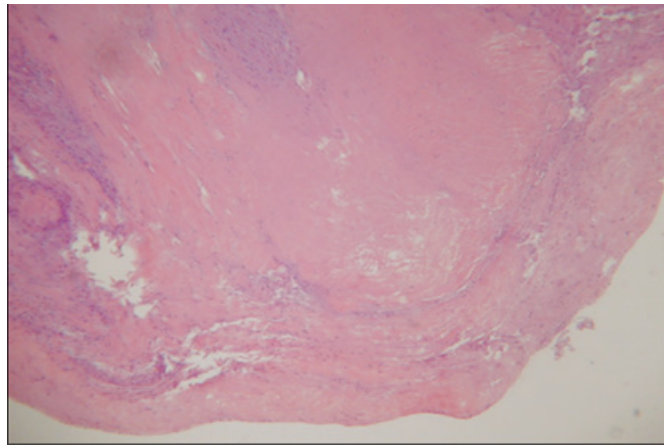


Figure 1 – Fibrous thickening of the tricuspid valve. Magnification: 100X. Hematoxylin-eosin staining.

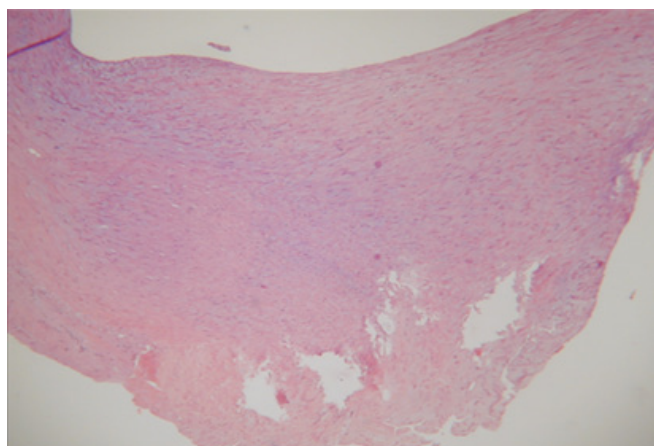


Figure 2 – Pulmonary valve showing fibrous thickening and hyalinization areas. Magnification: 100X. Hematoxylin-eosin staining.

## Case Report

with right heart valve involvement and we chose to perform valvular surgery due to the picture of right heart failure.

We chose to use the bioprosthesis due to the great possibility that this patient would require further surgical interventions in other organs, which could have been hampered if mechanical prostheses were used, with the consequent need for anticoagulation. Mabvuure et al<sup>10</sup> warn that the process of destruction of the native valve observed in patients with carcinoid disease does not continue at the same level in the bioprosthesis.

Upon returning, in 2012, the patient showed improvement of heart failure symptoms, with significant improvement in dyspnea, lower-limb edema and had episodes of diarrhea associated with fluid intake, which are tumor-related symptoms. In this case, the surgical correction, despite its risks, was important to improve survival and quality of life of this patient.

In our country, Evora et al<sup>9</sup> have drawn attention to the fact that in 2011 there were no national publications on the surgical treatment of carcinoid heart disease. Within this context, we believe that our case report may contribute to the recall of this diagnosis and the possibility of its surgical treatment.

### Conclusion

The improvement of oncologic treatment of neuroendocrine tumors has increased the survival of patients with this disease. Thus, an increasing number of these patients have shown heart

valve involvement. We reported the case of a patient who developed severe pulmonary and tricuspid valve disease and underwent double valve replacement with good outcome up to 2 years of follow up.

### Author contributions

Conception and design of the research and Critical revision of the manuscript for intellectual content: Pêgo-Fernandes PM, Jatene FB; Acquisition of data: Pêgo-Fernandes PM, Laurino AM, Ferronato DS, Costa FP, Anbar R; Analysis and interpretation of the data: Pêgo-Fernandes PM, Laurino AM, Ferronato DS, Costa FP, Anbar R; Writing of the manuscript: Laurino AM, Ferronato DS.

### Potential Conflict of Interest

No potential conflict of interest relevant to this article was reported.

### Sources of Funding

There were no external funding sources for this study.

### Study Association

This study is not associated with any post-graduation program.

### References

1. Bhattacharyya S, Davar J, Dreyfus G, Caplin ME. Carcinoid heart disease. *Circulation*. 2007;116(24):2860-5.
2. Bernheim AM, Connolly HM, Hobday TJ, Abel MD, Pellikka PA. Carcinoid heart disease. *Prog Cardiovasc Dis*. 2007;49(6):439-51.
3. Modlin IM, Lye KD, Kidd M. A 5-decade analysis of 13,715 carcinoid tumors. *Cancer*. 2003;97(4):934-59.
4. Ferrans VJ, Roberts WC. The carcinoid endocardial plaque; an ultrastructural study. *Hum Pathol*. 1976;7(4):387-409.
5. Pellikka PA, Tajik AJ, Khandheria BK, Seward JB, Callahan JA, Pitot HC, et al. Carcinoid heart disease: clinical and echocardiographic spectrum in 74 patients. *Circulation*. 1993;87(4):1188-96.
6. Møller JE, Pellikka PA, Bernheim AM, Schaff HV, Rubin J, Connolly HM. Prognosis of carcinoid heart disease: analysis of 200 cases over two decades. *Circulation*. 2005;112(21):3320-7.
7. Connolly HM, Nishimura RA, Smith HC, Pellikka PA, Mullancy CJ, Kvols LK. Outcome of cardiac surgery for carcinoid heart disease. *J Am Coll Cardiol*. 1995;25(2):410-6.
8. Moerman VM, Dewilde D, Hermans K. Carcinoid heart disease: typical findings on echocardiography and cardiac magnetic resonance. *Acta Cardiol*. 2012;67(2):245-8.
9. Evora PR, Basseto S, Augusto VS, Vicente WV. Carcinoid heart valve disease: still a puzzle and a challenge. *Arq Bras Cardiol*. 2011;97(5):e111-2.
10. Mabvuure N, Cumberworth A, Hindocha S. In patients with carcinoid syndrome undergoing valve replacement: will a biological valve have acceptable durability? *Interact Cardiovasc Thorac Surg*. 2012;15(3):467-71.