

Hypertrophic Cardiomyopathy and Tachyarrhythmias Detected by a Pacemaker

Adrian Baranchuk¹, Syamkumar Divakaramenon², Sebastian Ribas², Carlos A. Morillo²

Arrhythmia Service, Kingston General Hospital, Queen's University¹; Arrhythmia Service, Hamilton General Hospital, McMaster University² - Canada

A 56-year-old man came to the Pacemaker Clinic for his regular pacemaker control. He had experienced a syncopal episode in the previous week. He had a previous diagnosis of non-obstructive hypertrophic cardiomyopathy. Due to a previous syncope and documented 2:1 infrahisian block, a dual-chamber permanent pacemaker had been implanted a few years before. The device was interrogated, showing several ventricular high rate episodes. A careful analysis of the stored intracardiac electrograms showed ventricular tachycardia (VT) with 2:1 ventriculoatrial conduction. The following presentation discusses the alternative diagnosis and clinical management in an unusual diagnosis of VT in the presence of non-obstructive hypertrophic cardiomyopathy.

Case Report

A 56-year-old man came to the pacemaker clinic for his regular pacemaker control. The patient had presented a syncopal episode in the previous week, with no prodromes, while he was carrying heavy weight. He felt nauseated after recovering.

He had had a previous diagnosis of non-obstructive hypertrophic cardiomyopathy and the last echocardiogram performed in 2003 showed: IVS: 1.9; LV post wall: 1.0; LVDD: 4.8; LVSD: 2.6; LA: 5.0; Ejection Fraction: 46%. Due to a previous syncopal episode, an electrophysiology study was carried out in 2003, which showed: AH (nodal conduction): 155 ms; HV (distal conduction): 60 ms in conducted beats; 2:1 infrahisian block; non-inducible VT (with a protocol of 3 extra-stimuli). A cardiac angiogram showed normal coronary arteries. The patient was treated with 50 mg of Metoprolol, twice a day and subsequently, a dual-chamber permanent pacemaker was implanted (Kappa 931, Medtronic).

At the time of the consultation, the physical examination was unremarkable. His 12-lead ECG showed atrial sensing with ventricular pacing. The device was interrogated, showing

Key Words

Cardiomyopathy, hypertrophic; tachycardia; pacemaker, artificial.

Mailing address: Adrian Baranchuk•

76 Stuart St, K7L 2V7, Kingston - Canada

E-mail: barancha@kgh.kari.net

Manuscript received August 16, 2007; revised manuscript received October 25, 2007; accepted January 24, 2008.

a pacemaker programmed in the DDD mode, with a lower rate of 60 bpm, pacing thresholds (atrial and ventricular) less than 1 V, atrial impedance 599 Ω , ventricular impedance 550 Ω . Atrial and ventricular sensing were programmed in unipolar configuration. Several ventricular high rate episodes were detected with more than 300.000 premature ventricular beats (PVCs). It is remarkable that the ventricular rate during the episodes was almost double than the atrial rate. The stored intracardiac electrograms obtained during the episode are shown in Figure 1.

The diagnosis of VT with 2:1 ventriculo-atrial conduction was attained (Fig. 2) and the patient was referred for an upgrade to an implantable cardioverter-defibrillator (ICD) insertion. The ICD upgrade was performed with no complications. The old ventricular pacing lead was abandoned. The new ventricular lead and the old atrial lead were connected to the ICD.

Discussion

This is an interesting case that assesses the diagnostic possibilities of the new pacemakers. The diagnostic ability of the current pacemakers allows intracardiac electrograms to be stored for further analysis¹. The perfect symptom-rhythm correlation (syncope during the ventricular high-rate episode) was paramount in the clinical decision-making.

The analysis of the intracardiac electrograms revealed initiation of the tachycardia with a PVC (Fig.1, black arrow), followed by a rapid ventricular rhythm at 320 ms. The ventriculo-atrial conduction (VA) is 2:1, thus supraventricular arrhythmias were unlikely (Fig. 2). The ventricular channel (Fig. 2; arrows) showed atrial activation following ventricular activation every other beat.

Atrial flutter with 2:1 conduction and conducted atrial fibrillation were ruled out because the tachycardia started with a PVC and there were more ventricular beats than atrial beats. In addition, conducted atrial fibrillation is usually irregular and this tachycardia was regular. The fact that the patient was, most of the time, in atrial sensing-ventricular pacing (due to high-degree AV block) did not completely rule out conducted supraventricular rhythms; however, it made this possibility less likely to occur.

Pacemaker tachycardia could not be suspected because there was not a paced rhythm during tachycardia (a necessary requisite to suspect it).

The decision to upgrade the pacemaker to an ICD was based on a series of facts: 1) The presence of structural heart disease (non-obstructive hypertrophic cardiomyopathy); 2)

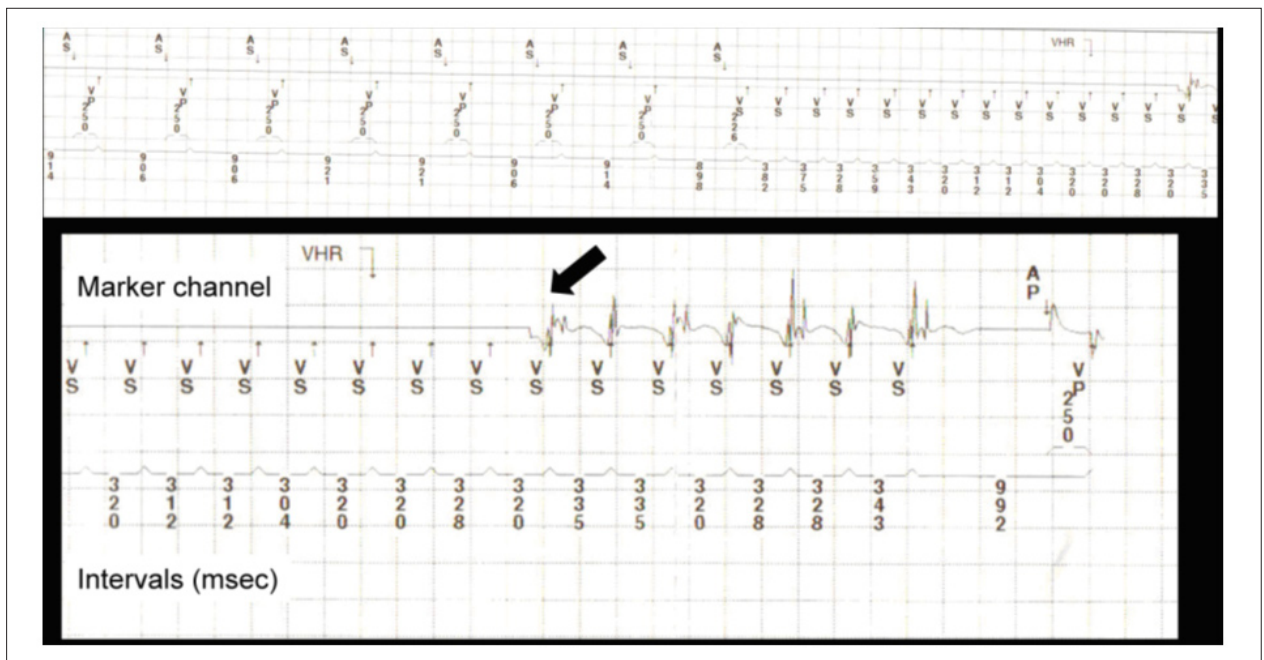


Figure 1 - Intracardiac electrograms; AS - atrial sensing; AP - atrial pacing; VP - ventricular pacing; VS - ventricular sensing.

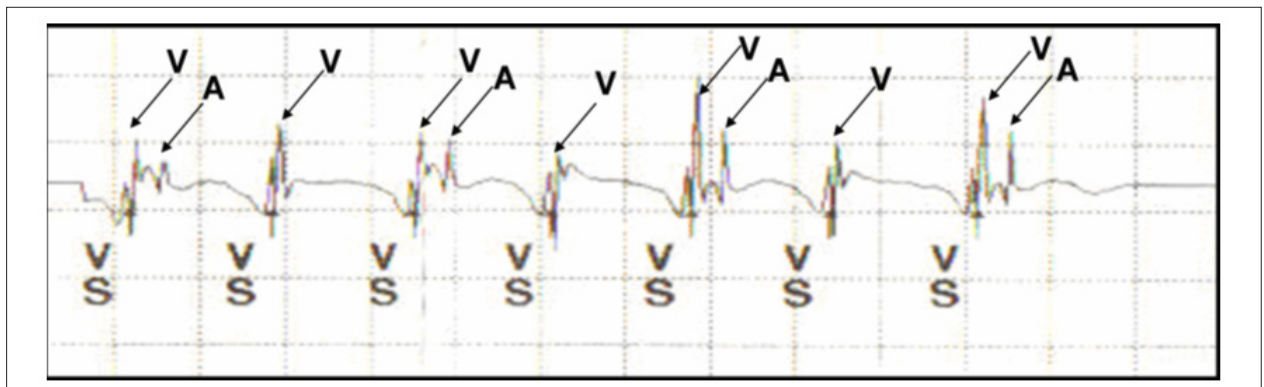


Figure 2 - Ventricular tachycardia with 2:1 VA conduction; VS - ventricular sensing; V - ventricular electrogram; A - atrial electrogram.

The clinical presentation (syncope) and 3) The documented sustained VT (through the analysis of the electrograms stored in the pacemaker).

In this clinical scenario, the presence of syncope alone increases the risk of sudden death by 5-fold². In addition, VT was detected through the analysis of the intracardiac electrograms (increasing the risk of sudden death by almost two-fold). An electrophysiology study may not add up more relevant information. The ICD implantation is preferred over antiarrhythmic drugs for high-risk patients (HCM, syncope, VT)².

Conclusion

The current generation of pacemakers facilitates the diagnosis of complicated clinical situations. Proper interpretation of the stored intracardiac electrograms may help in the diagnosis of life-threatening ventricular arrhythmias. The identification

of ventricular tachycardia in a patient with non-obstructive hypertrophic cardiomyopathy and syncope has helped in the decision-making of upgrading a pacemaker to an implantable cardioverter-defibrillator.

Potential Conflict of Interest

No potential conflict of interest relevant to this article was reported.

Sources of Funding

There were no external funding sources for this study.

Study Association

This study is not associated with any post-graduation program.

Case Report

References

1. Willems R, Morck ML, Exner DV, Rose SM, Gillis AM. Ventricular high-rate episodes in pacemaker diagnostics identify a high-risk subgroup of patients with tachy-brady syndrome. *Heart Rhythm*. 2004; 1: 414-21.
2. Elliott PM, Poloniecki J, Dickie S, Sharma S, Monserrat L, Varnava A, et al. Sudden death in hypertrophic cardiomyopathy: identification of high risk patients. *J Am Coll Cardiol*. 2000; 36: 2212-8.