

Percutaneous Mitral Valvuloplasty Complicated by Cardiac Tamponade in a Pregnant Patient

Luís Seca, Marco Costa, Nuno Quintal, A.M. Leitão Marques
Centro Hospitalar de Coimbra, Coimbra, Portugal

The occurrence of hemopericardium with cardiac tamponade is a complication of percutaneous balloon mitral valvuloplasty (BMV) which, although uncommon, may have severe maternal and fetal consequences. This article describes a case of cardiac tamponade following BMV in a 28-year-old woman with severe rheumatic mitral stenosis in the 20th week of gestation.

Introduction

Rheumatic mitral stenosis is still the most frequently found valvular disease among pregnant women¹. The hemodynamic changes during pregnancy, with increased heart rate and blood volume, lead to a worsened transmitral pressure gradient and concomitant increased pulmonary artery pressure, with subsequent reduction in exercise tolerance and higher risk of pulmonary edema. Therapeutic intervention thus becomes necessary to relieve symptoms. When refractory to drug therapy, repair of the mitral valve stenosis is justified. To date, BMV is considered the treatment of choice for severe mitral stenosis complicating the normal course of pregnancy, provided that it occurs in the presence of a favorable heart valve anatomy². However, this is not a risk-free procedure.

The BMV register of the National Heart, Lung and Blood Institute (NHLBI) classified the procedure-related complications in major (death, shock, severe mitral regurgitation, systemic embolism, cardiac tamponade, emergency surgery, and acute myocardial infarction), with an overall incidence of complications of approximately 12%, and minor complications (vasovagal reaction, prolonged hypotension, arrhythmia requiring treatment, interauricular septal defect). Cardiac perforation and subsequent tamponade occurred in approximately 4% of the patients, and was the most frequent cause of death during catheterization³.

Key Words

Dilatação com balão, tamponamento cardíaco, gestantes, derrame pericárdio

Mailing Address: Luís Seca •

Avenida Camilo 324 1^oDT 4300-095, Porto, Portugal

E-mail: luisseca@gmail.com

Manuscript received November 11, 2007; revised manuscript received February 09, 2008; accepted March 07, 2008.

Case Report

A 28-year-old black female patient, born in Guinea-Bissau, G₀P₀ in the 20th week of gestation, in NYHA class III heart failure, presenting palpitations and syncope (2 episodes) and echocardiographic diagnosis of severe mitral stenosis since November 2006, was admitted to our service in January 2007 to undergo BMV.

In 2004, she had been admitted to another hospital for cardioembolic stroke with right hemiparesis which was completely reverted after three months of physical therapy. The pregnancy progressed uneventfully until the date of admission to our service.

She took oral contraceptives until the beginning of pregnancy and at the moment of admission she was not taking any medication.

Her cardiac examination was unremarkable except for a diastolic murmur in the mitral area, best heard at the apex in the left lateral position, and accentuated S2 in the pulmonic area.

Laboratory test findings were within normal limits. Electrocardiography revealed normal sinus rhythm, heart rate of 75 bpm and left atrial hypertrophy.

A transthoracic echocardiogram performed prior to the valvuloplasty revealed severe mitral stenosis with mitral valve area of 0.6cm², and no valve regurgitation. The left atrium had a 51.2-mm diameter and the mild tricuspid regurgitation allowed the estimate of the systolic pressure in the pulmonary artery at 64mmHg. She also presented a mild pericardial effusion.

The procedure was performed under sedation and with the help of transesophageal echocardiography in order to reduce time of radiation exposure and to control the result after dilation (Figure 1).

An Inoue balloon was introduced via venous circulation up to the right atrium, then crossed the interatrial septum, and was positioned through the stenosed mitral valve. Inflation and quick deflation dilated the stenosis by splitting the fused commissures (Figure 1).

An immediate improvement of the hemodynamic parameters was observed, with reduction of the left intra-atrial pressure, of the transmitral gradient, and of the pulmonary artery pressure. The valve area increased from 0.6 cm² to 1.8 cm².

Approximately 4 hours after the procedure, the patient developed hypotension and depression of consciousness.

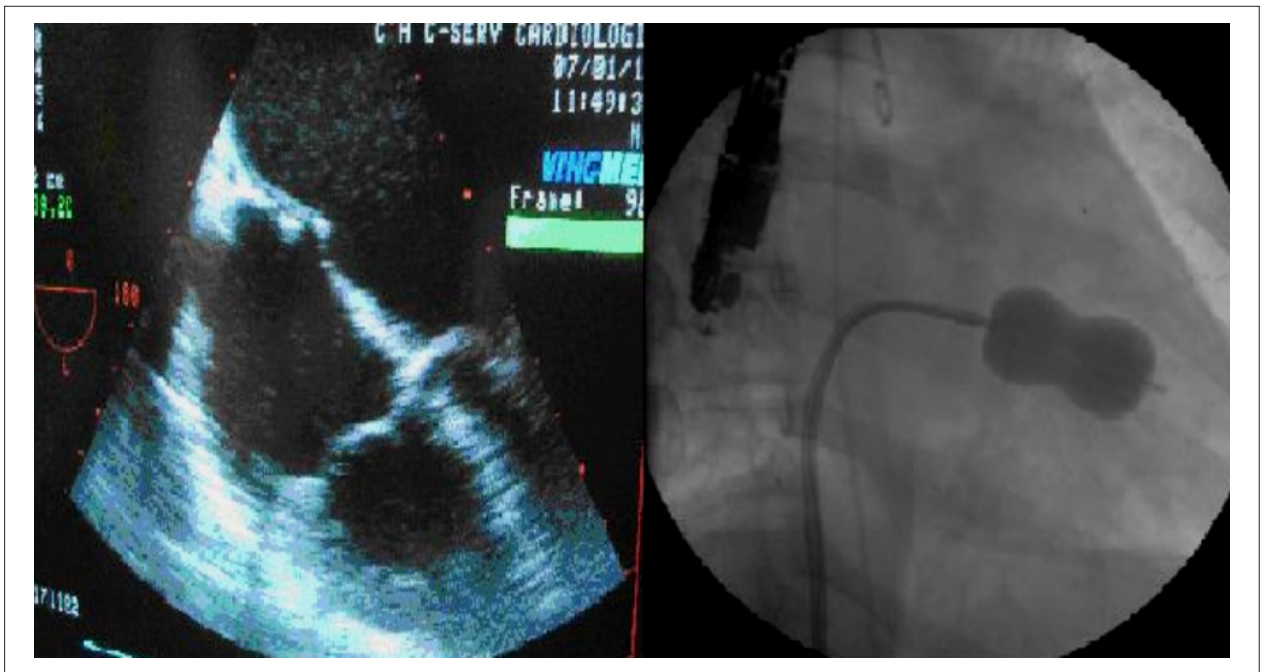


Figure 1 - Left – Transesophageal echocardiogram showing the moment of transeptal puncture; Right – Inflation of the Inoue balloon

A transthoracic echocardiogram was performed: cardiac tamponade with the presence of moderate pericardial effusion and collapse of the right chambers was confirmed (Figure 2).

Pericardiocentesis was performed and approximately 450cc were drained. Control blood count showed anemia of 8.8 g/dl, which was promptly corrected with transfusion of 2 units of red cells.

At hospital discharge, the patient was asymptomatic and hemodynamically stable. She underwent a new transthoracic

echocardiography which confirmed increased mitral valve area (1.8cm²) and reduction of PASP (59 mmHg), with mild mitral regurgitation.

Three months after hospitalization, when she was in the 32nd week of gestation, the patient was reevaluated in an outpatient visit. She referred significant improvement of the symptoms (NYHA class I). Transthoracic echocardiogram showed a 42-mm-diameter left atrium, mitral valve area of 1.5 cm², and mild to moderate mitral regurgitation; PASP was 53 mmHg.

The end of the pregnancy was uneventful and she had a cesarean delivery with no complications. The newborn was a healthy boy weighing 3125g with one-minute and five-minute APGAR scores of 8 and 10, respectively. After delivery the patient remained in NYHA class I.

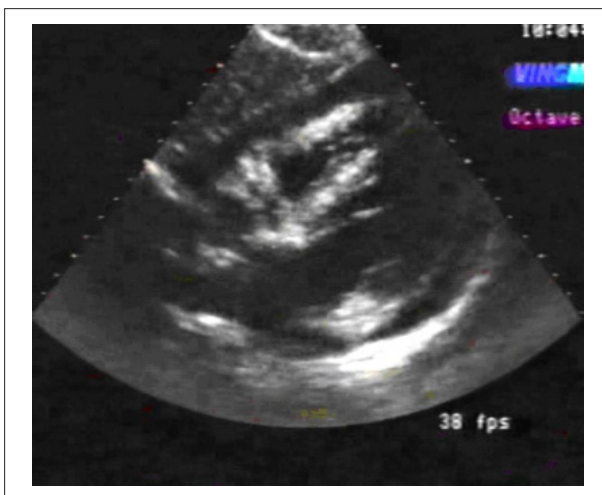


Figure 2 - Pericardial effusion with diastolic collapse of the right chambers

Discussion

Maternal mortality in pregnant women with mitral valve stenosis is of approximately 1% and varies according to the NYHA functional class (0.4% in class I or II; 6.8% in class III or IV)⁴. On the other hand, fetal mortality increases with the deterioration of the maternal functional capacity, reaching 30% in the presence of class IV heart failure¹.

Mitral stenosis during pregnancy is a complex problem, given that drug therapy is frequently ineffective. Thus, some type of intervention becomes necessary to increase the valve area.

Surgical open or closed commissurotomy may be performed, but still leads to a significant risk of fetal death⁵. Although surgical commissurotomy during pregnancy does

Case Report

not increase the maternal risk, approximately 10-37% preterm deliveries and a fetal mortality rate of 5-15% have been described after closed commissurotomy. With open commissurotomy, the fetal mortality rate may range from 6% to 33%, due to the additional harmful effects of extracorporeal circulation². In this context, BMV emerges as an alternative to the clinical approach.

In the past years, BMV has been performed during pregnancy with excellent short-term outcomes in selected patients with mitral stenosis⁶. Studies with long-term follow-up have also demonstrated a reduction in both fetal and maternal complications⁷. Fetal risks associated with radiation exposure should be reduced in the first half of pregnancy with uterine shielding and, if possible, with the help of transesophageal echocardiography, as was used in this case.

In most series, mortality associated with BMV ranges between 0-3%, and the major causes of death (not only in the case of pregnancy) are cardiac tamponade, mitral regurgitation and deterioration of the patient's general health status⁸.

The occurrence of hemopericardium, with rates between 1-3%, is related to transeptal puncture or left ventricular apex perforation with the guidewire or the balloon itself⁹. Perforations of the right atrial appendage are usually not very severe, and in the majority of cases are resolved with pericardiocentesis and administration of protamine. LV lacerations, however, result

in immediate hemodynamic deterioration and usually require emergency corrective surgery¹⁰.

Conclusions

Percutaneous transeptal mitral commissurotomy is an effective and safe procedure when performed by experienced cardiologists. Considering the peculiarities of symptomatic mitral stenosis in the pregnant woman, this type of procedure is considered the treatment of choice because it is less aggressive to the fetus in comparison with the surgical option. However, we must be aware of some complications that may arise, and therefore careful surveillance is fundamental after the procedure.

Potential Conflict of Interest

No potential conflict of interest relevant to this article was reported.

Sources of Funding

There were no external funding sources for this study.

Study Association

This study is not associated with any graduation program.

References

1. Brady K, Duff P. Rheumatic heart disease in pregnancy. *Clin Obstet Gynecol*. 1989;32(1):21-40.
2. de Souza JA, Martinez EE Jr, Ambrose JA, Alves CM, Born D, Buffolo E, et al. Percutaneous mitral balloon valvuloplasty in comparison with open mitral valve commissurotomy for mitral stenosis during pregnancy. *J Am Coll Cardiol*. 2001;37(3):900-3.
3. The National Heart, Lung and Blood Institute Balloon Valvuloplasty Registry Participants. Complications and mortality of percutaneous balloon mitral commissurotomy: a report from the National Heart, Lung and Blood Institute Balloon Valvuloplasty Registry. *Circulation*. 1992;85:2014-24.
4. Metcalfe J, Ueland K. Maternal cardiovascular adjustments to pregnancy. *Prog Cardiovasc Dis*. 1974; 16(4): 363-74
5. Chambers CE, Clark SL. Cardiac surgery during pregnancy. *Clin Obstet Gynecol*. 1994; 37(2): 316-23.
6. Martinez-Reding J, Cordero A, Kuri J, Martinez-Rios MA, Salazar E. Treatment of severe mitral stenosis with percutaneous balloon valvotomy in pregnant patients. *Clin Cardiol*. 1998; 21: 659-63.
7. Gupta A, Lokhandwala YY, Satoskar PR, Salvi VS. Balloon mitral valvotomy in pregnancy: maternal and fetal outcomes. *J Am Coll Surg*. 1998; 187: 409-15
8. Harrison JK, Wilson JS, Hearne SE, Bashore TM. Complications related to percutaneous transvenous mitral commissurotomy. *Cathet Cardiovasc Diagn*. 1994;(Suppl. 2):52-60.
9. Berland J, Gerber L, Gamra H, Bousadia H, Cribier A, Letac B. Percutaneous balloon valvuloplasty for mitral stenosis complicated by fatal pericardial tamponade in a patient with extreme pulmonary hypertension. *Cathet Cardiovasc Diagn*. 1989;17:109-11.
10. Pan M, Medina A, Suárez de Lezo J, Hernandez E, Romero M, Pavlovic D, et al.. Cardiac tamponade complicating mitral balloon valvuloplasty. *Am J Cardiol*. 1991;68:802-5.