

## Multicavitated Left Atrial Myxoma with Dual Coronary Supply

Mariana Couto Vasconcelos and Luís Filipe Vilela Pereira Macedo

Hospital São João, Porto - Portugal

A 68-year-old man was admitted for a syncope episode. A transesophageal echocardiogram revealed a 30x35 mm multicavitated ovoid mass in the left atrium, attached to the interatrial septum, at the level of the fossa ovalis (A). The Doppler study identified blood flow in the mass, mainly during the diastole (B). Before surgical excision, a coronary angiography was performed, revealing blood flow from the conus branch of the right coronary artery and circumflex artery (C, D). Histology confirmed the diagnosis of myxoma. This paper describes a rare case of cystic-appearance cardiac myxoma with dual coronary supply.

### Potential Conflict of Interest

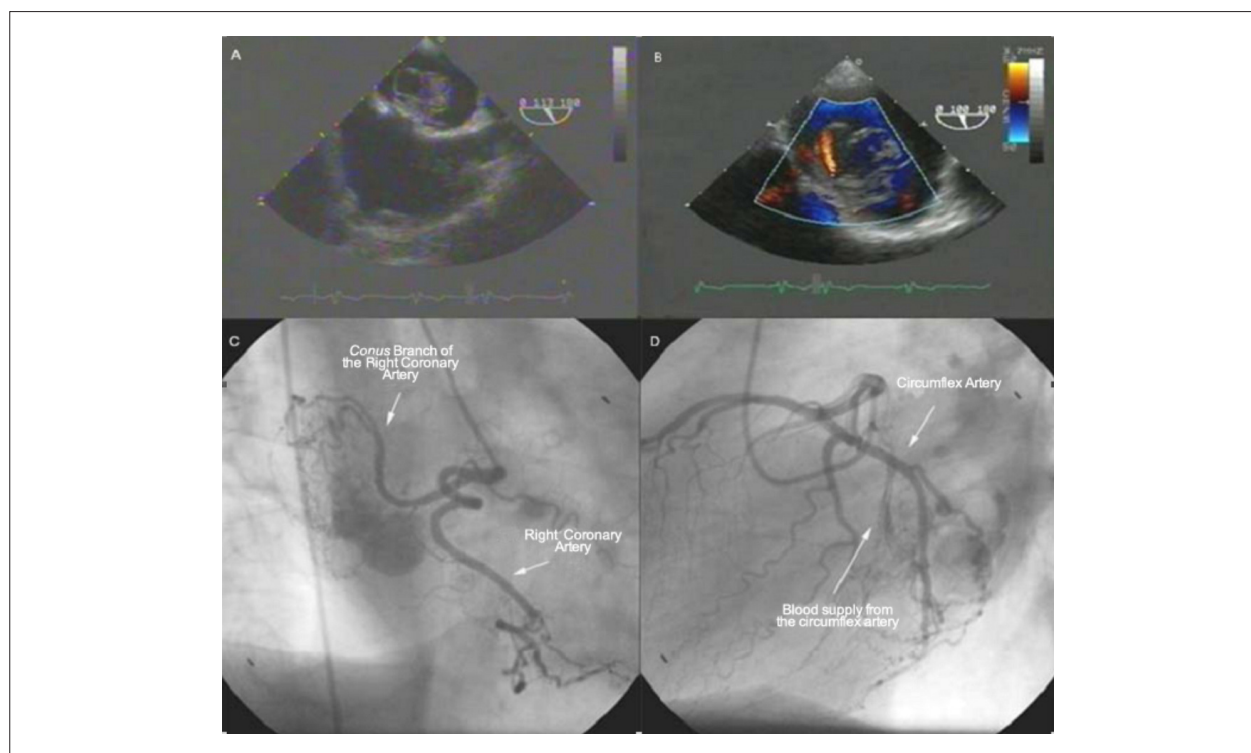
No potential conflict of interest relevant to this manuscript was reported.

### Sources of Funding

There were no external funding sources for this study.

### Study Association

This study is not associated with any graduation program.



### Key words

Cardiac myxoma; transesophageal echocardiography; coronary angiography.

Mailing address: Mariana Couto Vasconcelos •

Serviço de Cardiologia do Hospital São João - Alameda Professor Hernani Monteiro, 4200/319 - Porto - Portugal

E-mail: marvasmed@hotmail.com

Manuscript received April 22, 2007; revised manuscript received May 15, 2007; accepted May 15, 2007.