

Spontaneous Coronary Artery Dissection Causing Acute Coronary Syndrome

Francisco Juarez C. Vasconcelos Filho, José Eirirtonio F. Barreto, Raimundo Barbosa Barros, Imara C. L. Queiroz, Rômulo Ronkaly G. Lima
Hospital de Messejana - Fortaleza, CE - Brazil

A 34-year old, healthy man, reporting very strong, oppressive precordial pain, triggered by exertional exercise (soccer game), radiating to back and left arm, and associated to cold sweating for over 1 hour and with no alleviating factor. The patient denied risk factors for CAD. The patient looked for medical assistance only 2 days after the clinical event. Physical exam showed: BP: 120x 60mmHg; HR: 60b.p.m; Cardiac auscultation: regular rhythm, S4; Pulmonary auscultation: Normal. Electrocardiogram at admission showed: sinus rhythm with pathological Q waves in lower leads (D2, D3 and aVF) (Fig. 1). Laboratory exams at admission showed: CPK- 971 IU/L (normal < 195 IU/L); CK-MB- 59.7 IU/L (normal < 25IU/L); troponin- 2.15 ng/ml (normal < 0.1 ng/ml). Elective coronary angiography identified ulcerated plaque with thrombus adhered to its surface in the initial third of right coronary artery (Fig. 2.1.A) and spontaneous dissection in middle third of left anterior descending (Fig. 2.1.B); Left ventriculography showed: inferior hypokinesia (+++/+4). Atrium Flyer 3,5x16mm stent implantation was carried out in left anterior descending (Fig. 3.1.A) and infusion of IIb/IIIa inhibitor + IV heparin + clopidogrel

+ aspirin was indicated, with recommendation of a re-study 48 hours after therapeutic regimen. Control coronariography showed dissolution of intracoronary thrombus (Fig. 3.1.B).

COMMENTS

Coronary artery spontaneous dissection is a rare pathology that may lead to acute coronary syndrome with multiple clinical presentation spectra: angina pectoris, myocardium infarction or sudden death¹. One or two arteries may be injured in the same episode². It is more commonly found in groups of young people and it particularly focuses post-partum women³. Assumed etiology includes: Disruption of atherosclerotic plaque, exhausting physical exercise, pregnancy related hormonal influence, use of contraceptives; in some cases, risk factors cannot be identified.⁴ Treatment consists of: clinical and drug treatment, myocardial revascularization surgery, angioplasty with stent, and at times even heart transplant.⁵ As for the case in question, we have presented the use of a combination: drug therapy + stent.

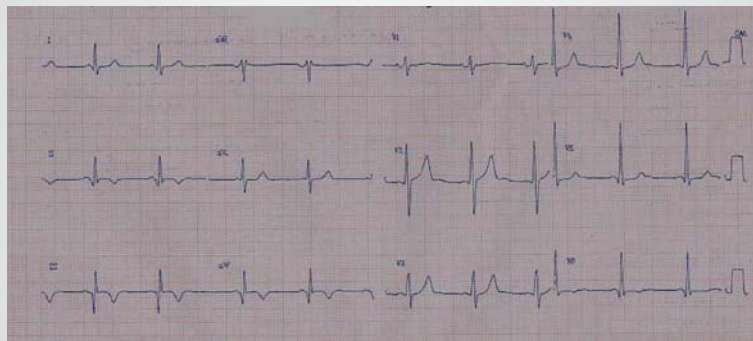


Fig. 1 – Electrocardiogram showing inactive area in inferior wall

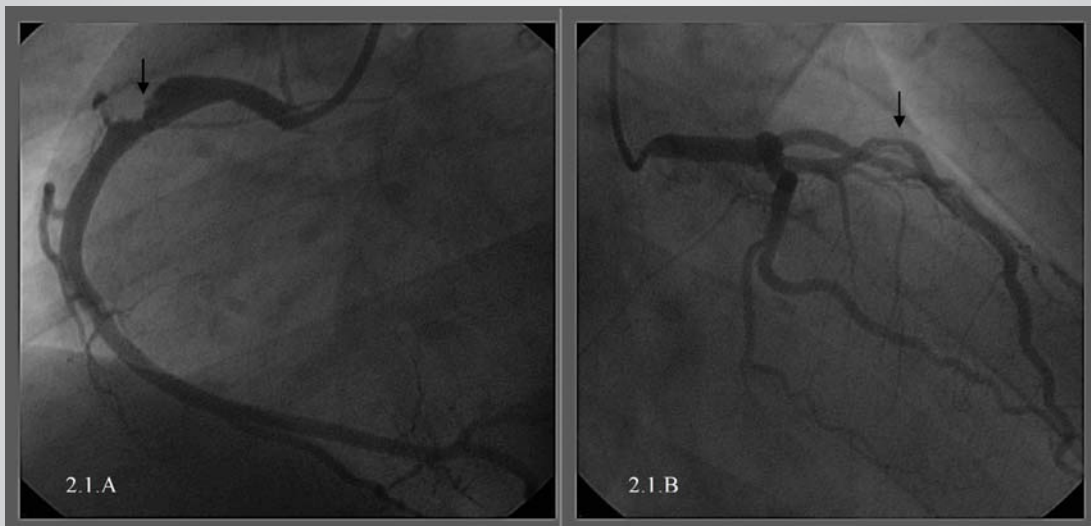

Fig. 2.1.A – Right coronary: Showing ulcerated plaque with thrombus adhered to its surface); **2.1.B** – Left anterior descending: showing spontaneous dissection in middle third) (Arrows)

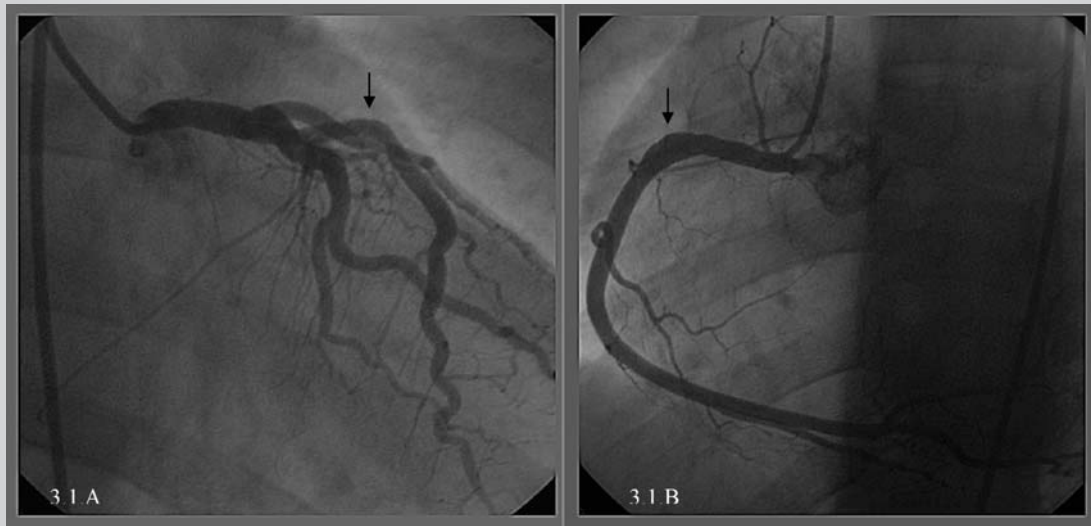


Fig. 3.1.A – Left anterior descending. Angio after stent implant); **3.1.B** - Right coronary control coronariography: showing dissolution of intracoronary thrombus (Arrows)

REFERENCES

1. Pita JP, Gonzalez NV, Alvarez LP, Rodríguez JMV, Beiras AC. Spontaneous coronary artery dissection: case reports. *Cath Cardiovasc Diagnosis* 1994; 32: 27-32.
2. Ooi A, Lavrsen M, Monro J, Langley SM. Successful emergency surgery on triple-vessel spontaneous coronary artery dissection. *Eur J Cardio Thoracic Surgery* 2004; 26: 447-449.
3. Rajiv D, Gurdev S, Henry F. Spontaneous coronary artery dissection: *The Clinical Spectrum. Angiology* 2002;53: 89-93.
4. Hering D, Piper C, Hohmann C, Schultheiss HP, Horstkotte D. Prospective untersuchung zu haufigkeit, pathogenese und therapie spontaner, koronarangiographisch diagnostizierter koronararteriendissektionen. *Z Kardiol* 1988; 87: 961-970.
5. Roig S, Gómez JA, Fiol M, Guindo J, Pérez J, Carrillo A et al. Spontaneous coronary artery dissection causing acute coronary syndrome: An early diagnosis implies a good prognosis. *Am J Emergency Med* 2003; 21: 549-551.