

## Three Cases of Hypertension and Renal Arteriovenous Fistula with a *de Novo* Fistula

Natalia Correa Vieira Melo, Juliano Sacramento Mundim, Elerson Carlos Costalonga, Antonio Marmo Lucon, Jose Luiz Santello, Jose Nery Praxedes

Departamento de Nefrologia e Departamento de Urologia da Faculdade de Medicina da Universidade de São Paulo, São Paulo, SP - Brazil

The Renal Arteriovenous Fistula (RAVF) is a rare and potentially reversible cause of hypertension and kidney and/or heart failure. The treatment of RAVF aims at preserving the most of the renal parenchyma and, concomitantly, eradicating the symptoms and hemodynamic effects caused by the RAVF. The present study reports three cases of RAVF, including one case of a *de novo* idiopathic RAVF, which presented with hypertension and kidney and/or heart failure and describes the therapeutic measures used to treat these patients as well as the outcomes.

### Introduction

The Renal Arteriovenous Fistula (RAVF) is a rare and potentially reversible cause of systemic arterial hypertension and also of kidney (KF) and/or heart failure (HF)<sup>1-4</sup>. The RAVF consists in one or more abnormal communications between the renal venous and arterial systems and can be congenital, idiopathic or acquired. The acquired form of the RAVF occurs more frequently (70-80% of the cases) and its incidence has increased due to the increasing number of kidney biopsies<sup>1,2,5</sup>. In the present study, we report three rare cases of hypertension, KF and/or HF secondary to RAVF, including one case of a *de novo* idiopathic RAVF. Additionally, we describe the therapeutic measures used to treat these patients and the results of the treatment.

### Case Reports

#### Case 1

An 18-year-old male, previously healthy individual presented, during a routine examination, abdominal murmur on the right side associated to blood pressure (BP) level of 150x100mmHg, using high doses of amlodipine and propranolol, as well as kidney function alteration (creatinine=1.5mg/dl). The computed angiotomography of the renal arteries showed high-flow RAVF, considered to be technically difficult to repair through transarterial embolization (Figure 1-A)<sup>5</sup>. Consequently, the surgical repair was carried out

through the ligation of the artery that fed the RAVF (Figure 1-B). On the 10<sup>th</sup> and 90<sup>th</sup> days of the postoperative period, the patient remained free from the abdominal murmur, with BP normalization (110 x 70 mmHg, without medication) and improvement in kidney function (creatinine=1.1mg/dl).

#### Case 2

A 38-year-old female patient was admitted with decompensated HF, refractory hypertension and abdominal murmur on the left. At the time, her BP was 190x80mmHg, using high doses of amlodipine, carvedilol and spironolactone. She did not have a previous history of kidney biopsy, trauma, tumors or other conditions that could justify the presence of an acquired RAVF. Kidney function was normal (creatinine=0.88mg/dl). A Doppler ultrasonography showed a single kidney to the left and RAVF. A computed angiotomography confirmed the communication between an artery and a left renal segmental vein. The patient was submitted to transarterial balloon embolization, with remission of hypertension and heart failure, without kidney function involvement. Two months after the procedure, the patient maintained normal kidney function (creatinine=0.9mg/dl) and normal BP (120x80mmHg, without medication).

#### Case 3

An 18-year-old male was admitted with refractory hypertension associated to abdominal murmur on the left. Laboratory assessment was normal, including rheumatologic tests, hemossedimentation rate and creatinine levels (1.0mg/dl). BP was 200x150mmHg, using high doses of propranolol, amlodipine, clonidine and hydrochlorothiazide. A renal arteriography showed a high-flow, posthilal RAVF in the lower left kidney pole (Figure 1-C). A transarterial balloon embolization was carried out with two balloons (Figure 1-D) and the patient achieved remission of the abdominal murmur as well as BP normalization (120x80mmHg, without medication). However, after one year, the patient again presented refractory hypertension (BP = 190x140mmHg, using clonidine, amlodipine, atenolol and clortalidone). Once more, laboratory assessment and kidney function were normal. The arteriography showed a high-output posthilal *de novo* RAVF, located in the upper left kidney pole. There was a new attempt of performing a transarterial balloon embolization, which was unsuccessful. Consequently, the patient was submitted to a left nephrectomy due to the impossibility of performing the surgical ligation of the artery that fed the RAVF. At the postoperative period, the patient presented

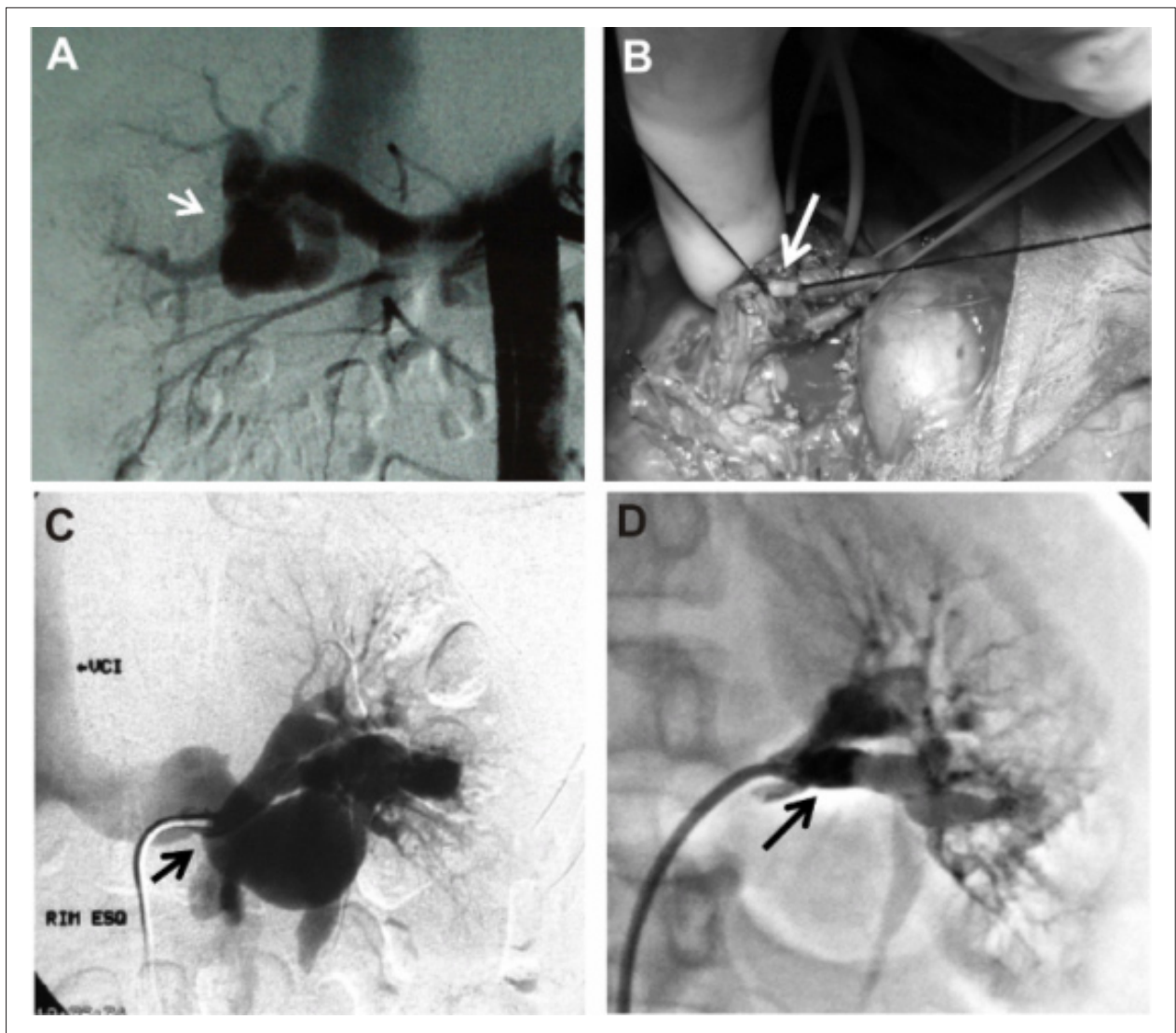
### Key Words

Arteriovenous fistula; hypertension; renal insufficiency; heart failure.

Mailing address:: Natalia Correa Vieira Melo•

Estrada do Arraial 2823/1101, Parnamirim, 52.051-380, Recife, PE - Brazil  
E-mail: nataliamelo@ymail.com

Manuscript received December 19, 2007; revised manuscript received May 06, 2008; accepted June 12, 2008.



**Figure 1** - A - Arteriography showing an extensive renal hilar formation that presents early arterial filling and rapid arterial emptying through the renal vein and inferior vena cava, corresponding to a renal arteriovenous fistula (RAVF – short white arrow); B - Surgical ligation of the renal artery branch responsible for supplying blood to the RAVF (long white arrow); C - Arteriography showing a large dilation of the renal vein due to a posthilum high-flow RAVF (short black arrow), in the lower pole of the left kidney; D - Arteriographic aspect after transarterial correction of the RAVF with two balloons (long black arrow).

normalization of BP (125x80mmHg, without medication) and creatinine level (1.0mg/dl). Ten years after the nephrectomy, the patient remains symptom-free, with no signs of *de novo* RAVF, with normal BP and kidney function and normal laboratory results.

## Discussion

The main objective of this study is to demonstrate RAVF as a rare cause of refractory hypertension, heart and/or kidney failure, which can be reverted with the treatment of the fistula. Additionally, we emphasize the possibility of a *de novo* idiopathic RAVF, in case of recurrence of the previously described symptom.

The RAVF can be congenital, acquired or idiopathic. The

congenital RAVF is the rarest form and is characterized by tangled vessels with multiple arteriovenous communications. The acquired form is the most common one and is secondary to kidney biopsy, surgery, trauma, tumor and/or inflammatory diseases. The idiopathic RAVF is acquired throughout life, but it does not have a defined etiologic factor<sup>1,2,5</sup>.

The acquired and idiopathic RAVF are characterized by large arteriovenous communications. The reduced venous vascular resistance of these communications causes decrease in the blood flow through the renal parenchyma, resulting in renal ischemia and consequent activation of the renin-angiotensin system, which favors the onset of hypertension and KF. Additionally, this “vascular robbery” phenomenon that occurs due to the RAVF increases the venous return and predisposes to high-output HF<sup>1-3,6</sup>.

## Case Report

The occurrence of *de novo* RAVF is rare, but it can happen when the underlying cause of the first RAVF is rheumatologic disease of tumor<sup>2</sup>. However, in the literature, there have been no previous reports of *de novo* idiopathic RAVF. The hypothesis that the RAVF was secondary to rheumatologic disease could be excluded in Case 3, considering that the rheumatologic tests, hemossedimentation rate and urinalysis remained normal throughout 10 years of follow-up. Similarly, no evidence of neoplasia was demonstrated in Case 3. Another hypothesis that can be ruled out, due to the high sensitivity of the arteriography for this diagnosis, is that the *de novo* fistula was not detected previously due to its small size at the time. Considering all the information, it is presumed that the *de novo* RAVF of Case 3 is really an idiopathic one.

Regarding the treatment of the RAVF, it aims at eradicating symptoms and hemodynamic effects caused by the fistula. Such treatment can be carried out by surgery or transarterial embolization<sup>3,5,7-9</sup>. There are several surgical techniques, such as the ligation of the artery that supplies blood to the fistula and even nephrectomy. Of these techniques, the ligation is the most beneficial one, as it allows a better preservation of renal parenchyma. However, this technique needs a detailed preoperative anatomical study in order to prevent the ligation of essential vessels that supply blood to the kidney<sup>5</sup>. Case 1, treated by the ligation method, showed BP normalization and progressive improvement in kidney function during the evolution.

The percutaneous treatment of the RAVF is currently considered the standard therapy. However, high-flow fistulas are still considered technically difficult to undergo transarterial

embolization, as the embolization agent can go through the RAVF and cause pulmonary/systemic embolism or even renal infarction. However, there have been recent reports of successful transarterial embolization of high-flow RAVF, as it occurred in Case 2 and in the first RAVF of Case 3<sup>3,8,9</sup>.

In conclusion, the recurrence of hypertension or kidney and/or heart dysfunction in patients with previously treated RAVF can indicate the onset of a *de novo* RAVF. Additionally, RAVF must be recalled as a potentially reversible cause of refractory hypertension, KF and/or high-output HF.

### Acknowledgements

We thank Dr. Alfredo Santana and Dr. Alexandre Pedreira for their invaluable comments in the preparation of this manuscript and Dr. Diego Ikejiri for the surgical photographs of Case 1.

### Potential Conflict of Interest

No potential conflict of interest relevant to this article was reported.

### Sources of Funding

There were no external funding sources for this study.

### Study Association

This study is not associated with any post-graduation program.

## References

1. Rezende LS, Ortiz MR, Paula SC, Gemelli JJ, Linhares A, Carvalho JGR. Idiopathic renal arteriovenous fistula causing renovascular hypertension and cardiac failure. *J Bras Nefrol*. 2002; 24 (2): 110-4.
2. Fogazzi GB, Moriggi M, Fontanella U. Spontaneous renal arteriovenous fistula as a cause of haematuria. *Nephrol Dial Transplant*. 1997; 12: 350-6.
3. Bates MC, Almekhi A. High-output congestive heart failure successfully treated with transcatheter coil embolization of a large renal arteriovenous fistula. *Catheter Cardiovasc Interv*. 2004; 63 (3): 373-6.
4. Barkhausen J, Verhagen R, Müller RD. Successful interventional treatment of renal insufficiency caused by renal artery pseudoaneurysm with concomitant arteriovenous fistula. *Nephron*. 2000; 85 (4): 351-3.
5. Osawa T, Watarai Y, Morita K, Kakizaki H, Nonomura K. Surgery for giant high-flow renal arteriovenous fistula: experience in one institution. *BJU Int*. 2006; 97 (4): 794-8.
6. Abassi ZA, Winaver J, Hoffman A. Large A-V fistula: pathophysiological consequences and therapeutic perspectives. *Curr Vasc Pharmacol*. 2003; 1 (3): 347-54.
7. Smaldone MC, Stein RJ, Cho JS, Leng WW. Giant idiopathic renal arteriovenous fistula requiring urgent nephrectomy. *Urology*. 2007; 69 (3): 576. e.1-3.
8. Lupattelli T, Garaci FG, Manenti G, Belli AM, Simonetti G. Giant high-flow renal arteriovenous fistula treated by percutaneous embolization. *Urology*. 2003; 61 (4): 837.
9. Bozgeyik Z, Ozdemir H, Orhan I, Cihangiroglu M, Cetinkaya Z. Pseudoaneurysm and renal arteriovenous fistula after nephrectomy: two cases treated by transcatheter coil embolization. *Emerg Radiol*. 2008; 15 (2): 119-22.