

Study of Breathing Pattern and Thoracoabdominal Movement in Mitral Valve Disease

Satiko Shimada Franco, Paula Nubiato Bardi, Max Grinberg, Maria Ignêz Zanetti Feltrim

Instituto do Coração (InCor) do Hospital das Clínicas da Faculdade de Medicina da Universidade de São Paulo (HC-FMUSP), São Paulo, SP - Brazil

Abstract

Background: patients with mitral valve disease can progress to having pulmonary congestion, which increases the work the respiratory muscles. This overload can change the breathing pattern with a predominance of rib cage displacement or presence of paradoxical movements.

Objective: a) to study the breathing pattern and thoracoabdominal movement of patients with mitral valve disease; b) to study the effect of body position on breathing parameters; and c) to correlate pulmonary hypertension with lack of coordination of thoracoabdominal movement.

Methods: the breathing pattern and thoracoabdominal movement of patients with mitral valve disease were assessed using respiratory inductive plethysmography during quiet breathing in the dorsal decubitus and sitting positions for two minutes. The variables assessed were tidal volume, breathing time and thoracoabdominal movement.

Results: of the 65 patients selected, 10 were excluded, 29 were in the mitral stenosis group and 26 in the mitral regurgitation group. Tidal volume, pulmonary ventilation and mean inspiratory flow significantly increased in the sitting position, with no difference between the groups. The thoracoabdominal movement remained coordinated in all groups and positions; except for five patients in the dorsal decubitus position, who lacked coordination (three in the mitral stenosis group; two in the mitral regurgitation group). A significant correlation with pulmonary artery pressure values was observed ($r = 0.992$; $p = 0.007$).

Conclusion: No difference in breathing pattern or thoracoabdominal movement was found between patients with mitral stenosis and regurgitation. The sitting position increased tidal volume without altering breathing times. The lack of coordination of the thoracoabdominal movement in the dorsal decubitus position was associated with pulmonary hypertension. (Arq Bras Cardiol 2012;99(5):1049-1055)

Keywords: Mitral valve stenosis; mitral valve regurgitation; hypertension pulmonary; respiratory insufficiency.

Introduction

Mitral stenosis (MS) is the valvular heart disease which causes a pressure gradient between the left atrium and left ventricle, leading to an increase in atrial pressure and pulmonary congestion. Its severity can be assessed by use of the valvular area (VA), mean transvalvular pressure gradient (TG), and pulmonary artery systolic pressure (PASP), parameters obtained by use of Doppler echocardiography¹.

In mitral regurgitation (MR), however, valvular incompetence occurs, causing blood regurgitation. The increase in volume overload leads to deterioration of compensatory mechanisms, lower compliance of the left atrium, and appearance of pulmonary hypertension², dyspnea or fatigue¹.

Thus, mitral valve impairment can induce ventilatory dysfunctions due to abnormalities in pulmonary circulation.

Those dysfunctions are characterized by small airways obstruction, a reduction in diffusion capacity and in dynamic pulmonary compliance, and an increase in ventilation in the upper zones of the lung³.

In addition, the breathing pattern (BP) and rib cage-abdominal movement are relevant factors in understanding and assessing pulmonary impairment. Healthy individuals are known to display abdominal dominant BP in the dorsal decubitus position and rib-cage dominant BP in the standing position⁴. These differences in the rib cage-abdominal contribution reflect the predominant action of the diaphragm in the dorsal decubitus position and the recruiting of the thoracic musculature in the standing position consequent to the effects of gravity on breathing mechanics^{4,5}.

In a study by Kawagoe et al.³, 62% of the patients with MS had abnormal BPs, which were associated with more severe valvular heart disease. Those authors have reported the presence of hyperperfusion in the upper zone of the lungs of those patients, suggesting that the BP can reflect changes in the regional distribution of ventilation and perfusion. However, we have no record of that condition in patients with a valvular heart disease, especially MR with surgical referral.

Mailing Address: Maria Ignêz Zanetti Feltrim •

Av. Dr. Enéas de Carvalho Aguiar, 44, 2º andar, Cerqueira César. Postal Code 05403-000, São Paulo, SP - Brazil

E-mail: mi.feltrim@incor.usp.br, mi.feltrim@yahoo.com.br

Manuscript received February 7, 2012; revised February 7, 2012; accepted August 24, 2012.

This study aimed at assessing the BP and thoracoabdominal movement of patients with MS and MR to evaluate: a) the differences in those parameters resulting from the underlying valvular heart lesion; and b) the effect of posture on the parameters analyzed. In addition, this study aimed to correlate pulmonary hypertension with the lack of coordination of thoracoabdominal movements.

Methods

This study was performed at the Instituto do Coração (InCor) of the Hospital das Clínicas of the Medical School of the Universidade de São Paulo (HC-FMUSP). All individuals had been diagnosed with mitral valve dysfunction (stenosis or regurgitation), with a referral for surgery, and neither moderate nor severe impairment of any other heart valve assessed by use of transthoracic echocardiography. The study protocol was approved by the Ethics Committee for the Analysis of Projects and Research of the HC-FMUSP (nº 1179/06). All participants provided written informed consent.

This study included patients of both gender, aged between 18 and 70 years, with New York Heart Association functional classes III and IV, who, due to clinical treatment, maintained hemodynamic stability and comfortable breathing at rest. The patients were divided into the following two groups: MS group (MSG), consisting of patients with $VA \leq 1.5 \text{ cm}^2$; and MR group (MRC), consisting of patients with non-ischemic MR.

From the medical records, personal and clinical data were collected, as were the following echocardiographic measures: VA; TG; PASP; and left ventricular ejection fraction (EF).

The BP and thoracoabdominal movement were recorded by use of respiratory inductive plethysmography (Respirace® - Noninvasive Monitoring Systems). The system comprises two bands with transducers, oscillator, calibrator, and recorder. Adequate bands for each patient were placed in their thoracic and abdominal regions and connected to the device (Figures 1 and 2). Calibration followed the protocol established. The patients were instructed to breathe quietly in each position. After stabilizing the breathing cycles, the curves corresponding to the abdominal movement, rib cage movement, and the integration of both movements (sum) were recorded for two minutes in the dorsal decubitus position (Figure 3). Then, with the patient comfortably reclined in the sitting position, feet planted on the floor and knees at a right angle, the respiratory cycles were recorded for two more minutes (Figure 4).

The records of the curves of the rib cage and abdominal movements, and that of their sum were entered into an information system specially developed for that purpose, and the following variables were obtained: tidal volume (VT) in milliliters; total breathing cycle time (TTOT) in seconds; inspiratory time (TI) in seconds; expiratory time (TE) in seconds; mean inspiratory flow (VT/TI) in milliliters per second; effective breathing time (TI/TTOT); respiratory frequency (f)

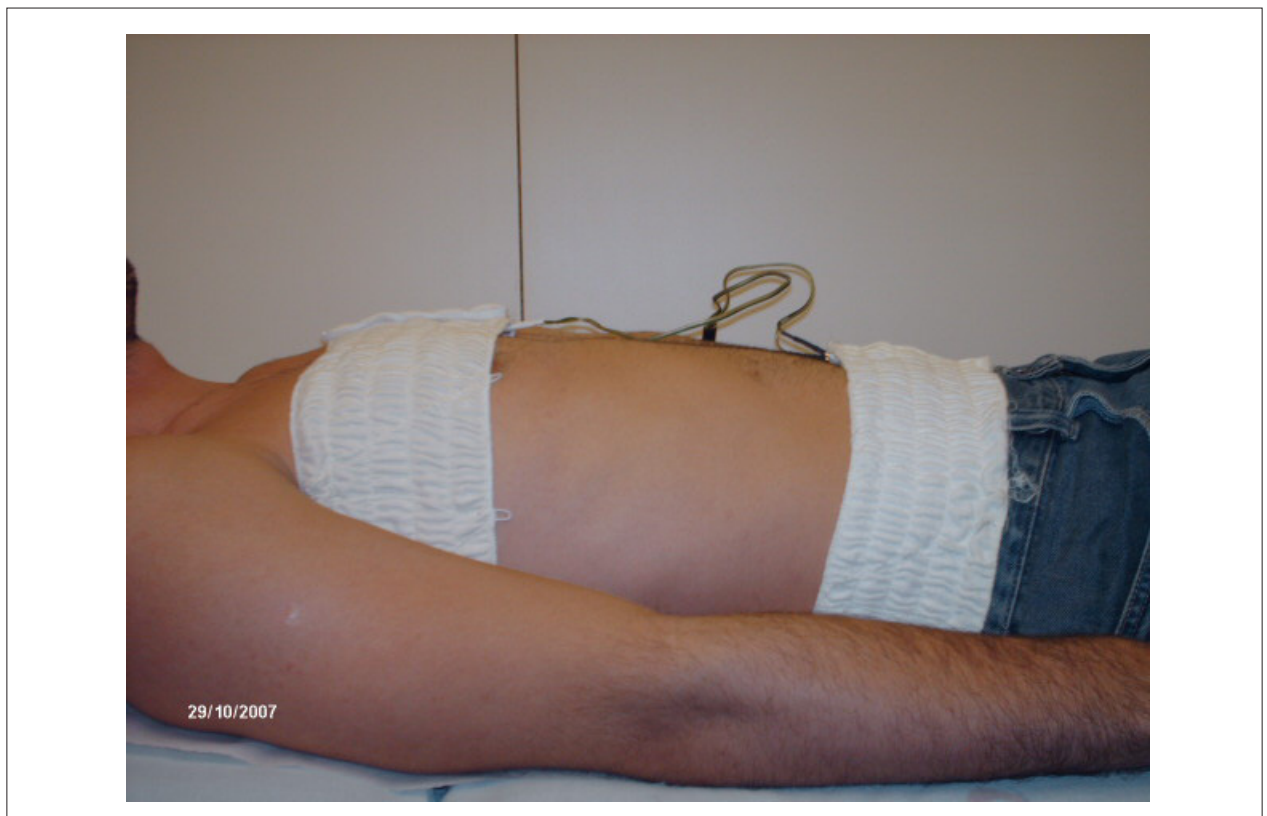

Figure 1 – Thorax and abdominal bands in the dorsal decubitus position

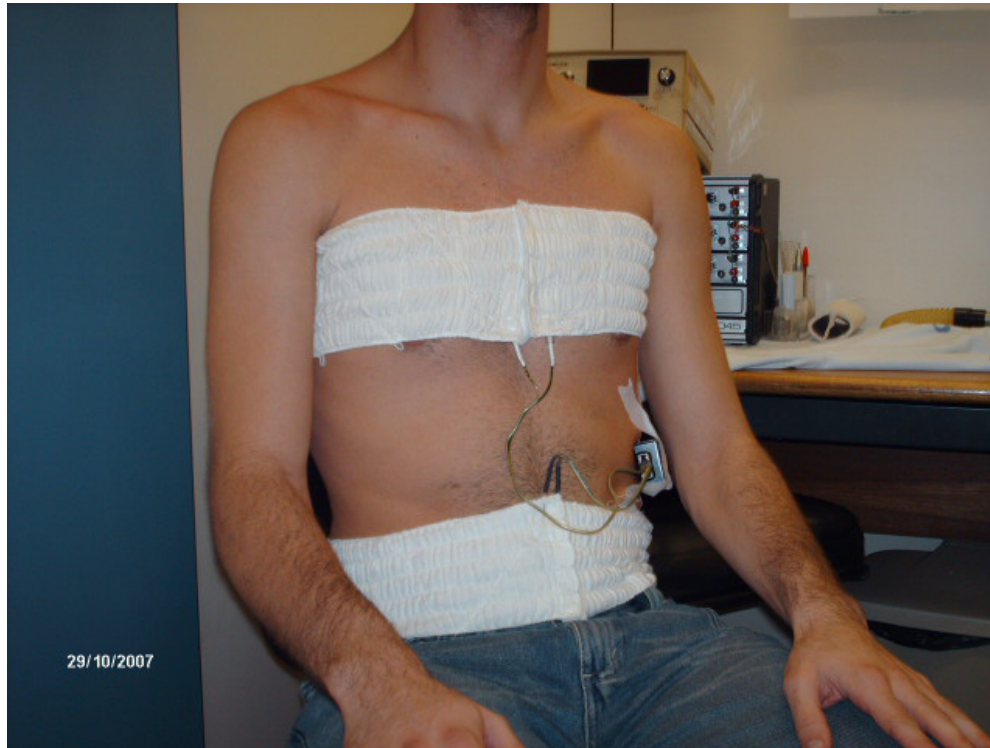

Figure 2 – Thorax and abdominal bands in the sitting position

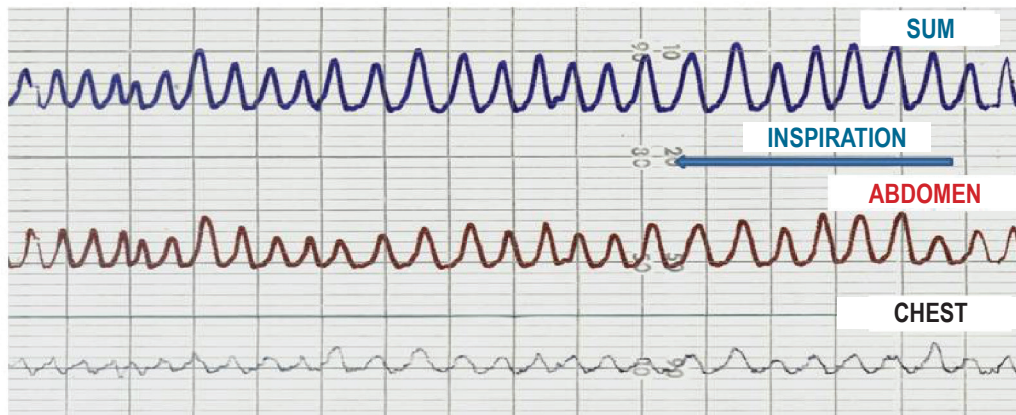


Figure 3 – Tracings of the abdominal and thorax movements, and of their sum, obtained by use of respiratory inductive plethysmography during quiet breathing in the dorsal decubitus position

in cycles per minute; and minute volume (VE) in liters per minute. In addition, the percentages of abdominal volume (%Abd) and rib cage volume (%RC) over TV were obtained. The maximal compartmental amplitude/VT ratio (MCA/VT), which reflects the coordination of the rib cage and abdominal movements, was calculated using the equation $(Abd+RC)/VT$. The thoracoabdominal movements are considered synchronic when that ratio is 1.0, and it can range up to 1.10.

The results are shown as mean and standard deviation. The BP and thoracoabdominal movement data, the influence of the group (MS and MR), position (dorsal decubitus and sitting), and the interaction between groups and positions were assessed by use of the two-way ANOVA for repeated measures in one of the factors. In correlation analysis a Pearson test was used for normal distribution data. Sample size calculation was based on VT; for 15% a significant difference of VT between the groups,

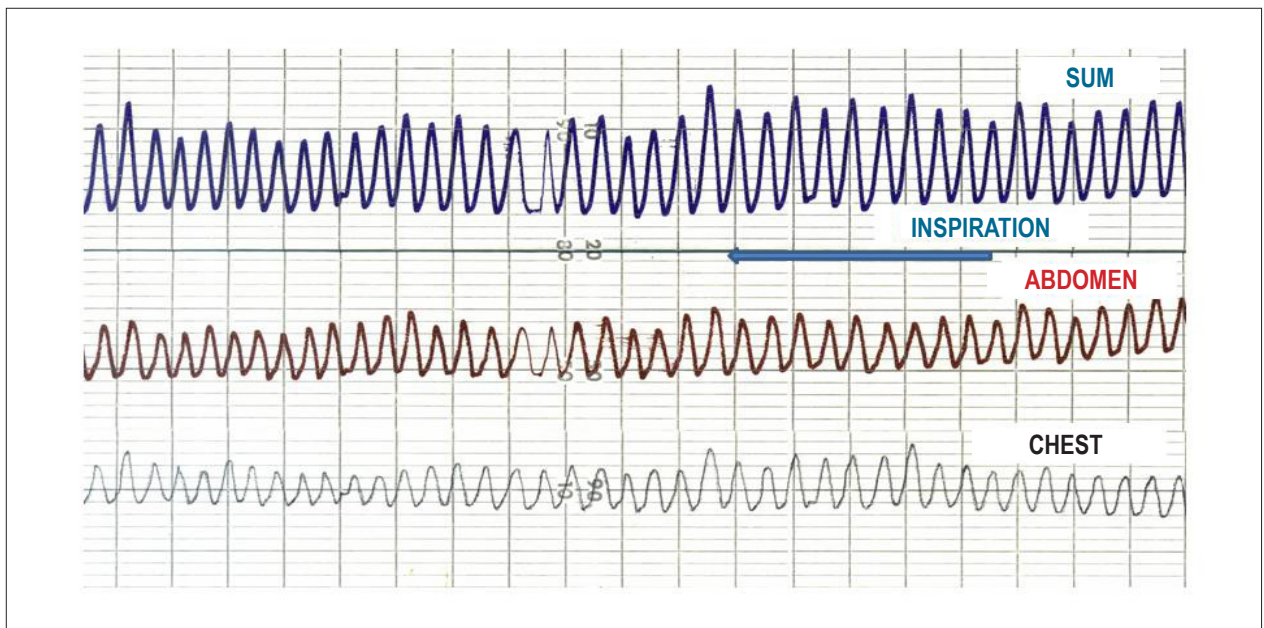


Figure 4 – Tracings of the abdominal and thorax movements, and of their sum, obtained by use of respiratory inductive plethysmography during quiet breathing in the sitting position

with a standard deviation of 40, significance level of 5% and statistical power of 80%, the size sample was estimated as 22 cases per group. Assuming a loss ratio of 10%, a minimum total population of 50 patients was delineated.

Results

This study assessed 65 patients, and ten were excluded. The reasons for exclusion were as follows: Cheyne-Stokes respiration ($n = 2$); dizziness and discomfort during the protocol ($n = 1$); and failure in plethysmograph calibration ($n = 7$). Of the 55 individuals completing the study, 29 (8 men and 21 women) were in the MSG and 26 (8 men and 18 women) were in the MRG.

Table 1 shows the anthropometric and echocardiographic data for each valvular heart disease group. The mean EF and PASP values showed no statistical difference between the groups. The VA was significantly smaller in MSG, with the corresponding TG markedly higher.

Table 2 shows the values of BP and thoracoabdominal movement during quiet breathing in the dorsal decubitus and sitting positions. Tidal volume, pulmonary ventilation, and mean inspiratory flow increased significantly when the patients adopted the sitting position, with no statistically significant differences between the groups. The breathing times did not vary with the change in body position and the type of valvular dysfunction.

Abdominal displacement predominated in both groups and in both positions, but significantly decreased in the sitting position. Inversely, the rib cage component significantly increased its participation in VT generation in the sitting position.

The mean MCA/VT ratio values, a parameter of coordination of thoracoabdominal movements, remained between 1.0 and 1.10, with no significant differences between neither the

groups nor the positions. However, ten patients (five in MSG and five in MRG) had uncoordinated breathing movements with MCA/TV ratio over 1.10 as follows: three MSG patients only in the dorsal decubitus position; five patients (two in MSG, three in MRG) only in the sitting position; and two MRG patients in both positions. On statistical analysis, the lack of coordination in the dorsal decubitus position ($n = 5$) showed a significant correlation with the PASP values ($r = 0.992$; $p = 0.007$), as shown in Table 3. This correlation did not reach statistically significant values ($r = 0.319$; $p = 0.537$), in patients who lacked coordination in the sitting position.

Discussion

In this study's sample, the female gender predominated (70%), and the mean age was 45 years. The highest incidence of MS occurs in that population, at a female:male ratio of 2:1².

The significant restriction in functional class caused by MS occurs around the fourth decade of life, and this usually leads to referral for surgery⁶. Transthoracic echocardiography is the gold standard test for diagnosing valvular heart diseases, providing anatomical and functional data in real time and noninvasively¹. Pulmonary artery systolic pressure values, measured by use of echocardiography, greater than 30 mm Hg indicate pulmonary hypertension.

Patients with MS can have greater perfusion in the upper zones of the lung because of the sustained elevation in pulmonary venous pressure and consequent edema in dependent regions. This process can increase vascular resistance in the lower zones of the lung. Vascular engorgement and edema in lung bases reduce compliance and increase airway resistance, which decrease ventilation and cause hypoxemia, resulting in vasoconstriction in those regions^{7,8}.

Table 1 – Characteristics of the mitral stenosis and regurgitation groups (MSG and MRG, respectively)

	MSG (n = 29)	MRG (n = 26)	p
Sex (F/M)	21/8	18/8	
Age (years)	46.3 ± 10.4	43.6 ± 13	0.406
Weight (kg)	63 ± 15.7	62.8 ± 13.2	0.940
Height (m)	1.6 ± 0.08	1.62 ± 0.1	0.151
BMI (kg/m ²)	24.8 ± 4.9	23.7 ± 3.8	0.346
Valvular area (cm ²)	0.97 ± 0.22	1.55 ± 0.6	<0.001
Transvalvular gradient (mm Hg)	11.6 ± 5.4	6.2 ± 3.7	0.006
EF (%)	61.6 ± 12	60 ± 10	0.592
PASP (mm Hg)	48.6 ± 19	50 ± 14.8	0.308

MSG: mitral stenosis group; MRG: mitral regurgitation group; F: female; M: male; BMI: body mass index; EF: ejection fraction; PASP: pulmonary artery systolic pressure

Table 2 – Values of the variables regarding breathing pattern and thoracoabdominal movement

	MSG		MRG		P (intragroup)	P (intergroup)
	Dorsal	Sitting	Dorsal	Sitting		
VT (ml)	362 ± 150	425 ± 207	400 ± 169	518 ± 249	0.001	0.236
f (ipm)	16 ± 3.6	17.5 ± 4.3	16.6 ± 4.5	17.3 ± 4.5	0.104	0.961
VE (L)	5.8 ± 2.5	7 ± 3.2	6.4 ± 2.7	8.7 ± 5	0.04	0.979
TI (s)	1.5 ± 0.3	1.4 ± 0.4	1.5 ± 0.4	1.5 ± 0.4	0.920	0.791
TE (s)	2.4 ± 0.7	2.2 ± 0.6	2.4 ± 0.6	2.3 ± 0.7	0.916	0.649
TTOT (s)	3.9 ± 0.8	3.6 ± 0.9	3.8 ± 0.9	3.7 ± 1	0.227	0.979
VT/TI	254 ± 104	309 ± 178	280 ± 120	349 ± 163	0.006	0.309
TI/TTOT	0.4 ± 0.07	0.4 ± 0.05	0.4 ± 0.06	0.4 ± 0.04	0.100	0.958
% Abd	63 ± 22	51 ± 18	72 ± 17	53 ± 18	<0.001	0.169
% RC	40 ± 21	50 ± 18	27 ± 16	46 ± 17	<0.001	0.548
MCA/VT	1.03 ± 0.07	1.04 ± 0.12	1.05 ± 0.06	1.06 ± 0.07	0.341	0.235

MSG: mitral stenosis group; MRG: mitral regurgitation group; VT: tidal volume; f: respiratory rate; VE: minute volume; TI: inspiratory time; TE: expiratory time; TTOT: total breathing cycle time; VT/TI: mean inspiratory flow; TI/TTOT: effective breathing time; % Abd: percentage of abdominal volume over tidal volume; % RC: percentage of rib cage volume over tidal volume; MCA/VT: maximal compartmental amplitude/VT ratio; ml: milliliters; ipm: incursions per minute; L: liters; s: seconds

Table 3 – Correlation between coordination of thoracoabdominal movement and pulmonary artery systolic pressure in the dorsal decubitus position

	Coordination		Noncoordination	
	r	p	r	p
MCA/VT				
PASP	-0.217	0.195	0.992	0.007

MCA/VT: maximal compartmental amplitude/VT ratio; PASP: pulmonary artery systolic pressure

According to Kawagoe et al.³, abnormal BP can occur in individuals with MS because of low cardiac output, being one of the major causes of breathing muscle fatigue. In their study with 37 patients with MS in the standing position, 23 showed

abnormal thoracoabdominal movement (74% had a thoracic dominant pattern, and 26% had a paradoxical pattern). Those with a paradoxical pattern showed higher PASP values and lower VA values. According to those authors, MS accounted for

increasing blood flow to the apical lung regions, and an elevation in the ventilation/perfusion ratio (V/Q) led to greater recruiting of the thoracic musculature.

In the present study, patients with MS and MR showed similar BP and thoracoabdominal movement. The type of heart valvular dysfunction did not influence these parameters, which varied only with body position: the sitting position caused a marked increase in TV, pulmonary ventilation, and mean inspiratory flow, while the breathing times remained unaltered, regardless of the position and heart valvular dysfunction. Our data are similar to those obtained from healthy people. Feltrim⁵ has assessed, by using the same method, the BP and thoracoabdominal movement of 40 healthy young individuals, and has reported that the change from the dorsal decubitus to the sitting position increased inspiratory volume and flow, without changing breathing times.

The abdominal movement predominated in both groups and in both positions, and decreased in the sitting position, inversely to the thorax component. The BP and thoracoabdominal movement vary with the change in body position: in the dorsal decubitus position, the abdominal compartment predominates, while, in the sitting position, the rib cage movement predominates⁴. This results from the higher abdominal compliance in the dorsal decubitus position, in which the diaphragm is more elongated, and its fibers contract more efficiently, favoring its greater excursion. In the standing position, due to gravity, the diaphragm lowers, increasing the vertical diameter and favoring the action of intercostal muscles⁵.

Of the 55 patients in our study, 25 of the MSG and 19 of the MRG had PASP over 30 mm Hg. This shows that the majority of our patients had pulmonary hypertension, but their BP was similar to that found in healthy individuals^{4,5}.

The type of valvular heart disease did not interfere with the BP. The timing of referral surgery and clinical control might explain why pulmonary hypertension in those patients could not significantly alter the pulmonary perfusion pattern that would lead to the rib-cage component predominance.

In our patients, the mean MCA/VT, a parameter of coordination of the thoracoabdominal movements, was within the normal range and did not significantly differ between the

groups. In most patients, thoracoabdominal movement was coordinated, but eight individuals lacked coordination in one of the positions (either dorsal decubitus or sitting), while two lacked it in both positions. Those who lacked coordination in the dorsal decubitus position had a strong association with pulmonary hypertension (9% of the sample).

Because of the limited size of the sample and the variables studied, a relationship identifying clinical or pathophysiological characteristics of those patients could not be established. One can assume that, in those individuals, the dorsal decubitus position contributed to markedly increase pulmonary blood flow in the dependent regions, with airway closure and a reduction in the residual functional capacity. In such a situation, the increase in the breathing muscle work would have favored the appearance of lack of thoracoabdominal movement coordination.

The scarcity of studies on the topic in that population limits the extension of the discussion to identify possible clinical parameters that could be associated with the change in BP.

Conclusion

Patients with MS and MR show no difference regarding the BP and thoracoabdominal movement. The sitting position increases pulmonary volumes without altering breathing times. A small number of patients with valvular heart disease lack coordination of thoracoabdominal movement, which is associated with pulmonary hypertension.

Potential Conflict of Interest

No potential conflict of interest relevant to this article was reported.

Sources of Funding

There were no external funding sources for this study.

Study Association

This study is not associated with any post-graduation program.

References

1. Santos AA, Moisés VA. Peculiaridades fisiopatológicas das valvopatias mitrais: implicações clínicas e terapêuticas. *Rev Soc Cardiol Estado de São Paulo*. 2008;18(4):314-8.
2. Bonow RO, Carabello BA, Kanu C, de Leon AC Jr, Faxon DP, Freed MD, et al.; American College of Cardiology/American Heart Association Task Force on Practice Guidelines; Society of Cardiovascular Anesthesiologists; Society for Cardiovascular Angiography and Interventions; Society of Thoracic Surgeons. ACC/AHA 2006 guidelines for the management of patients with valvular heart disease: a report of the American College of Cardiology/American Heart Association Task Force on Practice Guidelines (writing committee to revise the 1998 Guidelines for the Management of Patients With Valvular Heart Disease): developed in collaboration with the Society of Cardiovascular Anesthesiologists: endorsed by the Society for Cardiovascular Angiography and Interventions and the Society of Thoracic Surgeons. *Circulation*. 2006;114(5):e84-231.
3. Kawagoe Y, Konno K, Kanero N, Tanaka T, Yoshino K, Kimata S, et al. Abnormal breathing patterns in patients with mitral stenosis: a possible compensatory role. *Tohoku J Exp Med*. 1988;156 Suppl:159-70.
4. Tobin MJ, Chadha TS, Jenouri G, Birch SJ, Gazeroglu HB, Sackner MA. Breathing patterns. 1. Normal subjects. *Chest*. 1983;84(2):202-5.
5. Feltrim MIZ. Estudo do padrão respiratório e da configuração tóraco-abdominal em indivíduos normais, nas posições sentada, dorsal e laterais, com uso de plestimografia respiratória por indutância [dissertação]. São Paulo: Escola Paulista de Medicina; 1994.
6. Grinberg M, Sampaio RO. Doença valvar. São Paulo: Manole; 2006.
7. Dollery MB, West JB. Regional uptake of radioactive oxygen, carbon monoxide and carbon dioxide in the lungs of patients with mitral stenosis. *Circ Res*. 1960;8:765-71.
8. Dawson A, Kaneko K, McGregor M. Regional lung function in patients with mitral stenosis studied with xenon-133 during air and oxygen breathing. *J Clin Invest*. 1965;44(6):999-1008.

