

## Late Involution of Obstructive Rhabdomyoma of the Mitral Valve

Edmar Atik

Private practice of Dr. Edmar Atik, São Paulo, SP - Brazil

A male patient had presented signs of mitral valve obstruction since birth (fatigue during nursing, left atrial enlargement, diastolic gradient = 7 mmHg), which then regressed since 9 months of age. Masses identified at the mitral valve echocardiogram, right ventricular septum and left anterior papillary muscle led to a diagnosis of rhabdomyoma. Currently 14 years of age, the patient performs normal physical and mental activities. A late involution of the mitral valve mass was observed, partial at 5 years and total at 14 years of age. The mass measured 15x14mm up to 28 months of age, 14x11mm at 5 years and 12x10mm at 8 years of age. The other masses, which were non-obstructive, decreased. The expectant management showed a peculiar late involution of the rhabdomyoma.

### Potential Conflict of Interest

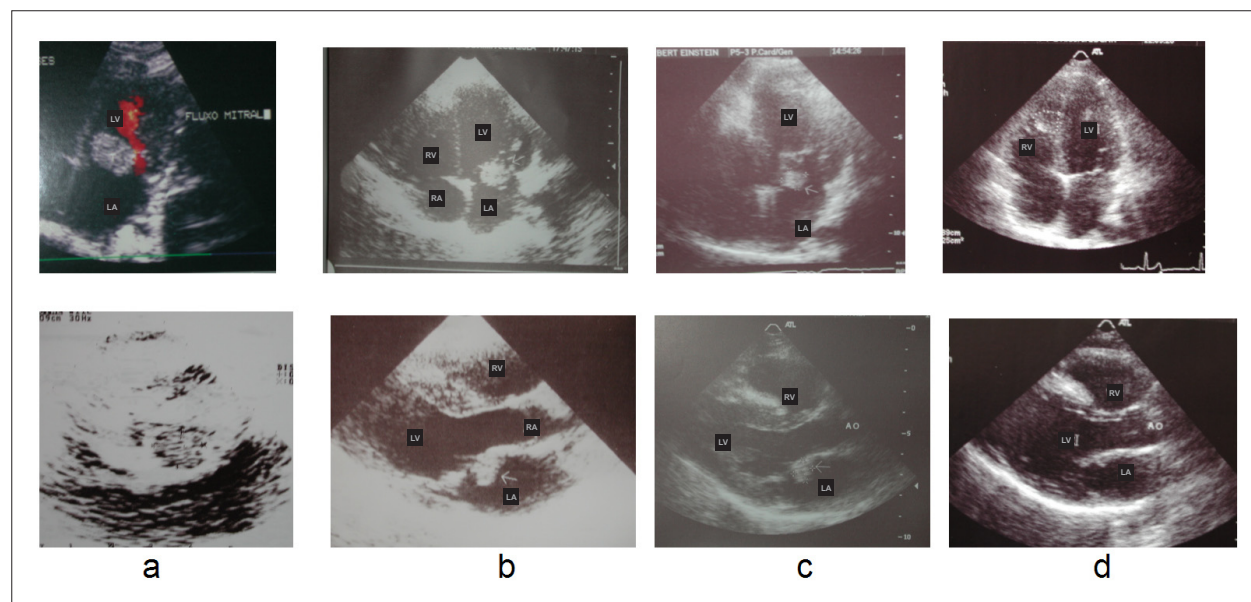
No potential conflict of interest relevant to this article was reported.

### Sources of Funding

There were no external funding sources for this study.

### Study Association

This study is not associated with any post-graduation program.



**Figure 1** - Sequence of images of the hyperechogenic mass located on the atrial side of the anterior mitral valve disclosing a clear progressive decrease of the mass at 2 months of age (a), 68 months (b), 8 years (c) and total involution at 14 years (d), in apical 4-chamber view (upper line) and left longitudinal paraesophageal view (lower line). RA - right atrium; LA - left atrium; LV - left ventricle; RV - right ventricle; Ao - aortic.

### Key words

Rhabdomyoma; mitral valve/abnormalities; congenital abnormalities.

### Mailing address: Edmar Atik •

Rua Dona Adma Jafet, 74 cj 73 - Bela Vista - 01308-050 - São Paulo, SP - Brazil

E-mail: conatik@incor.usp.br, eatik@cardiol.br

Manuscript received on September 11, 2008; revised manuscript received on October 22, 2008, accepted on October 21, 2008.