

## Antiadrenergic Rescue Therapy with Amiodarone in Children with Severe Left Ventricular Dysfunction Secondary to Scorpion Envenomation

Justo J. Santiago<sup>1,2,3</sup>, Carmen A. Mazzei de Dávila<sup>2,3</sup>, Diego F. Davila<sup>1,2,3</sup>, Jose H. Donis<sup>1,2,3</sup>, Vanesa Villaruel<sup>3</sup>

Instituto de Investigaciones Cardiovasculares de la Universidad de los Andes<sup>1</sup>; Hospital Universitario de los Andes<sup>2</sup>; Universidad de los Andes<sup>3</sup>, Mérida - Venezuela

### Abstract

**Background:** Children with scorpion envenomation have massive sympathetic activation and variable degrees of left ventricular systolic dysfunction.

**Objective:** To evaluate a rescue protocol for children with severe left ventricular dysfunction secondary to scorpion envenomation.

**Methods:** Four children, after scorpion envenomation, were subjected to a rescue protocol for acute left ventricular dysfunction: Endotracheal intubation and respiratory assistance, electrocardiograms, chest x-Ray, echocardiograms and blood samples for norepinephrine and troponin I serum levels. Samples and echocardiograms were repeated at 12, 24 and 48 hours. Intravenous medications: Dobutamine: 4-6 mcg/kg/min. Amiodarone: 3 mg/kg during a 2 hour period. Maintenance: 5 mg/kg/day. Furosemide: 0.5 mg/kg/dose. Diuretics were given when the systemic blood pressure was above percentile fifty. Amiodarone, Dobutamine and Furosemide were administered during the first 48 hours. Beta-adrenergic blockers and angiotensin converting enzyme were given, at 48 hours after admission, once the left ventricular Ejection fraction > 0.35 and the clinical status had improved.

**Results:** On admission, norepinephrine was  $1727.50 \pm 794.96$  pg/ml, troponin I  $24.53 \pm 14.09$  ng/ml and left ventricular ejection fraction  $0.20 \pm 0.056$ . At twelve hours, norepinephrine and troponin I serum levels were down to half of the initial values and the ejection fraction increased to  $0.32 \pm 0.059$ . During the next 24 and 48 hours, the ejection fraction rose to  $0.46 \pm 0.045$ , ( $p < 0.01$ ) and norepinephrine and troponin diminished to  $526.75 \pm 273.73$  ( $p < 0.02$ ) and  $2.20 < 2.36$  ( $p < 0.02$ ) respectively.

**Conclusion:** Amiodarone, by acting as a neuromodulator, is very likely responsible for the early and progressive decrease of serum norepinephrine. (Arq Bras Cardiol 2010; 94(1) : 18-23)

**Key Words:** Scorpion venoms; norepinephrine; amiodarone; adrenergic beta-agonists.

### Introduction

In Mérida-Venezuela, we have identified distinct geographical areas in which scorpion envenomation is potentially lethal<sup>1,2</sup>. Our initial findings indicated that the clinical manifestations were predominantly cardiovascular (i.e. pulmonary edema and cardiogenic shock). In a second clinical investigation, we performed two-dimensional echocardiograms and measured norepinephrine serum levels, to simultaneously assess cardiac function and sympathetic activation<sup>3</sup>. Our results demonstrated that, in children with scorpion envenomation, pulmonary edema and cardiogenic shock were accompanied by massive sympathetic activation and variable degrees of reversible left ventricular systolic dysfunction.

The mechanisms by which scorpion envenomation causes myocardial damage and systolic dysfunction are still the subject of intense controversy<sup>4-9</sup>. Sympathetic nervous system activation<sup>9,10</sup> and direct effects of the venom on the myocardium<sup>11-12</sup> are thought to be responsible for myocardial damage and systolic dysfunction. Histopathological findings in fatal human scorpion envenomation have shown unequivocal evidence of coagulative myocytolysis<sup>5,7,13</sup>. These lesions, known as myocardial contraction bands, are considered the hallmark of catecholamine cardiotoxicity<sup>14</sup>. Moreover, cardiac troponin, a biological marker of myocardial necrosis, increases from admission to 24-36 hours after the sting<sup>15,16</sup>.

Children with pulmonary edema and cardiogenic shock secondary to scorpion envenomation are usually in critical conditions and hemodynamically unstable<sup>4,17</sup>. Medical management is aimed at providing cardiorespiratory assistance to improve tissue perfusion and oxygenation<sup>18</sup>. Ideally, cardioprotection from catecholamine cardiotoxicity should be based on beta-adrenergic antagonists<sup>19,20</sup>. However, the presence of acutely depressed left ventricular systolic function precludes the administration of these

**Mailing address:** Justo J. Santiago •

Av. Fernandes Peña con Monseñor Chacon, residencias el Tepuy Apto 4-a  
– Ejido – 5111, Mérida, Venezuela

E-mail: justos@ula.ve

Manuscript received December 12, 2006, manuscript revised received July 7, 2007; accepted October 9, 2007

extremely useful drugs<sup>3,17,21,22</sup>. Therefore, we have used the sympatholytic actions of intravenous and oral amiodarone as a rescue therapy for children with severe left ventricular dysfunction secondary to scorpion envenomation<sup>23</sup>.

## Methods

Children referred to the Pediatric Emergency of the Hospital Universitario de Los Andes, between November 2003 and November 2004, with clinical diagnosis of scorpion envenomation and who were in pulmonary edema or cardiogenic shock were managed according to the following rescue protocol for severe left ventricular systolic dysfunction. On admission and after informed consent was obtained from the child's parent, all patients were assessed by the same physicians and found to be hemodynamically unstable. Endotracheal intubation and respiratory support were instituted when necessary. They all were subjected to the following noninvasive tests: electrocardiograms, chest x-Ray, two-dimensional echocardiograms and blood tests. The latter included special samples for norepinephrine determination by high-pressure liquid chromatography<sup>19</sup> and troponin I by enzyme immunoassay (Immulite Automated Analyser, USA). Normal values for troponin I with this method are <1 ng/ml. Blood samples and two-dimensional echocardiograms were repeated at 12, 24 and 48 hours after admission and analyzed in a blind manner. The investigator responsible for this part of the protocol had no knowledge of the clinical status of the patient. This protocol was approved by the Human Research Committee of the Instituto de Investigaciones Cardiovasculares de la Universidad de Los Andes.

Based on the clinical and echocardiographic findings of shock and severely depressed left ventricular systolic function (Table 1: Ejection fraction  $0.20 \pm 0.056$ ), the following rescue protocol was performed:

- 1) Intravenous Dobutamine: 4-6 mcg/kg/min.
- 2) Intravenous Amiodarone: 3 mg/kg to be administered in a 2 hour period. Maintenance. 5 mg/Kg/day<sup>24</sup>
- 3) Furosemide: 0.5 mg/kg/dose.
- 4) Digitalis: 10 mcg/kg/day

Diuretics were given when systemic blood pressure was above the 50<sup>th</sup> percentile<sup>25</sup>. Amiodarone, dobutamine and furosemide were administered during the first 48 hours. Beta-adrenergic blockers (carvedilol: 0.04 mg/kg/dose, at a 12-hour interval) and angiotensin converting enzyme (captopril: 0.01 mg/kg/dose at an 8-hour interval)<sup>26</sup> were given up to 48 hours after admission, since left ventricular function (ejection fraction > 0.35) and clinical status had improved. Simultaneously, dobutamine, amiodarone and furosemide were progressively down titrated and discontinued.

Results are expressed as mean  $\pm$  SD. Statistical analyses of echocardiographic, neurohormonal and biochemical findings were performed by repeated-measures analysis of variance, linear regression, and correlation analysis. Statistical significance was set at  $p < 0.05$ .

## Results

Four children with scorpion envenomation were referred to the emergency department of the Hospital Universitario de Los Andes in Mérida, Venezuela. They came from rural areas of southwestern Venezuela and had received antivenin at the site of the accident (Antiscorpion serum, Centro de Biotecnología, Universidad Central, Caracas, Venezuela).

### Clinical, epidemiologic, electrocardiographic and echocardiographic characteristics

As can be seen in table 1, two patients were male and two female. Ages ranged from 3 to 14 years. The time interval between the accident and antivenin administration was  $7.0 \pm 4.54$  hours. Heart and respiratory rates were markedly increased, and systemic blood pressure was below the third percentile. The electrocardiogram was abnormal in all four patients (Figure 1), and the ejection fraction was severely depressed ( $0.20 \pm 0.056$ ).

### Echocardiographic, neurohormonal and biochemical changes during the administration of the rescue protocol for left ventricular systolic dysfunction

On admission, serum norepinephrine ( $1727.50 \pm 794.96$  ng/ml) and troponin I ( $24.53 \pm 14.09$ ) were markedly elevated and left ventricular ejection fraction was severely depressed ( $0.20 \pm 0.056$ ) (Table 2, Figure 1A). Twelve hours after initiation of the rescue protocol, mean norepinephrine ( $p < 0.02$ ) and troponin I serum levels were down to half of baseline values and the ejection fraction had increased from  $0.20 \pm 0.056$  to  $0.32 \pm 0.059$ . During the next 48 hours, the ejection fraction returned to values close to normal ( $0.46 \pm 0.045$ ,  $p < 0.01$ ) and biochemical markers of sympathetic activation ( $p < 0.02$ ) and myocardial necrosis ( $p < 0.002$ ) were also significantly diminished (Table 2).

Figure 2 illustrates the dramatic improvement in septal wall motion and left ventricular function. Norepinephrine ( $r = -0.76$ ,  $p < 0.004$ ) and troponin I ( $r = -0.60$ ,  $p < 0.01$ ) serum levels correlated inversely and significantly with ejection fraction. On the contrary, norepinephrine and troponin I

**Table 1 - Baseline clinical, epidemiological, electrocardiographic, and echocardiographic characteristics**

Age	7,50 $\pm$ 5,06 years
Sex: Male	2
Female	2
Time from accident to antivenin administration	7,0 $\pm$ 4,54 hours
Heart rate	154,50 $\pm$ 27,52 beats/min
Respiratory rate	60 $\pm$ 10,14 breaths/min
Systemic blood pressure	< 3 <sup>rd</sup> Percentile
LV* Ejection fraction	0,20 $\pm$ 0,056
Electrocardiogram	ST depression in precordial leads

Values are M  $\pm$  SD \* Left Ventricular.

correlated directly and significantly with one another ( $r = 0.60$ ,  $p < 0.01$ ) (Figure 3).

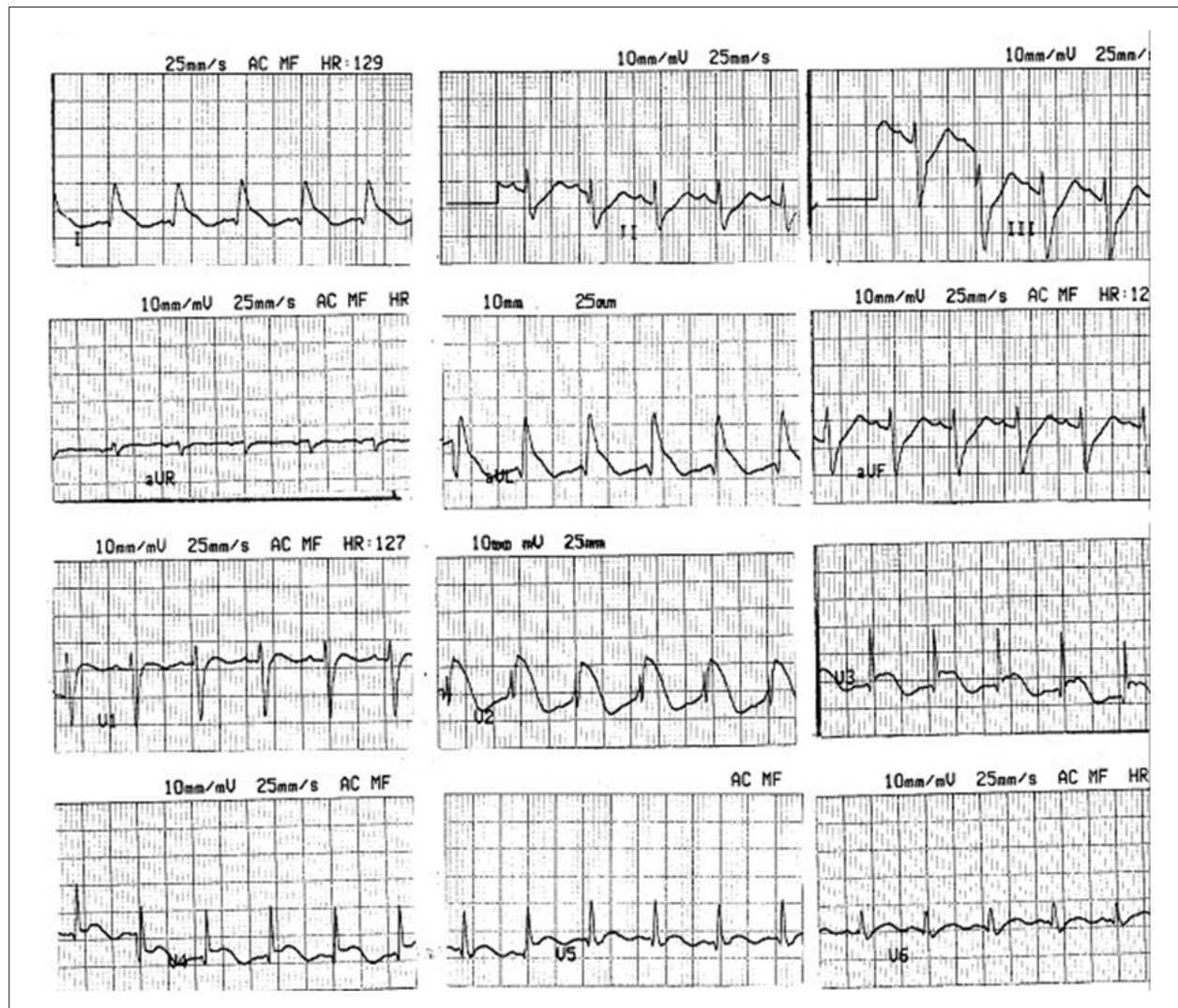
## Discussion

Acutely depressed left ventricular function has been consistently demonstrated by two-dimensional echocardiograms and hemodynamic measurements in children with scorpion envenomation<sup>17,4</sup>. Although histopathological and biochemical studies have documented the presence of catecholamine cardiotoxicity<sup>4,14,6</sup> and myocardial necrosis<sup>3,7</sup>, current clinical management of the cardiovascular manifestations of scorpion envenomation is mainly based on mechanical ventilation and positive inotropic support<sup>17,18</sup>. Moreover, clinical and experimental studies clearly indicated that beta-adrenergic agonists drugs might enhance the deleterious effects of massive sympathetic activation on the myocardium<sup>27,28</sup>.

Children with acute left ventricular systolic dysfunction

secondary to scorpion envenomation clearly need the positive inotropic support provided by endogenous catecholamines and exogenous beta-adrenergic agonists<sup>18</sup>. In an attempt to modulate the massive sympathetic activation caused by scorpion envenomation and minimize the need for positive inotropic support with beta-adrenergic agonists, we have followed an antiadrenergic rescue protocol for acutely depressed left ventricular systolic function. This rescue protocol is based on the favorable effects of intravenous amiodarone on critically ill children<sup>23</sup>. Intravenous administration of amiodarone has acute sympatholytic and vagotonic actions<sup>29</sup>. Furthermore, amiodarone selectively decreases sympathetic efferent traffic to the heart and improves left ventricular function<sup>30-33</sup>.

Upon admission, our patients with acutely depressed left ventricular function had biochemical evidence of massive sympathetic activation and of myocardial necrosis. Norepinephrine and troponin I serum levels were markedly elevated. Serial echocardiograms and determinations



**Figure 1** - Admission surface electrocardiogram. Case No. 2. ST segment elevation in precordial (V2-V5) and limb leads (DI-AVL). Echocardiographic, neurohormonal and biochemical changes during the administration of the rescue protocol for left ventricular systolic dysfunction



**Table 2** - Echocardiographic, neurohormonal and biochemical changes during administration of the rescue protocol for left ventricular systolic dysfunction

	Baseline	12 hours	24 hours	48 hours
Norepinephrine (pg/ml)	1727,50 ± 795,96	858,50±433,16***	1159 ± 1119,16	526,75 ±273.73***
Troponin I (ng/ml)	24,53 ±14,09	14,05 ± 6,55	5,43 ± 3,57 *	2,20 ± 2,36***
Ejection fraction	0,20 ±0,056	0,32 ± 0,059	0,39 ± 0,043 *	0,46 ± 0,045•

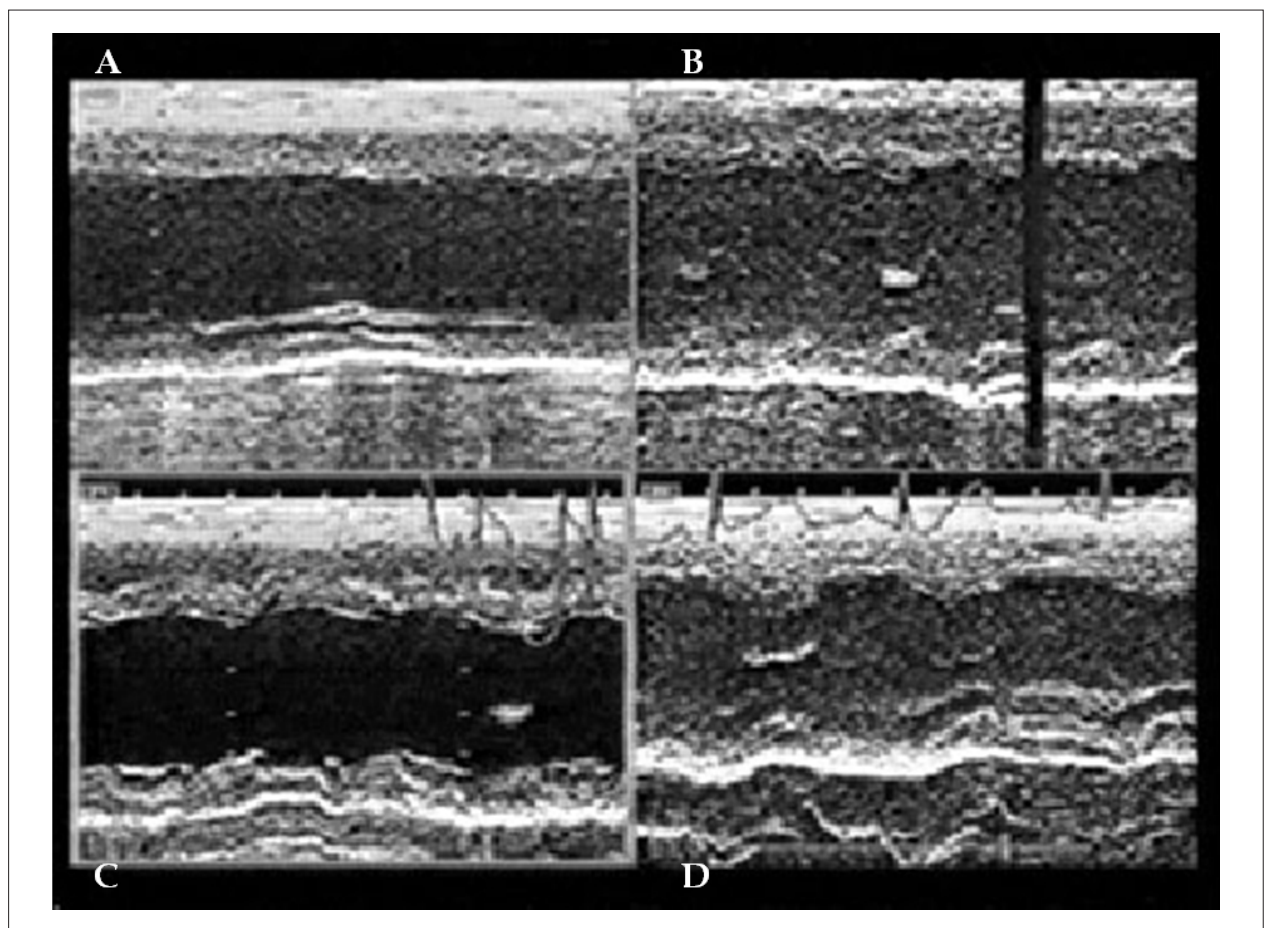
\* $p < 0,002$ , •  $p < 0,01$ , \*\*  $p < 0,04$ , \*\*\*  $p < 0,02$

of troponin I and of norepinephrine showed a dramatic improvement in left ventricular function and a decrease in the extent of sympathetic activation and of myocardial necrosis, within twelve hours of having initiated the antiadrenergic rescue protocol for left ventricular systolic dysfunction. During this period, patients received diuretics, beta-adrenergic agonists and amiodarone. The former two drugs are known to increase sympathetic activation and mortality in the presence of left ventricular dysfunction<sup>34,35</sup>, whereas amiodarone has opposite effects on sympathetic

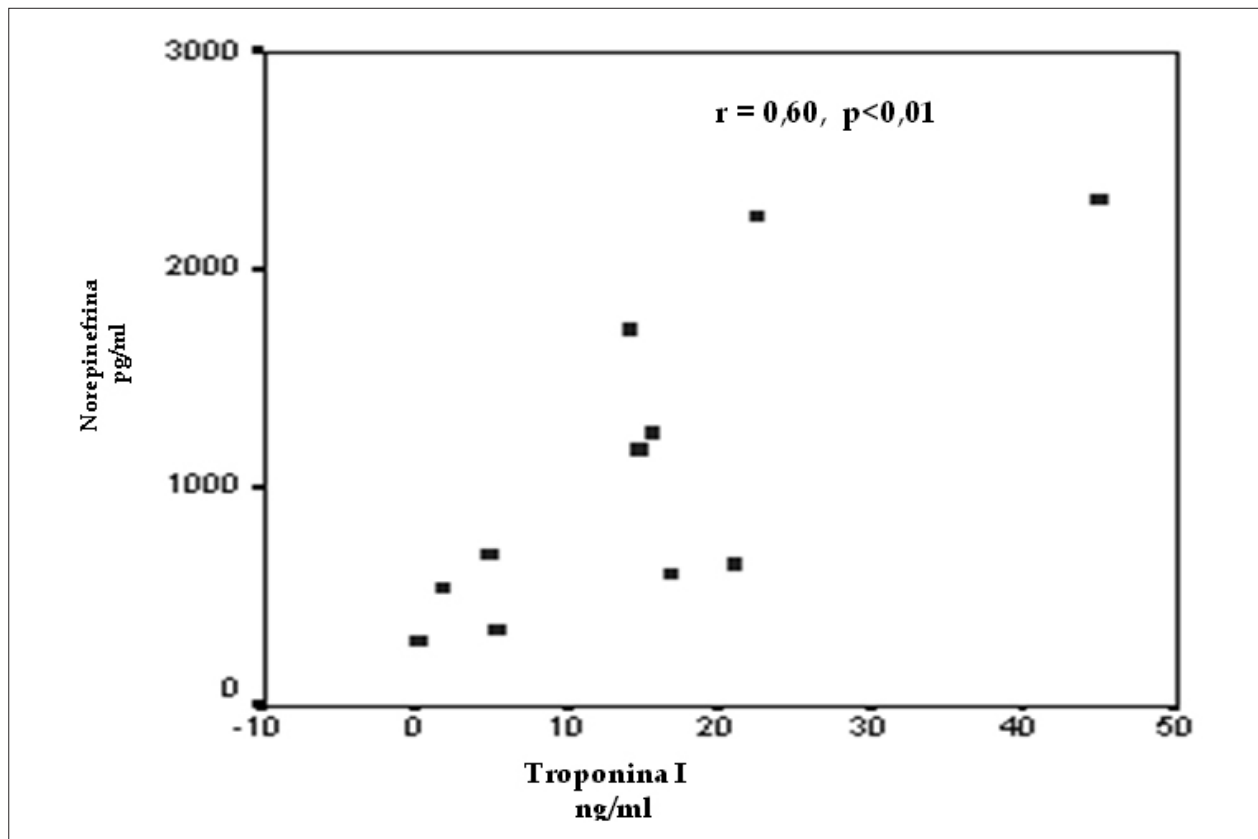
activation and mortality<sup>22,36</sup>. Therefore, the very favorable effects of our antiadrenergic rescue protocol are very likely secondary to the sympatholytic and vagotonic actions of amiodarone<sup>29-31</sup>.

**Norepinephrine serum levels directly correlated with troponin I and inversely with the left ventricular ejection fraction**

A possible explanation for these findings is provided by a recent clinical study, which simultaneously assessed myocardial perfusion, left ventricular function and regional wall motion<sup>6</sup>.



**Figure 2** - Echocardiographic changes during administration of the rescue protocol for left ventricular systolic dysfunction. On admission (A), left ventricular systolic function is severely depressed, the septum is akinetic and the inferior wall is hypokinetic. Septal and inferior wall motion progressively improves from 12 (B) to 24 (C) and 48 hours (D).



**Figure 3** - Correlation analysis between norepinephrine and troponin serum levels. A direct and significant correlation exists between norepinephrine and troponin serum levels ( $r = 0.60$ ,  $p < 0.01$ ).

Reversible myocardial perfusion defects were topographically associated with regional wall motion abnormalities (RWMA). Furthermore, improvement in left ventricular function and RWMA paralleled normalization of myocardial perfusion. In other words, norepinephrine, through its direct effects on the myocardium (i.e. necrosis) and on coronary microcirculation (i.e. vasospasm) is very likely responsible for both myocardial necrosis and left ventricular systolic dysfunction.

## Conclusion

Although patients had received antivenin at the site

of the accident<sup>37</sup>, the time interval between the accident and antivenin administration was outside the optimal time window for its beneficial effects<sup>1</sup>. This probably explains the progression of the envenomation to the stage of pulmonary edema and shock<sup>2</sup>. We should emphasize that our report is an open and non-randomized study based on a small number of cases. Our encouraging findings provide a therapeutic alternative to a potentially harmful strategy based on high doses and long-term administration of beta-adrenergic agonists. A prospective and randomized rescue protocol, based on the neuromodulatory effects of amiodarone, should be performed.

## References

1. Mazzei C, Fuenmayor A, Salgar N, Gonzales Z, Dávila D. Scorpion envenomation in Mérida, Venezuela. *Toxicon*. 1997; 35: 1459-62.
2. Mazzei C, Dávila D, Gonzales M, Dávila D, Pamoni P. Identificación de especies de escorpiones en el Estado Mérida. [Tesis]. Venezuela: Colegio San Luis de Mérida, Venezuela: 1999.
3. Mazzei de D'Avila CA, D'Avila DF, Donis JH, Bellabarba GA, Villarreal V, Barboza JS. Sympathetic nervous system activation, antivenin administration and cardiovascular manifestations of scorpion envenomation. *Toxicon*. 2002; 40: 1339-46.
4. Bahloul M, Kallel H, Rekik N, Ben Hamida C, Chelly H, Bouaziz M. Cardiovascular dysfunction following scorpion envenomation: mechanisms and pathophysiology. *Press Med*. 2005; 34 (2pt1): 115-20.
5. Cupo P, Jurca M, Acedo M, Oliveira J, Hering S. Severe scorpion envenomation in Brazil. Clinical laboratory and anatomopathological aspects. *Rev Inst Med Trop Sao Paulo*. 1994; 36: 67-76.
6. Cupo P, Figueiredo AB, Filho AP, Pintya A, Tavares Jr. G, Caligaris F, et al. Acute left ventricular dysfunction of severe scorpion envenomation is related to myocardial perfusion disturbance. *Int J Cardiol*. 2007; 116 (1): 98-106.

7. Daisley H, Alexander D, Pitt P. Acute myocarditis following *Tityus trinitatus* envenoming: morphological and pathophysiological characteristics. *Toxicon*. 1999; 37: 159-65.
8. Gueron M, Ilia R, Margulis G. Arthropods poisons and the cardiovascular system. *Am J Emerg Med*. 2000; 18: 708-14.
9. Ismail M. The scorpion envenomin syndrome. *Toxicon*. 1995; 33: 825-58.
10. Nouira S, Elatrous S, Besbes S, Boukef F, Devaux C, Aubrey N, et al. Neurohormonal activation in severe scorpion envenomation: correlation with hemodynamics and circulating toxin. *Toxicol Appl Pharmacol*. 2005; 208: 111-6.
11. Ouanes-Besbes L, El Atrous S, Nouira S, Aubrey N, Carayon A, El Ayeb M, et al. Direct vs. mediated effects of scorpion venom: an experimental study of the effects of a second challenge with scorpion venom. *Intensive Care Med*. 2005; 31: 441-6.
12. Texeira A, Fontoura B, Freire L, Machado C, Camargo E, Texeira M. Evidence for a direct action of *Tityus serrulatus* scorpion on the cardiac muscle. *Toxicon*. 2001; 39: 703-9.
13. Benvenuti L, Douettes K, Cardoso J. Myocardial necrosis after envenomation by the scorpion *Tityus serrulatus*. *Trans R Soc Trop Med Hyg*. 2002; 96: 275-6.
14. Baroldi G, Mittleman R, Parolini M, Silver M, Fineschi V. Myocardial contraction bands: definitions, quantification and significance in forensic pathology. *Int J Legal Med*. 2001; 115: 142-51.
15. Cupo P, Hering S. Cardiac troponin I release after severe scorpion envenoming by *Tityus serrulatus*. *Toxicon*. 2002; 40: 823-30.
16. Meki A, Mohamed Z, Mohey H. Significance of assessment of serum cardiac troponin I and interleukin-8 in scorpion envenomed children. *Toxicon*. 2003; 41: 129-37.
17. Abroug F, Boujdaria R, Belghlith M, Nouira S, Bouchoucha S. Cardiac dysfunction and pulmonary edema following scorpion envenomation. *Chest*. 1991; 100: 1057-9.
18. Elatrous S, Nouira S, Besbes L, Boussarsar M, Boukef R, Marghli, et al. Dobutamine in severe scorpion envenomation: effects on standard hemodynamics, right ventricular performance, and tissue oxygenation. *Chest*. 1999; 116: 748-53.
19. Mann D, Kent R, Parsons B, Cooper G. Adrenergic effects on the biology of the human cardiac myocyte. *Circulation*. 1992; 85: 790-804.
20. Mann D. Basic mechanisms of disease progression in the failing heart: the role of excessive adrenergic drive. *Prog Cardiovasc Dis*. 1998; 41 (1Suppl 1): 1-8.
21. Simoes M, Maciel B, Marin J. Reversible segmental left ventricular dysfunction caused by accidental administration of sympathomimetic drug in human. *Int J Cardiol*. 1997; 61: 93-6.
22. Choo D, Huiskes B, Jones J, Fabbri S, Hawkins L, Chatterjee, et al. Amiodarone rescue therapy for severe decompensated heart failure initially unsuitable for beta-blockers. *J Cardiovasc Pharmacol Ther*. 2003; 8: 187-92.
23. Perry JC, Fenrich AL, Hulse JE, Triedman JK, Friedman RA, Lamberti JJ. Pediatric use of intravenous amiodarone: efficacy and safety in critically ill patients from a multicenter protocol. *J Am Coll Cardiol*. 1996; 27: 1246-50.
24. Vogel M. Echocardiographic analysis of regional left ventricular wall motion in normal children and neonates. *J Am Coll Cardiol*. 1990; 15: 1409-12.
25. Karnard D, Deo A, Apte N, Lohe A, Thatte S, Tilve JH. Captopril for correcting diuretic induced hypotension in pulmonary edema after scorpion sting. *Br Med J*. 1985; 298: 1430-1.
26. Dávila D, Bellabarba G, Hernandez L, Calmon G, Torres A, Barboza J, et al. Plasma norepinephrine, myocardial damage and left ventricular systolic function in Chagas' heart disease. *Int J Cardiol*. 1995; 52: 145-51.
27. Mendez-Castellano H, Macias-Tome C. Fundacredesa: Fundación para el Estudio de crecimiento y desarrollo del venezolano. Proyecto Venezuela, Caracas; 1993.
28. Movahed A, Reeves WC, Mehta PM, Gilliland MG, Mazingo SL, Jolly SR. Norepinephrine-induced left ventricular dysfunction in anesthetized and conscious, sedated dogs. *Int J Cardiol*. 1994; 45: 23-33.
29. Dias V, Ginecchi T, Lavelli B, Bellina V, Manzella D, Porta A, et al. Opposite effects of iv amiodarone on cardiovascular vagal and sympathetic efferent activities in rats. *Am J Physiol Regul Integr Comp*. 2002; 283: R543-R548.
30. Davila DF, Donis JH, Bellabarba G, Torres A, Casado J, Mazzei de Davila C. Cardiac afferents and neurohormonal activation in congestive heart failure. *Med Hypotheses*. 2000; 54: 242-53.
31. Davila DF, Nuñez T, Odreman R, Mazzei de Davila C. Mechanisms of neurohormonal activation in chronic congestive heart failure: pathophysiology and therapeutic implications. *Int J Cardiol*. 2005; 101: 343-6.
32. Du XJ, Esler M, Dart A. Sympatholytic actions of intravenous amiodarone in the rat heart. *Circulation*. 1995; 91: 462-70.
33. Kaye D, Darta A, Jennings D, Esler M. Antiadrenergic effects of chronic amiodarone therapy in human heart failure. *J Am Coll Cardiol*. 1990; 15: 1409-12.
34. Abraham W, Adams K, Fonarow G, Contanzo M, Berowitz R, Lejemtel T, et al. ADHERE Scientific Advisory Committee and Investigators; ADHERE Sstudy Group. In-hospital mortality in patients with acute decompensated heart failure requiring intravenous vasoactive medications: an analysis from the Acute Decompensated Heart Failure National Registry (ADHERE). *J Am Coll Cardiol*. 2005; 46: 57-64.
35. Francis G, Siegel R, Goldsmith S, Olivari M, Levine T, Cohn J. Acute vasoconstrictor response to intravenous furosemide in patients with chronic congestive heart failure: activation of the neurohumoral axis. *Ann Intern Med*. 1985; 103: 1-6.
36. Dorian P, Cass D, Schwartz B, Cooper R, Gelasnikas R, Barr A. Amiodarone as compared with lidocaine for shock-resistant ventricular fibrillation. *N Eng J Med*. 2002; 346: 884-90.
37. Ismail, M. The scorpion envenoming syndrome: the saudi experience with serotherapy. *Toxicon*. 1994; 32:1019-26.