

CLINICAL LIVER TRANSPLANTATION WITHOUT VENOVENOUS BYPASS*Transplante de fígado clínico sem desvio venovenoso*Olival Cirilo Lucena da **FONSECA-NETO**From Oswaldo Cruz University Hospital,
Recife, PE, Brazil.**HEADINGS** - Liver transplantation.
Venovenous bypass. Complications.
Technique.**ABSTRACT – Introduction** – The use of a venovenous bypass in liver transplantation is a controversy source and discussion among anesthetists and transplant surgeons. Although it provides a stable hemodynamic state and metabolism during the anhepatic stage, venovenous bypass may lead to a number of complications, some of them with death. **Aim** – To review the current practice of using clinic venovenous bypass in liver transplantation, with its advantages and disadvantages. **Method** – A broad review of the literature was carried out, paying especial attention to articles published in the past ten years and indexed in PubMed and Medline. The following cross-referenced headings were used: liver transplantation, venovenous bypass, conventional technique, classic technique. The articles chosen for analysis were those of the greatest relevance and those considered “classics” in the subject. **Conclusion** – Liver transplantation without venovenous bypass is a safe and rapid technique. In most cases it can be used without giving rise to serious complications in patients with liver disease.**Correspondence:**Olival Cirilo Lucena da Fonseca Neto
olivalneto@globo.comSource of funding: none
Conflict of interest: noneReceived: 17/11/2010
Accepted for publication: 08/02/2011**DESCRIPTOR** - Transplante de fígado.
Desvio venovenoso. Complicações. Técnica.**RESUMO – Introdução** - O problema da utilização do desvio venovenoso no transplante de fígado é um ponto de discussão e controvérsia entre anestesistas e cirurgiões transplantadores. Apesar de proporcionar ambiente hemometabólico estável durante a fase anepática o seu uso poderá levar a algumas complicações, inclusive fatais. **Objetivo** - Revisar a prática atual do uso do desvio venovenoso no transplante de fígado clínico, com suas vantagens e desvantagens. **Método** - Foi realizada ampla pesquisa na literatura, com especial atenção aos artigos publicados nos últimos 10 anos e indexados ao PubMed e Medline. Foram utilizados os seguintes descritores de forma cruzada: liver transplantation, venovenous bypass, conventional technique, classic technique. Entre os artigos encontrados foram considerados para análise os mais relevantes além dos considerados “clássicos” sobre o assunto. **Conclusão** - Transplante de fígado sem desvio venovenoso é técnica segura e rápida. Pode ser utilizada, com poucas exceções, sem acarretar complicações maiores nos pacientes com doença hepática.**INTRODUCTION**

Liver transplantation (TxF) is considered the definitive treatment for patients with terminal liver disease. The conventional technique involves removing the diseased liver combined with the retrohepatic superior vena cava. During this procedure the inferior vena cava is interrupted in its suprahepatic portion. Associated with this, the portal vein has ceased its flow to the liver causing infradiaphragmatic venous stasis. Hemodynamic changes are established during this phase, anhepatic phase (when the diseased liver is removed). Cardiac output and mean arterial pressure decrease from the present baseline and may result in intraoperative and postoperative complications. The hemodynamic and metabolic handling of the patient at the moment is a clinical challenge.

To avoid the consequences of hemodynamic and metabolic disruption cavo-portal venous, venovenous bypass (DVV) has been used. Initial experiments were published in 1983 and was soon spread throughout the world²³. Initially, the connection tubes were inserted through venous

dissection after percutaneous insertion but was widely adhered to. Remember that Cutr3pia in 1972 had used the DVV in experimental Tx^F. With it, the blood returns to the heart and allows hemodynamic stabilization. Its use can cause complications such as vascular thrombosis and pulmonary embolism, major or minor vascular injuries, air embolism, hematoma, seroma, nerve damage and wound infection². These complications have the potential to compromise the function of the liver graft, can lead to retransplantation and receptor death.

Looking to avoid the hemodynamic complications of conventional technique and the inherent complications of using a new technique of DVV hepatectomy was used in Tx^F: "piggyback technique"²⁷. It consists of removing the retrohepatic diseased liver preserving the vena cava. Thus, the continuity of the venous drainage infradiaphragmatically continues to decrease the hemodynamic consequences of the conventional technique without DVV. Although described for the 1st time in 1968 only was popularized in the late 1980s. However, the piggyback has been considered only in favorable anatomical conditions and then, returns the problem of whether or not the DVV in Tx^F must be done.

The purpose of this article is to review the present practice of using clinic DVV in liver transplant, with its advantages and disadvantages.

METHOD

Was performed extensive research in the literature, with special attention to articles published in the last 10 years and indexed by PubMed and MedLine. Were used the following cross headings: liver transplantation, venovenous bypass, conventional technique, classic technique. The initial search revealed 286 articles, being evaluated the most relevant of the last 10 years, when the full texts were available for reading, besides older articles considered "classics" on the issue.

The venovenous bypass in liver transplantation

To perform the Tx^F in dogs was necessary to develop venovenous bypass because the animals did not tolerate abdominal vascular clamping. The first human liver transplants were performed with venovenous bypass, but due to the high incidence of embolic phenomena from the intravenous tubes it was abandoned. Due to coagulation disorders found in patients with liver disease, systemic anticoagulation could not be used and, thus, reinforced the idea of abandoning the DVV. However, the Denver group, led by Starzl, found that humans tolerate the anhepatic

phase without DVV²⁶. Were done 170 Tx^F in Denver, and 63 in Pittsburgh without DVV. But in 1982 after six intraoperative deaths (during the anhepatic phase) it was restrict. Now, it would be simpler²⁴. Only one-roller pump with tubes coated with heparin are being used. After successful experimental Tx^F, its clinical use spread quickly throughout the world.

Advantages and disadvantages of DVV

The conventional Tx^F causes venous congestion in the infradiaphragmatic territory and thereby decrease cardiac output and blood pressure. Its use decompresses the splanchnic circulation and lower extremities of the body allowing more stability in the anhepatic Tx^F. Thus, the DVV restores normal physiology and reduces renal congestion during the interruption of the inferior vena cava². In patients with pulmonary hypertension with cardiac dysfunction or cardiomyopathy also seems to benefit from the DVV (reducing the overflow on the heart during the anhepatic phase, and especially after coronary graft artery bypass)²². Renal function, using the DVV is widely supported because it would reduce the occurrence of renal dysfunction in the postoperative period³. It was also shown that greater balance in the cerebral circulation occurs with the use of DVV, especially in patients with acute liver failure¹⁷. Pulmonary changes in postoperative Tx^F are less frequent use of the DVV¹. All these phenomena occur due to interruption of the inferior vena cava and portal vein was attenuated with DVV. Among the disadvantages of DVV are the possibility of thromboembolic events with fatal outcome⁸. Air embolism is described and usually severe. Hypothermia is related to duration of DVV and may compromise the initial function of the graft. Complications of vascular access is considered to be minor can influence the quality of life after Tx^F.

Recent studies have shown increased release of inflammatory cytokines using the DVV with adverse clinical effects²¹. Moreover, there is an increase in the cost of Tx^F associated with the equipment and the perfusionist prolonged operation.

Several authors have shown that the "piggyback" technique could replace the use of DVV; it would allow continued blood flow in the inferior vena cava²⁰. These authors reported lower hemodynamic complications, renal, cardiac, cerebral than when using the DVV. Only failed to show better results for pulmonary complications. However, using the piggyback technique remains the splanchnic congestion that may influence the severity of reperfusion syndrome (cardiovascular collapse after the "new" liver in the recipient's blood rich in substances like potassium, cytokines, peroxide radicals, among others) and complicating the evolution of graft. To avoid

congestion in the splanchnic piggyback can be used to temporary portacaval shunt²⁵. In the piggyback technique with or without portacaval shunt, surgical time increases and can compromise the results of TxF. Moreover, the piggyback technique can be difficult due to anatomical features of the native liver (enlarged segment I and/or bypassing the inferior vena cava) and inflammatory (intense adhesions between the liver and abdominal wall, segment I and inferior vena cava). New complications arose with the advent of piggyback technique, vascular ones, related to anastomosis of the hepatic veins and inferior vena cava leading to obstruction of the venous graft for hepatic inferior vena cava ("outflow" blocking)⁶. providing congestion, ascites, liver retransplantation and death. Thus, the piggyback technique also has its drawbacks (Figure 1).

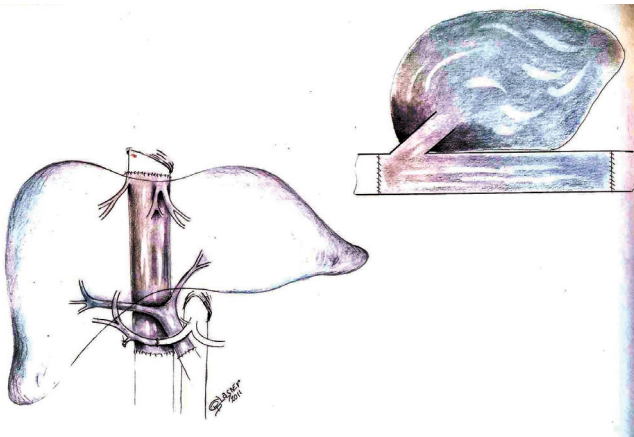


FIGURE 1 - Schematic drawing of the implantation of liver graft by conventional technique

The conventional liver transplantation without venovenous bypass

In the early era of liver transplantation, the conventional technique was performed and, due to infradiaphragmatic venous interruption and prolonged operation, complications were described as gastrointestinal edema, hemorrhage, renal and pancreatic failure and weight gain. After almost 50 years of the 1st TxF in humans, alterations and additions in the knowledge of the hemodynamic changes of these patients were acquired by changing the management of these critically ill patients in the perioperative period⁹. Despite the hyperdynamic circulation and various syndromes (hepatorenal, hepatopulmonary hepatocirculatory, hepatoadrenal) better handling with fluid replacement, vasopressors and best technique (more delicate dissection and shorter operative time) have attenuated the postoperative complications after TxF¹³. New knowledge on the coagulation of cirrhotic patients changed the use of blood

products intraoperatively (downwards) and added the use of synthetic (recombinant or not) as the best choice¹⁴. Changes in replacement of platelets, even in a critical situation due to its association with Tralli (acute lung injury related to blood transfusions) were also done²⁹. Several studies have shown that cardiovascular dysfunction in the anhepatic TxF conventional procedure without venovenous bypass is quickly overcome by the use of vasopressors and fluids with discrete effects on cardiac and urinary output³⁰.

The onset of renal dysfunction in the postoperative period without conventional DVV, is increased in most studies⁷. However, it is a temporary disturbance and low morbidity, even compared with the piggyback technique¹⁸. These studies suggest that in patients without renal dysfunction prior TxF tolerate interruption of cavo-portal blood flow without venovenous bypass and without significant renal dysfunction postoperatively^{16,28}.

The better understanding of physiopathological complications of portal hypertension in patients with liver disease have allowed better management of perioperative fluids with the use of more appropriate, more specific vasoconstrictor drugs and protective substances in target organs such as brain, heart and kidney, leading to better results in the post TxF, despite the use of conventional technique without venovenous bypass^{10,11,15,19} (Figure 2).

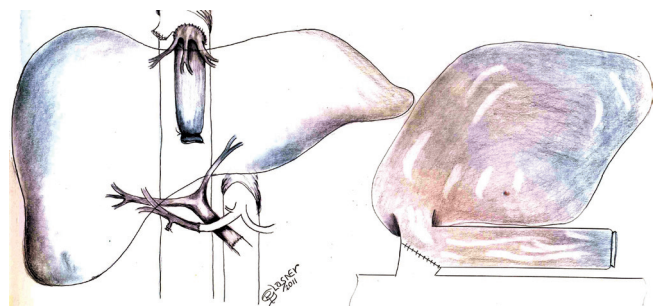


FIGURE 2 - Schematic drawing of the implantation of liver graft by piggyback technique

CONCLUSION

Liver transplantation without venovenous bypass technique is safe and fast. Can be used, with few exceptions, without causing major complications in patients with liver disease.

REFERENCES

1. Baia CE, Abdala E, Massarolo P, Bedushi T, Palma TM, Mies S. Inflammatory cytokines during liver transplantation: prospective randomized trial comparing conventional and piggyback techniques. *Hepatology* 2009; 56(94-95):1445-51.

2. Barnett R. Pro: Veno-veno bypass should routinely be used during liver transplantation. *J Cardiothorac Vasc Anesth* 2006; 20(5):742-743.
3. Biancofiore G, Davis CL. Renal dysfunction in the perioperative liver transplant period. *Curr Opin Organ Transplant* 2008; 13:291-297.
4. Calne RY, Williams R. Liver transplantation in man – I, observations on technique and organization in five cases. *BMJ* 1968; 4:535-540.
5. Carlos Cutropia J, Coratolo F, Spinetta A, Keil J, Ribas A, Assíni L, Delle Donne G, Bianchi M, Gui Názua A, Verdaguer JA. Experimental orthotopic liver transplant. *Rev Esp Enferm Apar Dig.* 1972; 38(5):553-70.
6. Chan C, Plata-Muñoz JJ, Franssen B. Técnicas quirúrgicas em transplante hepático. *Rev Invest Clin* 2005; 57(2):262-272.
7. Chen ZS, Zeng FJ, Ming CS, Lin ZB, Zhang WJ, Wei L, Jiang JP, Zhu XH, Gong NQ, Liu B, Liu DG, Chen ZK, Xia SS. Classic orthotopic liver transplantation without venovenous bypass: a report of 45 cases. *Transplant Proc.* 2003 Feb;35(1):364-5.
8. Fanouni H, Mehrabi A, Soleimani M, Müller SA, Büchler MW, Schmidt J. The need for venovenous bypass in liver transplantation. *HPB* 2008; 10:196-203.
9. Gallegos-Orosco JF, Vargas HE. Liver transplantation from child to MELD. *Med Clin V Am* 2009; 93:931-950.
10. Gurusamy KS, Koti R, Pamecha V, Davidson BR. Veno-venous bypass versus none for liver transplantation. *Cochrane Database Syst Rev.* 2011; 16;3:CD007712.
11. Gurusamy KS, Pamecha V, Davidson BR. Piggy-back graft for liver transplantation. *Cochrane Database Syst Rev.* 2011 19;(1):CD008258.
12. Hilmi IA, Planinsic RM. Con: Venovenous bypass should not be used in orthotopic liver transplantation. *J Cardiothorac Vasc Anesth* 2006; 20(5):744-747.
13. Khosravi MB, Jaleian H, Lah Sall M, Ghaffaripour S, Salahi H, Bahador A, Nikeghbalian S, Davari HR, Salehipour M, Kazemi K, Nejatollahi SMR, Shokrizadeh S, Gholami S, Malek-Hosseini SA. The effect of clamping of inferior vena cava and portal vein on urine output during liver transplantation. *Transplant Proc* 2007; 39:1197-1198.
14. Kim D-Y, Huh IY, Cho YW, Park ES, Park SE, Nah YW, Park CR. Experience without using venovenous bypass in adult orthotopic liver transplantation. *Korean J Anesthesiol* 2011; 60(1):19-24.
15. Lee J. Would routine avoidance of veno-veno bypass be possible during liver transplantation? *Korean J Anesthesiol.* 2011; 60(1):1-2.
16. Miranda LEC, Melo PSV, Lima DL, Sabat B, Amorim AG, Fonseca Neto OCL, Lopes HC, Lemos R, Leitão L, Lacerda CM. Liver transplantation: a 10-year single center experience in Pernambuco – Northeastern Brazil. *JBT J Bras Transpl* 2010; 13:1221-1275.
17. Miyamoto S, Polak WG, Geuken E, Peeters PMJG, de Jong KP, Porte RJ, Van Den Berg AP, Hendriks HG, Slooff MJH. Liver transplantation with preservation of the inferior vena cava. A comparison of conventional and piggyback techniques in adults. *Clin Transplant* 2004; 18:686-693.
18. Nikeghbalian S, Dehghani M, Salahi H, Bahador A, Kazemi K, Kakaei F, Rajaei E, Gholami S, Malek-Hosseini SA. Effects of surgical technique on postoperative renal function after orthotopic liver transplant. *Exp Clin Transplant.* 2009 Mar;7(1):25-7.
19. Pere P, Höckerstedt K, Isoniemi H, Lindgren L. Cerebral blood flow and oxygenation in liver transplantation for acute or chronic hepatic disease without venovenous bypass. *Liver Transpl.* 2000 Jul;6(4):471-9.
20. Sakai T, Matsukaki T, Marsh JW, Hilmi IA, Planinsic RM. Comparison of surgical methods in liver transplantation: retrohepatic caval resection with venovenous bypass (VVB) versus piggyback (PB) with VVB versus PB without VVB. *Transplant International* 2010; 23:1247-1258.
21. Schroeder RA, Collins BH, Tuttle-Newhall E, Robertson K, Plotkin J, Johnson LB, Kuo PC. Intraoperative fluid management during orthotopic liver transplantation. *J Cardiothorac Vasc Anesth* 2004; 18(4):438-441.
22. Schwarz B, Pomaroli A, Hoermann C, Margreiter R, Mair P. Liver transplantation without venovenous bypass: morbidity and mortality in patients with greater than 50% reduction in cardiac output after vena cava clamping. *J Cardiothorac Vasc Anesth* 2001; 15(4):460-462.
23. Shaw Jr BW, Martin DJ, Marquez JM, Kang YG, Bugbee Jr AC, Iwatsuki S, Griffith B, Hardesty RL, Bamnson HT, Starzl TE. Advantages of venous bypass during orthotopic transplantation of the liver. *Seminars in Liver Disease* 1985, 5(4):344-348.
24. Shaw Jr BW. Some further notes on venous bypass for orthotopic transplantation of the liver. *Transplant Proc* 1987; 29(4):13-16.
25. Shokouh-Amiri MH, Gaber AO, Bargous WA, Grewal HP, Hathaway DK, Vera SR, Stratta RJ, Bagous TN, Kizilisik T. Choice of surgical technique influences perioperative outcomes in liver transplantation. *Ann Surg* 2000; 231(6):814-823.
26. Starzl TE, Groth CG, Brettschneider L, Penn I, Fulginiti VA, Moon JB, Blanchard H, Martin Jr AJ, Porter KA. Orthotopic homotransplantation of the human liver. *Ann Surg* 1968; 168:392-415.
27. Tzakis A, Todo S, Starzl T. Orthotopic liver transplantation with preservation of the inferior vena cava. *Ann Surg* 1989; 210(5):649-652.
28. Witkowski K, Piecuch J. Liver transplant without a venovenous bypass. *Ann Transplant.* 2001;6(1):16-7.
29. Wojcicki KS, Jarosz K, Czuprynska M, Lubikowski J, Zeair S, Bulikowski J, Gasinska M, Andrzejewska J, Surudo T, Mysliwiec J. Liver transplantation for fulminant hepatic failure without venovenous bypass and without portacaval shunting. *Transplant Proc* 2005; 38:215-218.
30. Wu Y, Oyos TL, Chenhsu R-Y, Katz DA, Brian JE, Rayhill SC. Vasopressor agents without volume expansion as a safe alternative to venovenous bypass during cavaplasty liver transplantation. *Transplantation* 2003; 76(12):1724-1728.