

BENIGN BILIARY STRICTURES: REPAIR AND OUTCOME WITH THE USE OF SILASTIC TRANSHEPATIC TRANSANASTOMOTIC STENTS

Estenoses biliares benignas: reparação e resultado com o uso de stents de silastic transhepático transanastomótico

José Artur **SAMPAIO**, Cristine Kist **KRUSE**, Thiago Luciano **PASSARIN**,
Fábio Luiz **WAECHTER**, Mauro **NECTOUX**, Paulo Roberto Ott **FONTES**, Luiz **PEREIRA-LIMA**

From the Departamento de Clínica Cirúrgica da Universidade Federal de Ciências da Saúde de Porto Alegre and Serviço de Cirurgia Hepatobiliopancreática e Transplante Hepático da Santa Casa de Porto Alegre, Porto Alegre, RS, Brasil

ABSTRACT – Background - The medical advances is not always related to homogeneous good results for all the patients. This is the case of laparoscopic cholecystectomy, whose advantages are largely recognized in the medical literature. However, this operation most dreaded complication, iatrogenic major bile duct injury, is rising in the last years, despite the learning curve, and stabilized in a level higher than that experienced in open cholecystectomy. Among the features which can bring to this event a good outcome is the use of transhepatic transanastomotic tubes in association with the corrective hepaticojejunostomy. **Aim** - To report a 20 years experience on biliary reconstruction of bile duct injuries with the use of transhepatic transanastomotic tubes. **Methods** - Data were analysed from 338 patients who underwent operation for major bile duct injuries between January 1988 and December 2009. **Results** - All the 338 patients were submitted to Roux-en-Y hepaticojejunostomy (Hepp-Couinaud approach) or distinct cholangiojejunostomies, all with the use of transhepatic transanastomotic silastic tubes. A successful long-term result was achieved in 240 (92,9%) of 338 patients, including those who required subsequent procedures. **Conclusion** - Benign bile duct strictures near the hepatic duct confluence remains a surgical challenge. The use of silastic transhepatic transanastomotic tubes in high biliary tract reconstruction is an option which can provides a successful repair of bile duct injuries with low complication rates.

HEADINGS – Biliary surgical procedure. Benign biliary strictures. Stents. Surgery.

Correspondence:

José Artur Sampaio,
e-mail: jartur@terra.com.br

Fonte de financiamento: não há
Conflito de interesses: não há

Recebido para publicação: 10/06/2010
Aceito para publicação: 13/09/2010

RESUMO - Racional - Os avanços da medicina nem sempre estão relacionados a bons resultados homogêneos para todos os pacientes. Este é o caso de colecistectomia laparoscópica, cujas vantagens são amplamente reconhecidos na literatura médica. No entanto, ela pode trazer consigo temida e grave complicação que é lesão iatrogênica da via biliar extra-hepática. Ela vem aumentando nos últimos anos, apesar da curva de aprendizagem já estar ultrapassada na maioria dos centros. Está estabilizada em nível mais elevado do que o registrado nas colecistectomias laparotômicas. Na reparação das grandes lesões bom resultado pode ser alcançado com a utilização de tubos transanastomóticos em associação à hepaticojejunostomias. **Objetivos** – Relatar 20 anos de experiência na reconstrução das vias biliares por lesão ductal com o uso de tubos transanastomóticos. **Métodos** - Foram analisados os dados de 338 pacientes que se submeteram à operação para as principais lesões do ducto biliar entre janeiro de 1988 e dezembro de 2009. **Resultados** - Todos os 338 pacientes foram submetidos à hepaticojejunostomias com anastomoses em Y-de-Roux (Hepp-Couinaud) ou colangiojejunostomias, todos com o uso de tubos de silastic transanastomóticos. A longo prazo, bom resultado foi obtido em 240 (92,9%) dos 338 pacientes, incluindo aqueles que necessitaram de procedimentos subsequentes. **Conclusão** – Estenoses biliares benignas próximas à confluência dos ductos hepáticos permanece sendo desafio cirúrgico. O uso de tubos de silastic transhepáticos transanastomóticos na reconstrução biliar alta é opção que pode proporcionar boa reparação biliar com baixos índices de complicações.

DESCRITORES - Estenoses biliares. Stents. Cirurgia. Via biliar.

INTRODUCTION

Benign biliary strictures are a surgical challenge even for experienced hepatobiliary surgeons. If unrecognized or improperly treated, serious complications like biliary cirrhosis, cholangitis, portal hypertension and even death can occur. In most cases, the bile duct stricture is secondary to biliary tract operations, especially cholecystectomy, with an incidence of major bile duct injury in the open procedure reported as 0,04% to 0,2%²³, compared to 0,1% to 1%^(4, 10) in the laparoscopic approach. Other causes include fibrosis due to chronic pancreatitis, choledocolithiasis, hepatoduodenal papilla stenosis, primary sclerosing cholangitis and abdominal trauma. To avoid the described life-threatening complications, patients with bile duct strictures must be investigated and properly treated with the aim of relieving the bile flow obstruction and its associated hepatic injury.

The aim of this paper is to describe the authors experience with the treatment of benign bile duct strictures with the use of transhepatic transanastomotic stents associated with the Hepp-Couinaud technique, which capitalizes on the relatively long extrahepatic course of the left main hepatic duct nestled beneath the quadrate lobe (hepatic segment IV), and the long-term outcomes.

METHODS

Data were collected retrospectively on all patients with a complex postoperative bile duct stricture or major bile duct injury (Bismuth III-IV-V) treated with definitive reconstructive biliary surgery by the senior author between January 1, 1988 and December 31, 2009.

Were included in the analysis group all patients with major lesions of the biliary tree, i.e., transections or partial lacerations of the common bile duct or major segmental ducts at the porta hepatis. Were also included patients with postoperative bile duct strictures secondary to open or laparoscopic cholecystectomy, common bile duct exploration, bilioenteric or biliary anastomosis, or injury to the biliary tree associated with another abdominal surgery.

Were excluded from this report patients with malignant disease, minor leaks (i.e., gallbladder bed, Luschka ducts or cystic duct), or bile duct strictures secondary to benign inflammatory process like chronic pancreatitis, biliary tract infections or stones, primary sclerosing cholangitis, liver transplantation, between others.

Data collection

Data were collected retrospectively on all patients. The medical records were reviewed with reference to cause, details of clinical and surgical

management, hospital course and outcome. Follow-up was obtained by review of records of subsequent visits and supplemented by phone interviews with the patient, and the length was calculated from the date of definitive surgical repair. Outcome assessments were completed through June 30, 2010 on all patients based on direct patient contact or hospital/office records. The strictures were classified on the basis of radiologic and operative findings after the method of Bismuth.

The patients current status was rated subjectively as treatment successes, if they were excellent, asymptomatic from the biliary tract reconstruction, or good, if mild symptoms with no need of invasive investigation or treatment. Treatment failures were considered on patients who needed invasive investigational or therapeutic procedures, either surgical or radiologic, to treat symptoms or stricture recurrence.

Data analysis

Clinical management and operative technique

The biliary tree was studied in the preoperative period with percutaneous transhepatic cholangiography and, more recently, magnetic resonance cholangiopancreatography (Figure 1) in all patients. Surgery was performed promptly unless in those patients with sepsis, biliary fistula, right upper quadrant abscess or inflammatory process, when surgery was postponed until better local conditions were achieved. When major bile duct injuries were associated with ongoing biliary leak, percutaneous drainage of bile duct collections or ascitis was performed. Furthermore, specific treatment was indicated if the patients were septic. In both cases, definitive treatment was postponed by four to six weeks with the aim to reduce the local inflammatory response.

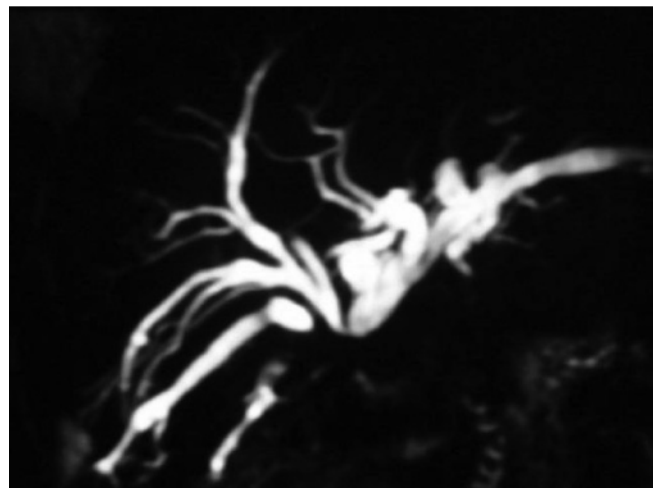


FIGURE 1 - Magnetic resonance cholangiopancreatography: Strasberg E3 biliary tract stricture following open cholecystectomy.

The standard surgical treatment was an end-to-side Roux-en-Y hepaticojejunostomy (Hepp-Couinaud approach) with placement of one to three silastic transhepatic tubes depending on the number of anastomosed bile ducts. When the bile duct confluence was not available, distinct cholangiojejunostomies were performed (Figure 2). After dissection of the porta hepatis, a hilar plate section was performed to allow the exposure of the left hepatic duct, and careful exploration of the left and right hepatic ducts was done, and the cephalic dissection stopped when healthy ducts, i.e. with no ischemic, scarred or inflamed ducts were reached. In some cases, when the bile duct confluence was not available, independent anastomosis between the right and left bile ducts and the defunctionalized jejunal loop was performed. In some cases it was necessary a partial resection of hepatic segment IVA to expose healthy intrahepatic bile ducts. For the positioning of the silastic transhepatic transanastomotic stents, it is introduced a Randall forceps inside the intrahepatic ductal lumen and exteriorized across the hepatic dome; then, the tube (usually a 10F silastic tube) was fixed to the tip of the Randall forceps with a silk suture and delivered through the duct. A side-to-side anastomosis with a minimum stoma size of 2 cm employing a 60 cm Roux-en-Y jejunal limb was performed with 4.0 to 6.0 polydioxanone (PDS®; Ethicon, Hamburg, Germany) or Prolene® sutures, with the transhepatic stent placed across the anastomosis. From the hepatic dome until the exterior, the silastic stent was involved by a laminar drain as previously published by our group¹⁷ (Figure 3). The transhepatic tubes were connected to external drainage until day 4 after surgery, when they were closed and flushed twice a day with 10 to 20 ml of 0,9% isotonic sodium chloride solution. Patients were discharged home between the 10th and 14th postoperative day, and followed up on an outpatient basis. Between 6th and 12th postoperative months, stents were removed after a cholangiogram had been done (Figure 4).

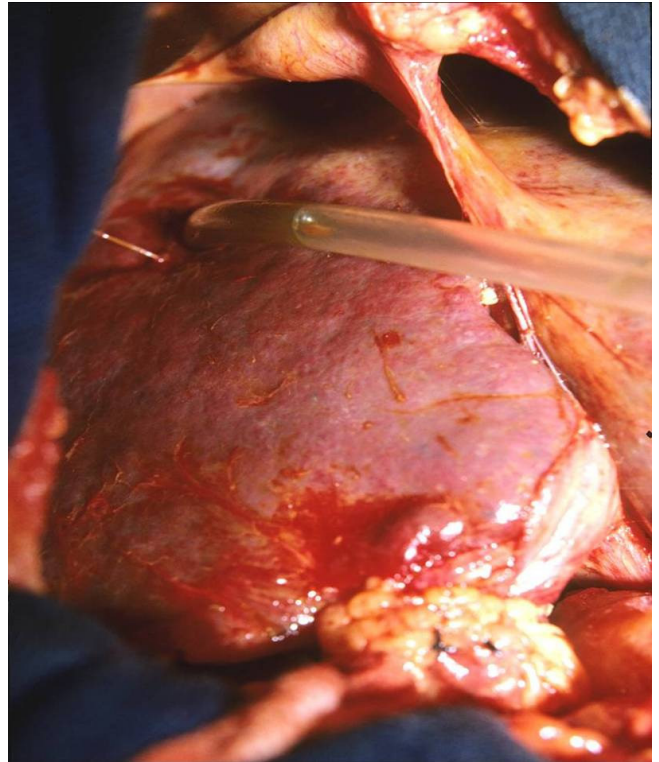


FIGURE 3- View of the diaphragmic liver surface with the transhepatic transanastomotic stent in situ

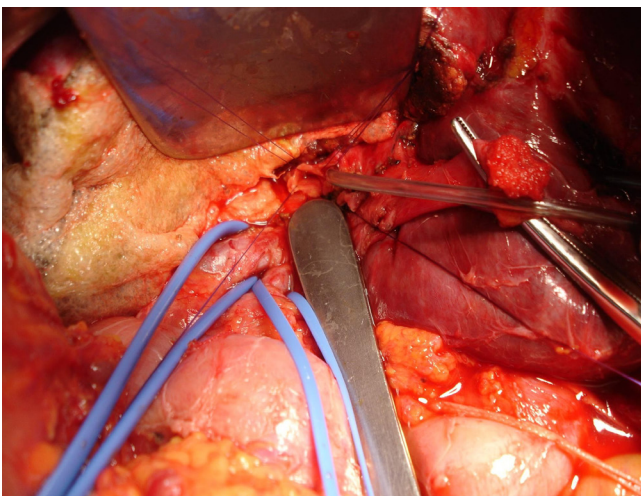


FIGURE 2 - Cholangiojejunostomy with transhepatic transanastomotic stent in situ

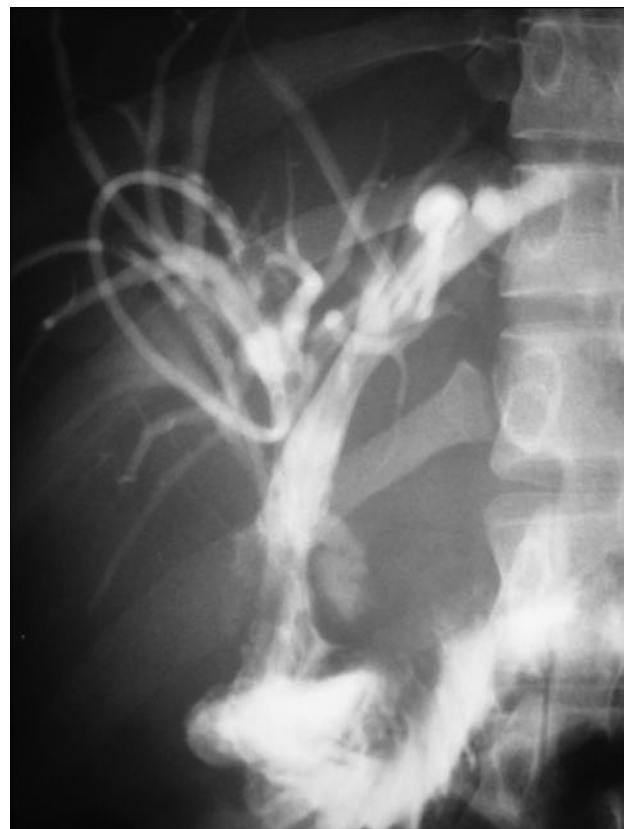

FIGURE 4 - Cholangiogram in the post-operative period

Anastomosis dysfunction was considered in cases of obstructive jaundice, progressive elevation of alkaline phosphatase and direct bilirubin, intrahepatic biliary tree dilatation on follow-up abdominal ultrasound, cholangitis and hepatic abscess. Reoperation constituted in a new Hepp-Couinaud's anastomosis or partial resections of liver segment IV at the level of the gallbladder plate to allow exposure of intrahepatic bile ducts, with a transhepatic transanastomotic stent in all cases.

RESULTS

A total of 338 patients was referred to the senior author to biliary tract reconstruction. Two hundred and fifty patients (74%) were female. The mean age was 45 +/- 17 years (range 19-77 years); 213 patients (63%) were white; 81 (24%) black and 44 (13%) from another ethnic group.

As summarized in Table 1, the original surgical procedure was laparoscopic cholecystectomy in 238 patients (70,4%), open cholecystectomy in 74 (21,9%), common bile duct exploration in 25 (7,4%) and another abdominal surgery in 1 (0,3%). In 46 patients (13,6%), the injury was recognized in the first procedure and immediate surgical repair was attempted by the original surgeon, all with anastomotic failure in the follow-up. In 115 patients (34%), there was an attempt to repair surgery by the original surgeon after recognition of the biliary tract injury in the post-operative period, all with Roux-en-Y hepaticojejunostomy. In total, 161 patients (47,6%) had undergone previous attempts of repair before referral. There was no statistical difference in frequency of biliary tract injury between laparoscopic and open cholecystectomy.

TABLE 1 – Patient characteristics (n 338)

Female	250 (74%)
Median age (years)	45 +/-17 (19-77)
Original surgery	
- Laparoscopic cholecystectomy	238 (70,4%)
- Open cholecystectomy	74 (21,9%)
- Common bile duct exploration	25 (7,4%)
Attempts to repair by the original surgeon	
- In the first procedure	46 (13,6%)
- In the post-operative period	115 (34%)
Status at referral	
- Ongoing bile leak	132 (39,1%)
- Obstructive jaundice	112 (33,1%)
- Cholangitis	94 (27,8%)

The time interval between the original operation and referral for our group was 1 day to 14 months (mean 2 months), with interval inferior to 30 days for 176 patients (52,1%). At time to referral, 132 patients (39,1%) had an ongoing bile leak, 112 patients (33,1%) obstructive jaundice and 94 patients (27,8%) cholangitis.

All the reconstructive operations were performed by the senior author. The Bismuth classification of biliary tract injury was Bismuth III in 274 patients (81,1%), Bismuth IV in 47 patients (13,9%) and Bismuth V in 17 patients (5%). The Hepp-Couinaud approach with transhepatic transanastomotic stents was done in 281 patients (83,1%), and 57 patients (16,9%) needed distinct cholangiojejunostomies secondary to destruction of the bile duct confluence. One stent was used in 57 patients (16,9%), two in 267 patients (79%) and three in 14 patients (4,1%).

Postoperative complications are presented in Table 2, with no hemobilia or biliary sepsis. There was no mortality in the 30 days postoperative period. Mean follow-up was 46 months. Good long term results (clinically asymptomatic) were obtained in 240 patients (92,9%). Twenty four (7,1%) patients required radiologic dilatation, and 11 (3,2%) a reoperation due to anastomotic disfunction irresponsable to percutaneous treatment.

TABLE 2 – Post-operative complications

Operative mortality	0
Anastomosis dysfunction	
Radiologic dilatation	24 (7,1%)
Operative management	11 (3,2%)
Complications	
Biliary fistula	33 (9,8%)
Postoperative lithiasis	37 (10,6%)
Subhepatic collection	41 (12,1%)
Subphrenic collection	32 (9,5%)
Intrahepatic abscess	28 (8,3%)
Hemobilia	0
Biliary sepsis	0

DISCUSSION

Benign strictures of the biliary tract secondary to iatrogenic injuries, fistulas or recurrent ascendant cholangitis constitute a continuing serious challenge to the hepatobiliary surgeon, because those pathologic conditions usually modify the quality of the bile duct wall at the porta hepatis with inflammatory changes. A postoperative bile duct stricture is a serious complication that usually occurs as a result of a technical mishap associated with cholecystectomy. Bile duct injuries complicating laparoscopic cholecystectomy fortunately remain uncommon, with an incidence of major bile duct injury of 0,4% to 0,6% in large populations databases⁴. The overall mortality for laparoscopic cholecystectomy without technical mistakes is 0,45%, yet can be as high as 9% when a bile duct injury occurs²⁵. The management of a post-cholecystectomy bile duct injury costs 4.5 to 26 times the cost of a cholecystectomy²⁴, so it has also a significant economic impact in hospitalar costs. Also, this entity is associated with the economic mishap of postponed return to work because of increased morbidity when compared to laparoscopic

cholecystectomy.

The results are related to the initial management of the entity, as the successful management of bile duct injuries depends upon several factors, like as early detection, the accurate evaluation of the injury, the timing and selection of the remedial procedure and the experience of the center. In the case of iatrogenic lesions following cholecystectomy, the majority of the lesions are missed at surgery, with only 16-25% being detected in the original operation^{20,26}. The first attempt at repair of a benign biliary stricture is the best opportunity to achieve a good long term outcome, as repairs of recurrent strictures may be associated with a poor outcome^{16,20}. Even though the immediate consequences of bile duct injury and stricture are significant⁹, the long-term results after repair can be considered the procedure success determinants. If the biliary tract injury is unrecognized or managed improperly, life-threatening complications, such as biliary cirrhosis, portal hypertension and cholangitis, can develop. The outcome of a repair can be altered by many factors, including timing of repair, infection, vascular injury, level of injury and operative technique²⁹. The outcome is better when the patient is sent to a specialized tertiary center before any attempt to a biliary-enteric anastomosis is made³⁰.

Surgical repair of hilar strictures is associated with worse outcomes as compared to the repair of lesions below the hepatic confluence. Monteiro da Cunha JE, et al.¹³, in a 49 patient series, found that stricture recurrence and cholangitis occurred in 14% of patients with hilar lesions, whereas no patient with lesions below the hepatic duct bifurcation had such complications.

The bile duct reconstruction was made by the Hepp-Couinaud approach^{5,6}, which incorporates the extrahepatic portion of the left main hepatic duct. In this technique, it was incised the hilar plate (condensation of the endoabdominal fascia located beneath the base of the quadrate lobe) and retract cephaladly the base of hepatic segment IV to exposure of the left hepatic duct, followed by an anterior opening of this duct, providing a satisfactory length of healthy mucosa for anastomosis. This is an excellent option to repair high strictures, because the left hepatic duct is protected from infection and inflammatory reaction secondary to bile leakage by the conjunctive tissue of the hilar plate, and the location at the base of hepatic segment IV prevents iatrogenic injury during surgery. Also, the left hepatic duct has a rich blood supply of the hepatic parenchyma, in contrast to the tenuous coaxial blood supply of the common hepatic duct. The anastomosis has to be performed with nonreactive absorbable sutures and with accurate apposition of the intestinal mucosa and the biliary epithelium, allowing a very wide-mouth, side-to-side, bile duct-to-jejunal anastomosis.

Temporary stenting and bile diversion from the anastomosis remains controversial. Experienced groups have shown good results with and without

stents^{2,3,7,8,11,12,17,21}, polarizing their positions on the use and misuse of transanastomotic stents. Those who favour stenting and decompression of the biliary tree claim a lower probability of postoperative stricture^{1,15}; others, have found equivalent results without stenting^{5,28}. In the immediate post-operative period, transanastomotic stents assures the anastomosis patency despite postoperative transitory edema, thus lowering the intraductal pressure and bile leakage, with their local inflammatory response and the consequent fibrosis of the perianastomotic zone secondary to the healing process with disruption of the intestinal mucosa-biliary epithelium apposition. During the next postoperative months, healing of the anastomosis around the stent assures that it will have at least the stents diameter and allows for manipulation and/or dilatation of the anastomosis. However, the silastic stent is a foreign body and some groups defends that this prolonged use can predispose to stenosis because of the inflammatory process and consequent fibrosis derived from local irritation. It can be also related to stone formation, and, if the stent is too large to the duct diameter, it can cause pressure necrosis of the bile duct with consequent fibrosis, leading to stenosis after removing the tube. Also, transhepatic transanastomotic stenting diverts biliary secretions externally in the face of a leak, which is one of the major advantages of this technique

The transhepatic stents plays an important role in hepatobiliopancreatic surgery centers specialized in biliary tree reconstruction because they allows a successful overall outcome for the majority of the patients in this and other series, re-stenosis of the bilioenteric anastomosis years after operative repair cannot be excluded. Two-thirds of recurrences occur within the first 2 years but stricture recurrence after 20 years^{10,18,27} has also been reported.

Transanastomotic stents were used in 43 patients for 45 +/- 3 days postoperatively in a Mayo Clinic series¹⁴ of 51 patients, with the reconstruction in a Hepp-Couinaud fashion. The stents use criteria was not mentioned in the manuscript. Eight three percent were classified as Strasberg E2-E5 (56% was E3-E4-E5). In a mean follow-up of 3.7 +/- 0.3 years, excellent result was observed in 85%, and 5% developed anastomotic stricture that required intervention.

Schmidt, et al.²⁵, in a series of 54 iatrogenic bile duct trauma following cholecystectomy patients who underwent Roux-en-Y hepaticojejunostomy in a mucosa-to-mucosa technique with transhepatic transanastomotic stents for three months, observed excellent results in 93%, including some patients who underwent subsequent procedures for new stenosis; 15% developed biliary stricture, and 8% secondary biliary cirrhosis. Multivariate analysis with stepwise logistic regression identified repair in the presence of peritonitis (p = 0.002), high injuries (p = 0.012) and concomitant vascular injuries (p = 0.029) as independent

risk factors for major biliary complications (new stenosis, fistula, bilioma, secondary biliary cirrhosis, cholangiocarcinoma).

Quintero and Patino²², in a 65 patients series of Roux-en-Y hepaticojejunostomies without transhepatic tubes, had 9,2% of failures, characterized by new strictures. However, only 20% of the patients had lesions Bismuth III-IV-V, where the use of transhepatic tubes is considered mandatory in our service. On the other hand, Lillemoe et al, in a 156 patients series with mean follow-up of 57,5 months, used transhepatic stents for 12 months in 100% of Roux-en-Y hepaticojejunostomy patients, and also had 9,2% of failures in a 55,1% Bismuth III-IV-V series.

The John Hopkins group recommends final stent removal to occur at different stages, according to individual characteristics of each patient, specially when adequate proximal bile duct is not available for a good mucosa-to-mucosa anastomosis¹⁰. Most of their patients (62,7%) had a stent in place for more than nine months. In this series, the analysis of factors predicting outcome after surgical repair showed that the length of stent placement did not influence the long-term outcome.

Mercado, et al.¹² in a 63 patients series over a decade period, used transhepatic transanastomotic stents in 37 patients and 26 patients had no stent. The criteria for the stents use was the absence of a healthy duct (i.e., without scar, inflammatory or ischemic lesion), bile duct smaller than 4 mm or necessity for separated anastomosis. On the other hand, easier cases without those criteria did not use transhepatic stents. Mean follow-up was 26 months, and good results were obtained in 90% of the stent group and in 86% of the nonstent group. The results of this series has a selection bias – the hardest cases prone to failure had the transhepatic transanastomotic stents and, even then, the results were better than the nonstent group. In their conclusion, they favor the selective placement of a stent if a difficult anastomosis has been done in an “unhealthy” duct with a small diameter.

Some authors preclude an increased failure rate for patients who underwent previous repair attempts¹⁹. In our series, 47,6% were secondary repairs, and good long term results were obtained in a majority of the cases. These results are very similar to a Pellegrini CA, Thomas MJ, Way LW¹⁶, who affirm that excellent results can be achieved in most patients undergoing secondary operation.

CONCLUSION

Iatrogenic bile duct injury after cholecystectomy is a devastating complication of a common and apparently “simple” surgical procedure, and prevention is the best policy, with better training of surgeons, careful dissection of the Calot trigone until the “critical view

of safety” can be accomplished and a low threshold to switch to the laparotomic approach, in case of a difficult procedure. The key to the successful management of these injuries lies on continued vigilance during and after the cholecystectomy, hoping to early recognition. Injuries should be early referred to tertiary centers with hepatobiliopancreatic surgery experience and expertise, where a complete field of diagnostic and treatment modalities are available, ensuring to the patient the best opportunity for an good long-term result.

REFERENCES

1. Blumgart LH, Kelley CJ, Benjamin IS. Benign bile duct stricture following cholecystectomy: critical factors in management. *Br J Surg* 1984; 71: 836–843.
2. Buell JF, Cronin DC, Funaki B, Koffron A, Yoshida A, et al. Devasting and fatal complications associated with combined vascular and bile duct injuries during cholecystectomy. *Arch Surg* 2002;137:703-10.
3. Cameron JL, Gayler BW, Zuidema GD. The use of silastic transhepatic stents in benign and malignant biliary strictures. *Ann Surg* 1978;188(4):552-9.
4. Deziel DJ, Millian KW, Ezonmou SG, et al. Complications of laparoscopic cholecystectomy: a national survey of 4292 hospitals and an analysis of 77604 cases. *Am J Surg* 1993;165:9/14.
5. Hepp J. Hepaticojejunostomy using the left biliary trunk for iatrogenic biliary lesions: the French connection. *World J Surg* 1985;9:507-11.
6. Hepp J, Couinaud C. L'abord et l'utilisation du canal hepatique gauche dans le reparations de la voie biliare principale. *Presse Med* 1956;64:947-8.
7. Jamgin WR, Blumgarth LH. Operative repair of bile duct injuries involving the hepatic duct confluence. *Arch Surg* 1999;134:769-75.
8. Lillemoe KD, Melton GB, Cameron JL, Pitt HA, Campbell KA, Talamini MA, et al. Postoperative bile duct strictures: management and outcome in the 1990s. *Ann Surg* 1999;134:604-10
9. Lillemoe KD, Martin SA, Cameron JL, et al. Major bile duct injuries during laparoscopic cholecystectomy. *Ann Surg* 1997;225:459-71.
10. Lillemoe KD. Benign post-operative bile duct strictures. *Bailliere's Clinical Gastroenterology* 1997;11(4):749
11. McDonald ML, Farnell MB, Nagorney DM, Ilstrup DM, Kutch JM. Benign biliary strictures: repair and outcome with a contemporary approach. *Surgery* 1995;118(4):582-91.
12. Mercado MA, Chan C, Orozco H, Cano-Gutierrez G, Chaparro JM, Galindo E, et al. To stent or not to stent bilioenteric anastomosis after iatrogenic injury: a dilemma not answered? *Arch Surg* 2002;137:60-3.
13. Monteiro da Cunha JE, Machado MC, Herman P, Bacchella T, Abdo EE, Penteado S, Jukemura J, Montagnini A, Machado MA, Pinotti HW. Surgical treatment of cicatricial biliary strictures. *Hepatogastroenterology* 1998;45(23):1452-6.
14. Murr MM, Gigot JF, Nagorney DM, Harmsen WS, Ilstrup DM, Farnell MB. Long-term results of biliary reconstruction after laparoscopic bile duct injuries. *Arch Surg* 1999;134:604-10.
15. Nealon WH, Urrutia f. Long-term follow-up after bilioenteric anastomosis for benign bile duct stricture. *Ann Surg* 1996;223:639-48.
16. Pellegrini CA, Thomas MJ, Way LW. Recurrent biliary stricture: patterns of recurrence and outcome of surgical therapy. *Am J Surg* 1984;147:175-80.
17. Pereira-Lima L, Falavigna L, Sales MC. Técnica e manejo dos tubos trans-hepáticos nas estenoses da via biliar. *R. Pesquisa Médica* 1989;23(1):25-8.
18. Pitt HA, Kaufman SL, Coleman J, White RI, Cameron JL. Benign postoperative biliary strictures: operate or dilate? *Ann Surg* 1989;210(4):417-25.
19. Pitt HA, Miyamoto T, Parapatis SK, Tompkins RK, Longmire WP Jr. Factors influencing outcome in patients with postoperative biliary duct strictures. *Am J Surg* 1982;144:14-21
20. Pottakkat B, Sikora SS, Kumar A, Saxena R, Kapoor VK. Recurrent bile

- duct stricture: causes and long-term results of surgical management. *J Hepatobiliary Pancreat Surg* 2007;14:171-6.
21. Praderi RC. Twelve years' experience with transhepatic intubation. *Ann Surg* 1974;179(6):937-40.
 22. Quintero GA, Patino JF. Surgical management of benign strictures of the biliary tract. *World J Surg* 2001;25:1245-50.
 23. Roslyn JJ, Binns GS, Hughes EFX, Kirkwood KS, Zinner MJ, Cates JA. Open cholecystectomy – a contemporary analysis of 42474 patients. *Ann Surg* 1993;218:129-37.
 24. Savader SJ, Lillemoe KD, Prescott CA, Winick AB, Venbrux AC, Lund GB, et al. Laparoscopic cholecystectomy-related bile duct injuries – a health and financial disaster. *Ann Surg* 1997;25:268-73.
 25. Schmidt SC, Langrehr JM, Hintze RE, Neuhaus P. Long-term results and risk factors influencing outcome of major bile duct injuries following cholecystectomy. *Br J Surg* 2005;92:76-82.
 26. Stewart L, Way LW. Bile duct injuries during laparoscopic cholecystectomy – factors that influence the results of treatment. *Arch Surg* 1995;103:1123-8.
 27. Sutherland F, Lanois B, Staescu M, Campion JP, Spiliopoulos Y, Stasik C. A refined approach to the repair of postcholecystectomy bile duct strictures. *Arch Surg* 1999;134:299-302.
 28. Tocchi A, Costa G, Lepre L, Liotta G, Mazzoni G, Sita A. The long-term outcome of hepaticojejunostomy in the treatment of benign bile duct strictures. *Ann Surg* 1996; 224: 162–167.
 29. Walsh RM, Henderson JM, Vogt DP, Brown N. Long-term outcome of biliary reconstruction for bile duct injuries from laparoscopic cholecystectomies. *Surgery* 2007;142(4):450-7.
 30. Walsh RM, Vogt DP, Ponsky JL, et al. Management of failed biliary repairs for major bile duct injuries after laparoscopic cholecystectomy. *J Am Coll Surg* 2004;199:19.