

SUBTOTAL SPLENECTOMY FOR SPLENIC ABSCESS*Esplenectomia subtotal para abscesso esplênico*

Rachid Guimarães NAGEM, Andy PETROIANU

ABCDDV/600

Nagem RG, Petroianu A. Subtotal splenectomy for splenic abscess. ABCD Arq Bras Cir Dig. 2008;21(2):92-4

ABSTRACT - Background - Splenic abscess is a rare condition but carries high mortality (up to 100% when untreated) and surgery has been the standard of therapy. **Case report** - An adult male had been undergone thrombolytic therapy for a heart attack and presented spontaneous intrasplenic hematoma which, subsequently, have turned into an abscess. Once it was a large multiloculated collection, subtotal splenectomy was the only treatment that could spare some splenic tissue. This approach was carried out successfully and the patient is presently healthy. **Conclusion** - Subtotal splenectomy is an effective option for the management of splenic abscesses.

HEADINGS - Splenic abscess. Subtotal splenectomy.

INTRODUCTION

Splenic abscess generally occurs in patients with neoplasia, immunodeficiency, hemoglobinopathies, trauma, metastatic infection, splenic infarct and diabetes¹¹. This condition, although rare, has high mortality rates¹⁶. Despite the proven safety and efficacy of percutaneous drainage technique^{6,17}, surgery remains as the gold standard for splenic abscess therapy^{1,4,9}. Total splenectomy was considered the best surgical procedure until recently⁵. Today the susceptibility to infection and thromboembolic events after splenectomy has been emphasized¹⁴ and conservative procedures over the spleen are quite common. In subtotal splenectomy the spleen is resected and its upper part is kept in place. Viability is warranted by splenogastric vessels¹².

CASE REPORT

A 49-year-old man was admitted to emergency department with retrosternal chest pain. Electrocardiogram (ECG) and cardiac enzymes revealed acute myocardial infarction (AMI) and thrombolytic therapy was used with satisfactory results. Two days later the patient complained sudden onset of upper left quadrant pain. Abdominal ultrasound (US) and computed tomography (CT) showed a large collection inside the spleen and the diagnosis of spontaneous intrasplenic hematoma secondary to thrombolytic agent was established. Non surgical treatment was indicated. The patient was doing well until two weeks later when he presented with abdominal

pain, fever with chills and leukocytosis. An multiloculated splenic collection involving almost the entire organ, suggesting abscess, was identified by CT (Figure 1). US-guided needle aspiration confirmed the diagnosis. Supraumbilical laparotomy was carried out through a midline incision and subtotal splenectomy was performed (Figures 2 and 3). The organ was dissected free from his attachments and brought towards the anterior abdominal wall. Then all the splenic vessels were ligated except the splenogastric ones. The spleen was divided using the ischemic transition area as a landmark. The remnant was sutured with 2-0 chromic catgut stitches (Figures 4 and 5). Culture samples grew staphylococcus aureus and the patient received venous antibiotic treatment for thirty days before being discharged. At 1 year' follow-up he was asymptomatic and disease-free (Figure 6).

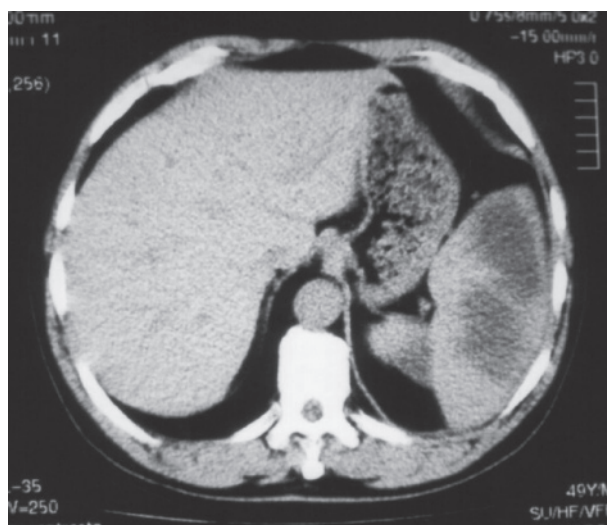

FIGURE 1- CT shows splenic abscess

From the Department of Surgery - Hospital dos Servidores do Estado de Minas Gerais (IPSEMG), Belo Horizonte, MG, Brazil

Address for correspondence: Rachid G. Nagem. E-mail: rgnagem@yahoo.com.br

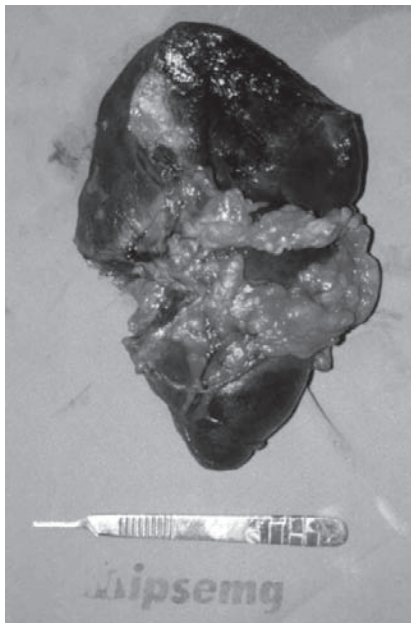


FIGURE 2 - Resected spleen. Note the section area in the upper pole

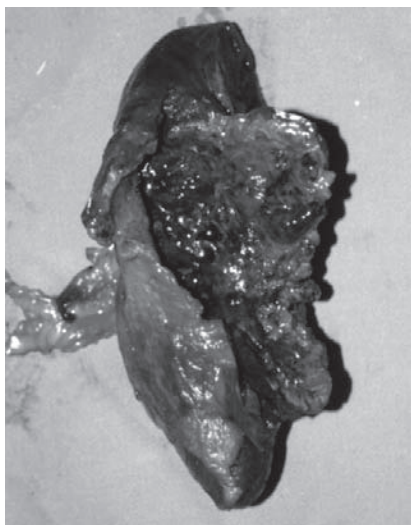


FIGURE 3 - Resected spleen: internal aspect of the abscess is shown.

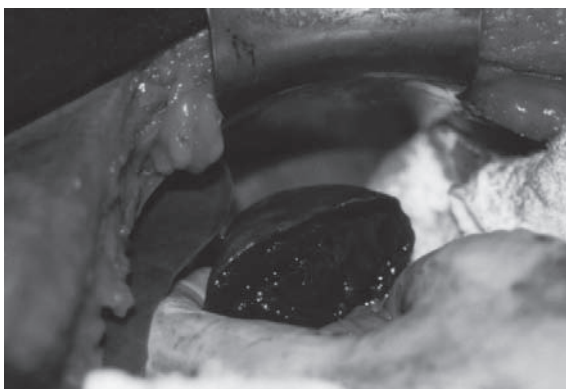


FIGURE 4 - Splenic remnant into the abdominal cavity

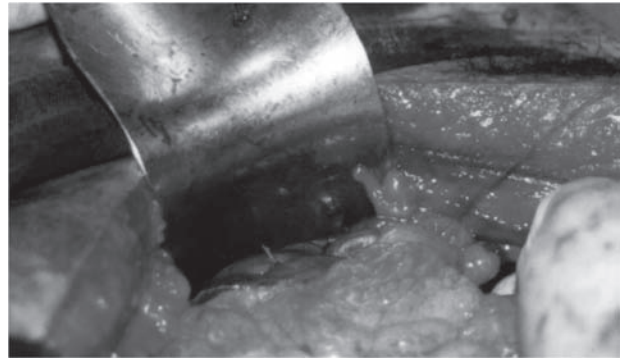


FIGURE 5 - Splenic remnant: an omentum buttress had been sutured over the raw edge of tissue left by the resection.

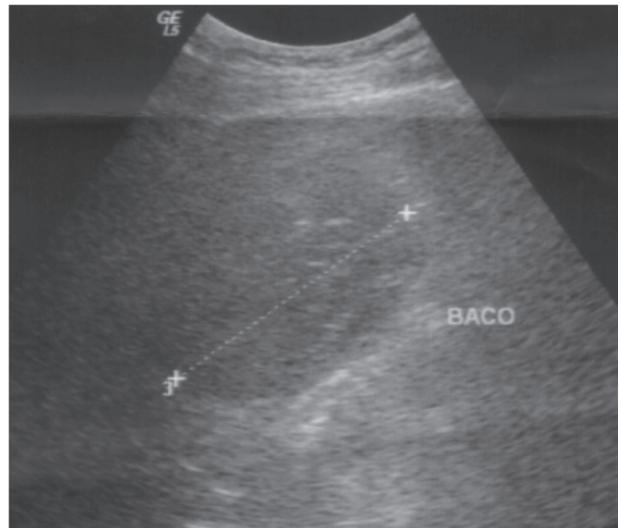


FIGURE 6 - Post-operative US showing splenic remnant

DISCUSSION

Splenic abscess is a rare entity. Autopsy studies suggest an incidence of 0,14% to 0,7%. In a series of 18960 CT of the abdomen, only three cases of splenic abscesses were found⁹. Mortality rates of 12 to 47% have been reported^{1,5}. In large series and reviews the etiologic factors recognized are metastatic infection from other sites, such as bacterial endocarditis, secondary infection of splenic infarction such as hemoglobinopathies, trauma to the spleen, immunodeficiency state and contiguous infection by direct spread. In this case, the patient was receiving multiple intravenous drugs, what is a cause for transitory bacteremia² with posterior infection of the hematoma. The most common organisms obtained from culture of these abscesses are aerobic microbes, in particular the staphylococci (like this case), streptococci, salmonella and escherichia coli^{4,7}. Anaerobic organisms are less frequently encountered and this may be due to the difficulty in culturing these microbes. Mycobacteria and fungi are being increasingly reported in immunosuppressed patients. Splenic abscesses are polymicrobial in 36% of cases⁵. The diagnosis on clinical grounds is difficult. Fever is present in 90% of patients

but the classical triad of fever, left upper quadrant pain and splenomegaly is seen in only one third of patients³. Fortunately the present case did not present any difficulty for the diagnosis. Empiric broad spectrum antibiotics are used in the initial management and changed according to culture results. A plain abdominal x-ray can show a soft tissue mass in the left upper quadrant, displacement of the gastric bubble, elevation of the left hemidiaphragm or a left pleural effusion. Abdominal US is cost-effective, non-invasive and very useful for percutaneous drainage. With a sensitivity of 96%, CT is presently the gold standard to establish the diagnosis^{3,4,7}. Medical therapy with antibiotics alone have been reported in patients considered unfit for surgical intervention but is the exception rather than the rule. Nonetheless, antibiotics must be kept for at least two weeks even in the surgical patients. Surgical options include percutaneous aspiration, percutaneous catheter drainage, open drainage and splenectomy (partial or total, open or laparoscopic)^{10,13}. Recently it was reported the first case of a splenic abscess treated definitively with endoscopic transgastric drainage⁸. In the past, surgical treatment for

splenic abscesses was by splenotomy. Later, splenectomy had been the gold standard of treatment for splenic abscess in the literature^{4,5,9}. Nowadays the importance of preserving splenic function, whenever possible, is well known. Percutaneous drainage is indicated for uniloculated or biloculated abscesses and for high-risk surgical patients^{6,17}. Splenic resection is indicated for failed percutaneous drainage or multiloculated abscesses³. We have demonstrated that the upper part of the spleen vascularized by splenogastric vessels had satisfactory immune function¹⁵. In this case that was the only part of the organ free of abscess loci, therefore subtotal splenectomy was the last chance to preserve some splenic tissue. Once provided adequate (spectrum and length of use) antibiotic therapy the patient has recovered uneventfully.

CONCLUSION

Subtotal splenectomy is an effective option in splenic abscess surgical therapy.

Nagem RG, Petroianu A. Esplenectomia subtotal para abscesso esplênico. ABCD Arq Bras Cir Dig. 2008;21(2):92-4

RESUMO – Introdução – Abscesso esplênico é condição rara e trás consigo alta mortalidade (quase 100% quando não tratado) e a cirurgia é a forma de tratamento de escolha. **Relato de caso** – Homem adulto foi submetido à terapia tromboembólica como tratamento de enfarte de miocárdio e apresentou hematoma espontâneo de baço, o qual transformou-se em abscesso. Desde que ele era multiloculado e grande, esplenectomia subtotal foi considerada o único tratamento que poderia retirar todo o tecido comprometido. Este procedimento foi realizado com sucesso e o paciente evoluiu bem sem complicações. **Conclusão** – Esplenectomia sub-total é uma efetiva opção para o manuseio dos abscessos esplênicos.

DESCRIPTORIOS – Abscesso esplênico. Esplenectomia sub-total.

REFERENCES

- Alonso-Cohen MA, Galera MJ and Ruiz M. Splenic abscess. World J Surg 1990; 14: 513-516.
- Alterman P, Vigder C, Shabun A, Feldman J, Spiegel D, Yaretzky A. Splenic abscess in geriatric care. J Am Geriatr Soc 1998; 46: 1481-1483.
- Chang KC, Chuah sk, Changchien CS, Tsai TL, Lu SN, Chiu YC et al. Clinical characteristics and prognostic factors of splenic abscess: a review of 67 cases in a single medical center of Taiwan. World J Gastroenterol 2006; 12: 460-464.
- Faught WE, Gilbertson JJ and Nelson EW. Splenic abscess: presentation, treatment options and results. Am J Surg 1989; 158: 612-614.
- Gadacz TR. Splenic abscess. World J Surg 1985; 9: 410-415.
- Gasparini D, Basadona PT, Didonna A. Splenic abscesses: their management and the role of the interventional radiologist. Radiol Med 1994; 87: 803-807.
- Herman P, Silva A, Chaib E, D'Albuquerque LC, Pugliese v, Machado MCC, Pinotti HW. Splenic abscess. Br J Surg 1995; 82: 355.
- Lee DH, Cash BD, Womeldorph CM and Horwhat JD. Endoscopic therapy of a splenic abscess: definitive treatment via EUS-guided transgastric drainage. Gastrointest Endosc 2006; 64:631-634.
- Lucien L, Leong SS. Splenic abscesses from 1987 to 1995. Am J Surg 1997; 174:87-93.
- Nelkman N, Ignatius J, Skinner M. Changing clinical spectrum of splenic abscess: a multicenter study and review of the literature. Am J Surg 1987; 154: 27-34.
- Ng KK, Lee TY and Wan YL. Splenic abscess: diagnosis and management. Hepatogastroenterol 2002; 49: 567-571
- Petroianu A, Ferreira VL, Barbosa AJA. Morphology and viability of the spleen after subtotal splenectomy. Braz J Biol Res 1989; 22: 491-5.
- Phillips GS, Radosevich MD, Lipsett PA. Splenic abscess: another look at an old disease. Arch Surg 1997; 132:1331-1336.
- Pimpl W, Dapunt O, Kaindl H and Thalhamer J. Incidence of septic and thromboembolic-related deaths after splenectomy in adults. Br J Surg 1989; 76: 517-521.
- Resende V, Petroianu A. Functions of the splenic remnant after subtotal splenectomy for treatment of severe splenic injuries. Am J Surg 2003; 5: 311-315.
- Tung CC, Chen FC, Lo CJ. Splenic abscess: an easily overlooked disease? Am Surg 2006; 4: 322-5.
- Zerem E, Bergsland J. Ultrasound guided percutaneous treatment for splenic abscesses. World J Gastroenterol 2006; 12:7341-45.

Fonte de financiamento: não há

Conflito de interesse: não há

Recebido para publicação: 16/11/2007

Aceito para publicação: 20/01/2008