

## THREE PORT LAPAROSCOPIC APPENDECTOMY TECHNIQUE WITH LOW COST AND AESTHETIC ADVANTAGE

*Técnica de apendicectomia laparoscópica com três portais de baixo custo e benefício estético*

Carlos Eduardo **DOMENE**, Paula **VOLPE**, Frederico Almeida **HEITOR**

From the Centro Integrado de Medicina Avançada e Núcleo Unificado de Tratamento do Obeso (Integrated Center for Advanced Medicine and Unified Center for Treatment of the Obese), São Paulo, SP, Brazil.

**HEADINGS** - Appendectomy.  
Laparoscopy. Technic.

### Correspondence:

Carlos Eduardo Domene  
Email: cedomene@terra.com.br

Financial source: none  
Conflicts of interest: none

Received for publication: 23/05/2014  
Accepted for publication: 14/08/2014

**DESCRIPTORES** - Appendectomy.  
Laparoscopia. Técnica.

**ABSTRACT - Introduction:** Despite dating more than 30 years after the first laparoscopic appendectomy, ileocecal appendix resection is still performed by laparotomy in more than 90% of cases, in our country. **Aim:** To describe a technique for laparoscopic removal of the ileocecal appendix with three portals, at low cost and very good aesthetic appearance. **Technique:** Three incisions, one umbilical and two suprapubic are made; permanent material used comprises: grasping forceps, hook, scissors, needle holders, three metal trocars and four other usual instruments, and a single strand of cotton. There is no need to use of operative extractors bags, clips, endoloops, staples or bipolar or harmonic energy instruments. Allows triangulation and instrumentation in the conventional manner. **Conclusion:** The proposed technique is safe and reproducible, easily teachable, at very low cost and can be applied in general hospitals with conventional laparoscopic equipment.

**RESUMO - Introdução:** Apesar de datar mais de 30 anos da primeira apendicectomia videolaparoscópica, a apendicectomia ainda é realizada por laparotomia em mais de 90% dos casos em nosso país. **Objetivo:** Descrever uma técnica para retirada laparoscópica do apêndice ileocecal com três portais, com muito baixo custo em insumos e de muito bom aspecto estético. **Técnica:** São feitas três punções, uma umbilical e duas suprapúbicas; o material permanente utilizado compreende: pinça de apreensão, gancho, tesoura, portagulhas, três trocarerres metálicos e outros quatro instrumentos usuais, além de um único fio de algodão. Não há necessidade do uso de bolsas extratoras da peça operatória, cliques, alças, grameadores ou instrumentos de energia especial, bipolar ou harmônica. Permite triangulação e instrumentação da forma convencional. **Conclusão:** A técnica proposta é segura e reprodutível, facilmente ensinada, de muito baixo custo podendo ser aplicada em hospitais gerais com equipamento laparoscópico convencional.

## INTRODUCTION

Appendectomy is the most common operation in emergency situations<sup>23,27</sup>. Although dating more than 30 years after the first laparoscopic appendectomy, it is still performed by laparotomy in more than 90% of cases in our country<sup>4,5,23</sup>. Several causes determine this high index of laparotomic procedures and, among them, it can be mentioned the cost of equipment and used inputs.

The objective of this proposal is to describe one technique for performing laparoscopic appendectomy with three portals at very low cost and with good aesthetic appearance.

## TECHNIQUE

Three incisions for trocars are performed. The first, 5 to 10 mm in length, is made in the umbilicus for the optical device (incision is dependent on optical diameter) using permanent metallic trocar. Two other suprapubic incisions are performed at low bilateral position, medial to the epigastric vessels. On the right side is introduced one 5 mm permanent metallic trocar; on the left, another of 10 mm with reducer to 5 mm. The surgeon is on the left side of the patient, with the first assistant on his right and instrumentation table on the left. The monitor is put on the right side of the patient (Figure 1).

The operation is performed with four permanent instruments: grasping forceps, hook, scissors and needle holders. A single needled 2-0 cotton thread is used. The surgical technique consists on doing the following steps: 1) hold the ileocecal appendix with grasping forceps introduced through right iliac fossa; 2) with the hook in the left iliac fossa trocar, isolate the appendix from its meso since its edge going gradually to the base, including the epiploic appendices near the appendix and cecum, releasing them from the vicinity (Figure 2); 3) suture the base of the appendix with the cotton thread (needled 2-0 with 20 cm long), transfixing

the serous with two sutures for better fixation, with optional one more distal suture between the sutures, without risk of extravasation of its content; 4) cut the suture thread at the appendix base and the remainder needled thread remains in the abdominal cavity to be used in appendiceal stump invagination; 5) hold appendix near the base using grasping forceps introduced through 10 mm reducer trocar in the left iliac fossa, or between the two sutures, when the second suture was performed; 6) section of the appendix using the hook introduced through the right iliac fossa; the suture between the base and the grasping forceps (or between the two suture), avoids leakage of the contents of the appendix (Figures 3 and 4); 7) removal of the apprehended appendix, pulling the grasping forceps immediately after section into the trocar (Figure 4); normally the diameter of the appendix allows its removal pulling up with the reducer and, without the meso, even thicker inflammatory appendix can be pulled out through the 10 mm trocar; 8) put the appendix within the 10 mm trocar; 9) the 10 mm trocar is withdrawn from the abdominal wall with the appendix inside and, afterward is introduced again; this maneuver avoids the use of extraction bags which, besides increasing the cost of the procedure, requires movements to put the appendix inside which may require time and risk of contamination of the abdominal cavity; 10) made an oversuture on the cecum around the appendiceal stump doing its invagination.

## DISCUSSION

Described by Fitz and first performed in 1886 for the treatment of acute appendicitis, appendectomy is the safest treatment of this disease at any stage of its evolution<sup>1</sup>. The laparotomy incisions used for access vary widely, but the most common is proposed by McBurney (oblique incision in the right iliac fossa)<sup>16</sup>. The aesthetic result is very poor when the laparotomy incisions are oblique, horizontal or vertical. Most appendectomies are performed in children and adolescents, and aesthetics is very important factor at these ages<sup>18</sup>. Scars remain through life, and may change with the growth of the patient, becoming often with unsatisfactory appearance.

The introduction of the laparoscopic approach for appendectomy, described by Kurt Semm in 1982<sup>23</sup>, has brought significant aesthetic benefits, since it is almost always performed with three incisions, two of which are located in different positions in the abdominal wall, but always visible on the exposed abdomen. This is particularly important when the operation is in young female. In the technique proposed here, the first incision of 5 or 10 mm in length is not visible, due it is located inside the umbilicus. The other two, being held in low hypogastrium, are also almost imperceptible because they can be hidden by underclothes.

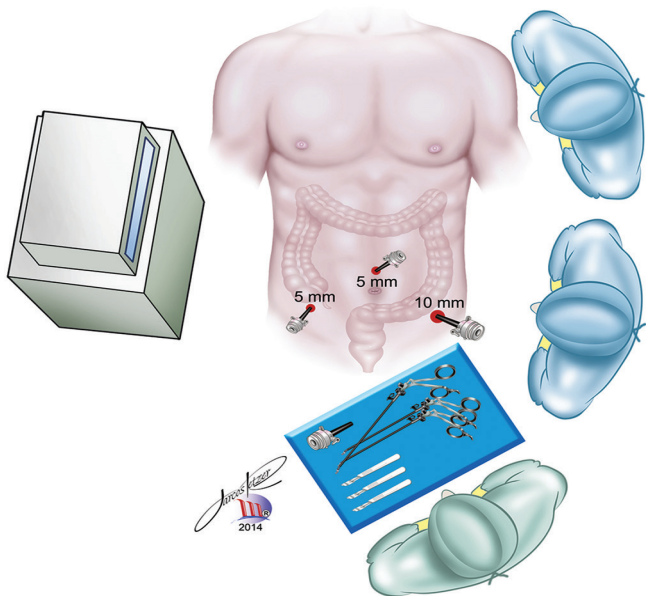


FIGURE 1 - Positioning of the surgical team, trocars and monitor

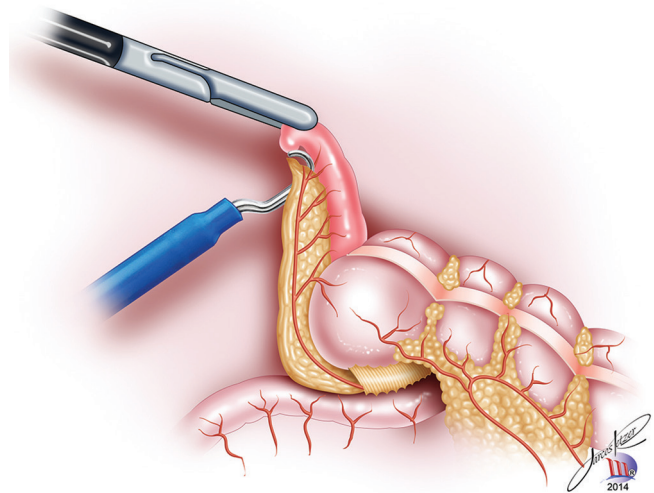


FIGURE 2 - Release the appendix from its meso with monopolar hook

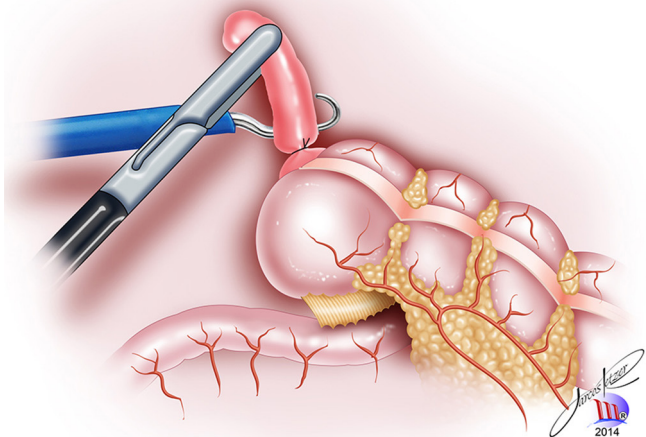


FIGURE 3 - Section of the appendix near to the base suture with monopolar hook

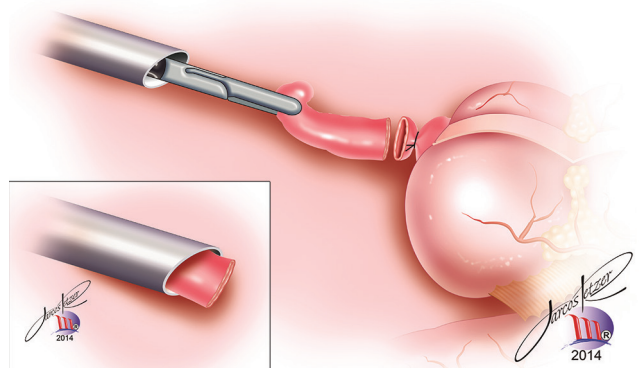


FIGURE 4 - Traction and remove of the appendix through the left iliac fossa trocar immediately after section, avoiding use of extraction bag

Access through natural orifices (excluding the umbilicus from this classification) - NOTES - had no significant evolution and even if in the future it may be used, special instrumentation and specialized equipment increase its cost, as well as requires staff highly trained<sup>13</sup>.

The technique of single umbilical access is feasible for the appendectomy, and has better aesthetic appeal in relation to the multiple visible incisions in the abdominal wall<sup>8,11,14,17,24,25,26,29</sup>. The incisional access needs to be wider, and may become visible or can deform the patient's umbilicus. The incision should be at least 2.5 cm long for placing a special trocar, or even be equally long with the sum of the three conventional trocars<sup>2,13</sup>. Remember that most of the listed appendectomy occurs in children, adolescents and young adults. An incision of this size can determine aesthetic result quite precarious in these circumstances<sup>15,22</sup>. Series of cases show that an additional auxiliary trocar may be necessary in up to 10%<sup>21</sup>, or even be converted to three-trocar technique, compromising the appearance<sup>17</sup>. Comparative series reported pain in higher intensity compared to conventional laparoscopy<sup>3,6</sup>. The aesthetic result was better than or equal to the conventional method<sup>8,29</sup>. Even though it is higher in the aesthetic result than conventional laparoscopy, the cost can be significantly higher, need the use of special devices to introduce the instruments by only one access<sup>3,6,16</sup>. To reduce cost, placement device for three trocars can be done, from 10 to 5 mm in diameter by a single umbilical incision<sup>28</sup>; this tactic led authors to comparative series, considering the difficult implementation and aesthetic finished aspect that was similar to laparoscopy with three incisions<sup>17,21,24</sup>.

In single portal technique cannot be disregarded the technical difficulty in dissecting and sectioning the appendix with conventional instruments without triangulation and in bad position to visualize the operative field, promoting higher risk and hindering its use in the more difficult appendices<sup>7</sup>.

Safety is important to consider in such common operation, such as appendectomy, even where the number of procedures performed by each surgeon has implication in increased complications, length of stay and cost<sup>7</sup>. On the other hand, if performed safely and with minimally invasive method, can achieve high rates of hospital stay less than one day up to 90% of the cases<sup>9,10</sup>. The technique described in this paper with three portals - one umbilical and two suprapubic - have satisfactory cosmetic results because the scars usually are not visible, appearing only when there is complete exposure of the abdominal wall. The umbilical scar is small and may be even of 5 mm, not determining deformation of the umbilicus in any patient. The other two incisions, as already mentioned, remain behind the underclothes. This technique also enables appendectomy with a privileged view of the appendix and operative instruments; allows proper triangulation of instruments, bringing security and reducing operative time. The use of suprapubic trocars too close can hinder triangulation<sup>12</sup>.

Treatment of mesoappendix, appendix itself and appendiceal stump is the reason for many publications<sup>17,30</sup>. Mesoappendix release can be done using endoclips, bipolar forceps, harmonic tweezers or vascular stapler. In all, or almost all of these tactics, mesoappendix remains with the surgical specimen. This greatly increases the volume of the surgical specimen, forcing its extraction in special bags, which increase the cost and operative time<sup>19,30</sup>. It should be stressed that its withdrawal is mere artifice of operative tactics; it can stay with the cecum without any additional risk. Moreover, by dissecting close to the mesoappendix, the technique herein described makes unnecessary ligation of appendicular artery, avoiding the use of devices for occlusion and decreasing risk of bleeding. The operative

specimen, and only the inflamed appendix, can be removed in most cases in the 10 mm left iliac fossa trocar, reducing the risk of contamination of the abdominal wall (Figure 4). In the rare impossibility of withdrawing the appendix throughout the trocar, small plastic bag or a piece of sterile surgical glove - very low cost -, the withdraw can be done from the left iliac fossa incision. The appendiceal stump can either be sutured with 2-0 cotton and left exposed. Comparative studies of simple ligation and invagination did not show differences between the two methods of stump treatment<sup>20</sup>. In the technique described here, it takes place an invaginating suture in the cecum around the appendiceal stump.

The technique suggested here, standardized and simplified, can be made in any hospital that has a system for conventional laparoscopy with the basic permanent instruments; makes the operation to be faster with rapid removing of the specimen with only one or two sutures. It does not use any instrument or disposable device, and is at very low cost. Can be used safely at any age and at any stage of evolution of appendicitis, especially in morbidly obese patients.

The authors have used this technique systematically in the last 15 years, and its safety, efficiency and replication is cause for another publication. The authors hope that with this contribution the laparoscopic appendectomy can be more widely applied in the surgical treatment of acute appendicitis, since there is already concrete evidence of its superiority to laparotomy appendectomy, especially in more complicated cases, or in obese patients.

## CONCLUSION

This technique of laparoscopic procedure is almost inexpensive, allows triangulation and instrumentation in the conventional manner, is safe and reproducible and can be easily learned and taught, and multiplies the possibility of its use in hospitals that have the conventional laparoscopic equipment.

## REFERENCES

1. Aguayo P, Alemayehu H, Desai AA, Fraser JD, St Peter SD. Initial experience with same day discharge after laparoscopic appendectomy for nonperforated appendicitis. *J Surg Res* 2014; 4804(14):245-50.
2. Bergholz R, Klein I, Wenke K, Boettcher M, Reinshagen K, Krebs T. Midterm outcome of transumbilically laparoscopic-assisted versus laparoscopic and open appendectomy. *Europ J Pediatric Surg* 2014; 28(3):35-9.
3. Bergholz R, Krebs T, Klein I, Wenke K, Reinshagen K. Transumbilical laparoscopic-assisted versus three-port laparoscopic and open appendectomy: a case-control study in children. *Surg Laparosc Endosc Percutan Tech* 2014; 24(3):135-9.
4. Borges PSGN, Lima MC, Falbo Neto GH. Validação do score de Alvarado no diagnóstico de apendicite aguda em crianças e adolescentes no Instituto Materno Infantil de Pernambuco. 2003; 3(4): 439-45.
5. Brenner AS. Apendicectomia em pacientes com idade superior a 40 anos: análise dos resultados de 217 casos. *Rev Bras Colo-proctol* 2006; 26(2):128-32.
6. Carter JT, Kaplan JA, Nguyen JN, Lin MY, Rogers SJ, Harris HW. A prospective, randomized controlled trial of single-incision laparoscopic vs conventional 3-port laparoscopic appendectomy for treatment of acute appendicitis. *J Am Coll Surg* 2014; 218(5):950-9.
7. Cawich SO, Mohanty SK, Simpson LK, Ramdass MJ, Naraynsingh V. Is laparoscopic appendectomy safe when performed in a low volumen setting? *Int J Biomed Sci* 2014; 10(1):31-5.
8. Clerveus M, Morandeira-Rivas A, Moreno-Sanz C, Herrero-Bogajo ML, Picazo-Yeste JS, Tadeo-Ruiz G. Systematic review and meta-analysis of randomized controlled trials comparing single incision versus conventional laparoscopic appendectomy. *World J Surg* 2014; 28:31-9.

9. Cross W, Chadru Kowdley G. Same-day surgery for laparoscopic appendectomy in appendicitis: is this safe? *Am Surg* 2014; 80(1):25-6.
10. Frazee RC, Abernathy SW, Davis M, Hendricks MC, Isbell TV, Regner JL, Smith RW. Outpatient laparoscopic appendectomy should be the standard of care for uncomplicated appendicitis. *J Trauma Acute Care Surg* 2014; 76(1):79-82.
11. Golebiewski A, Losin M, Murawski M, Wiejec A, Lubacka D, Czaudema P. One, two or three port appendectomy – a rational approach. *Wideochir Inne Tech Malo Inwazyjne*. 2013; 8(3):226-31.
12. Gorter RR, Heij HA, Eker HH, Kazemier G. Laparoscopic appendectomy: state of the art. *Best Pract Res Clin Gastroenterol* 2014; 28(1):211-24.
13. Knuth J, Heiss MM, Bulian DR. Transvaginal hybrid-NOTES appendectomy in routine clinical use: prospective analysis of 13 cases and description of the procedure. *Surg Endosc* 2014; 28(3):731-9.
14. Langer M, Safavi A, Skarsgard ED. Management of the base of the appendix in pediatric laparoscopic appendectomy: clip, ligate or staple? *Surg Technol Int* 2013; 23:81-3.
15. Lasheen AE, Ezz R, Safwat K, Salem A, Amr W. Minilaparoscopic appendectomy using a new spiral needle. *Surg Endosc* 2014; 28(3):645-9.
16. Lasses-Martinez B, Ortiz-Oshiro E, Cabanas-Ojeda JL, Benito-Exposito P, Fernandez Perez C, Alvarez Fernandez-Represa J. Cost is not a drawback to perform laparoscopic appendectomy in a academic hospital. *Surg Laparosc Endosc Percutan Tech* 2014; 24(2):24-9.
17. Lee JS, Hong TH. Comparison of various methods of mesoappendic dissection in laparoscopic appendectomy. *J Laparoendosc Adv Surg Tech A*. 2014; 24(1):28-31.
18. Lee SE, Choi YS, Kim BG, Cha SJ, Park JM, Chang IT. Single port laparoscopic appendectomy in children using glove port and conventional rigid instruments. *Ann Surg Treat Res* 2014; 86(1):35-8.
19. Minutolo V, Licciardello A, Di Stefano B, Arena M, Arena G, Antonacci V. Outcomes and cost analysis of laparoscopic versus open appendectomy for treatment of acute appendicitis. *BMC Surg* 2014; 14:14-20.
20. Neves LJVA. Ligadura simples ou ligadura com confecção de bolsa e sepultamento para tratamento do coto apendicular: estudo comparativo prospectivo randomizado. *Arq Bras Cir Dig* 2011; 24(1):15-9.
21. Nicola Z, Gabriella S, Alberto M, Saverio CF. Transumbilical laparoscopic-assisted appendectomy in children: clinical and surgical outcomes. *World J Gastrointest Endosc* 2014; 6(4):101-4.
22. Olijnyk JG, Pretto GG, da Costa Filho OP, Machado FK, Silva Chalub SR, Cavazzola LT. Two-port laparoscopic appendectomy as transition to laparoendoscopic single site surgery. *J Minim Access Surg* 2014; 10(1):23-6.
23. Oliveira ALG, Oti, AT, Yasojuma EY, Ikegami HC, Hage PAM, Valente TON. Apendicectomia videolaparoscópica: análise prospectiva de 300 casos. *Arq Bras Cir Dig* 2008; 21(2):48-52.
24. Pinheiro RN, Sousa RC, Castro FM, Almeida RO, Gouveia G de C, Oliveira VR. Single-incision videolaparoscopic appendectomy with conventional videolaparoscopic equipment. *Arq Bras Cir Dig* 2014; 27(1):34-7.
25. Qiu J, Yuan H, Chen S, He Z, Wu H. Single-port laparoscopic appendectomy versus conventional laparoscopic appendectomy: evidence from randomized controlled trials and nonrandomized comparative studies. *Surg Laparosc Endosc Percutan Tech* 2014; 24(1):12-21.
26. Sesia SB, Haecker FM. Laparoscopic-assisted single-port appendectomy in children: it is a safe and cost-effective alternative to conventional laparoscopic techniques? *Minim Invasive Surg* 2013; 8:24-9.
27. Slotboom T, Hamminga JT, Hofker HS, Heineman JW. Intraoperative motive for performing a laparoscopic appendectomy on a postoperative histological proven normal appendix. *Scand J Surg* 2014; Apr 15: 232-36.
28. Swank HA, van Rossem CC, van Geloven AA, in't Hof KH, Kazemier G, Meijerink WJ, Lange JF, Bemelman WA. Endostapler or endoloops for securing the appendiceal stump in laparoscopic appendectomy: a retrospective cohort study. *Surg Endosc* 2014; 28(2):576-83.
29. Villalobos-Mori R, Escoll-Rufino J, Herrerias-Gonzales F, Mias-Carballal MC, Escartin-Arias A, Olsina-Kissler JJ. Prospective, randomized comparative study between single-port laparoscopic appendectomy and conventional laparoscopic appendectomy. *Cir Esp* 2014; 26:51-8.
30. Wright GP, Mitchell EJ, McClure AM, Onesti JK, Moyo SC, Brown AR, Peshkepiya A, Scott GL, Chung MH. Comparison of stapling techniques and management for the mesoappendix in laparoscopic appendectomy. *Surg Laparosc Endosc Percutan Tech* 2014; 24(5):315-9.